

Variation of Acid Phosphatase Activity in the Fallopian Tube of Rabbits: A Semiquantitative Histochemical Assessment

VIRENDRA KUMAR¹, GEETIKA MOHAN², NIYATI AIRAN³, ADITI SRIVASTAVA⁴, ANIL KUMAR DWIVEDI⁵

ABSTRACT

Introduction: The fallopian tube is a tubular muscular organ connecting the uterus to the ovary. It is important for the passage of gametes, zygotes, and early embryos. Fallopian tube undergoes histochemical variations with ovarian cycles.

Aim: To study the phasial and segmental variation of Acid Phosphatase (ACP) activity in the fallopian tube of rabbits.

Materials and Methods: A cross-sectional study was done on 50 female rabbits at Sarojini Naidu (SN) Medical College, Agra from June 1976 to June 1979. The fallopian tubes of both sides were taken out by dissection and cut into anatomical segments, from medial to lateral ends viz., intramural, isthmus, ampulla and infundibulum. The phases of the oestrus cycle i.e., pro-oestrus, oestrus, meta-oestrus, and di-oestrus were decided by cytological observation of a papaniculous stained vaginal smear. ACP activity was observed in various phases of sexual cycle and in different segments of the fallopian tube by the

modified lead nitrate staining method i.e. Takeuchi and Tanoue. One-way Analysis of Variance (ANOVA) was applied for the analysis of the data.

Results: The ACP activity was higher in pro-oestrus (2.25 ± 0.24), oestrus (2.00 ± 0.24) and low in meta-oestrus (1.33 ± 0.24) and di-oestrus phases (1.08 ± 0.24) of sexual cycle. The activity was seen higher in infundibulum (2.50 ± 0.22), ampullary (1.83 ± 0.22) and low in intramural (1.08 ± 0.22) and isthmus segments (1.25 ± 0.22) of the fallopian tube. The maximum difference (1.42) was noticed between the infundibulum and intramural segments ($p < 0.001$). A maximum difference (1.16) was noticed between prooestrous and di-oestrus the ($p < 0.001$).

Conclusion: Oestrogenic phase of the sexual cycle has higher enzymatic activity whereas in the luteal phase it was low. The infundibulum and ampulla show higher activity which suggests these segments are more functionally active as compared to intramural and isthmus segments.

Keywords: Acid phosphatases, Activity, Ampulla, Fallopian tube, Infundibulum, Intensity, Oestrous cycle, Segments

INTRODUCTION

Life is possible due to the coordination of numerous metabolic reactions inside the body cells. Proteins are hydrolysed with hydrochloric acid by boiling for a very long time; but inside the body with the help of enzymes, proteolysis takes place within a short time at body temperature. Enzyme catalysis is very rapid; usually, one molecule of an enzyme can act upon about 1000 molecules of substrate per minute. Lack of enzyme will lead to block in the metabolic pathways causing in born error of metabolism. The substance upon which an enzyme acts is called substrate. The enzyme will convert the substrate into product or products [1].

Monosaccharides are produced in the uterus under influence of oestrogen [2]. The enzymes i.e., acid and Alkaline Phosphatases (ALP) are closely associated with the metabolism of monosaccharides [3,4]. ACP may be involved in the provision of energy for organelle destruction and its release has been associated with lysosomal involvement in implantation and placentation in sheep, man, and mice [5-7].

ACP and ALP are two different enzymes that show considerable alterations, depending on the volume of luminal secretion in the luteal phase. These secretions are essential for embryo development. The ACP activities are responsible for the hydrolysis of organic phosphodiesterase [8]. ACP is found in different forms in the cells of the tissue. Normal serum value of ACPs is 2.5-12 U/L. enzymology such as tumour marker and biomarker gained the clinician's attention in regards to the disease diagnosis and prognosis [1].

Fallopian tube epithelium and its secretions are important for the survival and transportation of gametes and also provide favourable condition for sperm capacitation and fertilisation [9]. As far as the authors are aware, work on histochemical aspects of fallopian tube is less and previous work have not comprehensively considered

various segments of fallopian tube and various phases of ovarian cycle [10]. The present study was conducted to find out segmental and phasial variation of ACP activity in fallopian tube. The obtained histochemical data may be of value in understanding the physiology and pathological aspect of fallopian tube.

MATERIALS AND METHODS

A cross-sectional observational study was done on 50 female rabbits at Sarojini Naidu (SN) Medical College, Agra during June, 1976 to June, 1979. The healthy mature animals were chosen for this study.

Inclusion criteria: Physical active female rabbits in reproductive age group without pregnancy.

Exclusion criteria: Unhealthy and pregnant female rabbits with visible congenital malformations, altered physical and feeding behaviour.

Study procedure: The phase of oestrus cycle was decided by cytological appearance of papaniculous stained vaginal smear of experimental animals. These animals were treated with the ether to anaesthetise and abdomen was opened by giving the vertical incision in the wall. The fallopian tubes were obtained by dissection and cut into four anatomical segments from medial to lateral ends i.e., intramural, isthmus, ampulla and infundibulum in each phase of oestrous cycle viz., pro-oestrus, oestrus, meta-oestrus, di-oestrus. The cut segments were fixed in cold acetone (-40C) for 24 hours. Tissues were then routinely processed and embedded in paraffin blocks, transverse microsections of 6 μ were cut and stained by modified lead nitrate staining method [11]. The slides were studied under light microscope. ACP activity appears as brownish black [11].

Chemistry of phosphatase activity: ACP+ β Glycerophosphate \rightarrow acid phosphate \rightarrow lead phosphate (yellow ammonium sulphide) \rightarrow lead sulphide (brown or brown black precipitate).

The sections from different segments of fallopian tube of rabbit in various phases of sexual cycle were stained by modified lead nitrate method (Takeuchi and Tanoue) [11]. The brownish black colour showed the presence of ACP activity. It was seen in lining epithelial cells. The enzymatic activity was almost exclusively found in cytoplasm of the cells.

The stained slides were given to three different independent observers to grade the intensity of ACP activity in various phases and in different anatomical segments. The grading criteria was fixed as irregular or in traces, weak, mild, moderate for ACP activity. The results of observations were not known to each other. The mean of grading given by three observers were taken into consideration for evaluation of the ACP activity depicted in [Table/Fig-1] [12].

Phases of sexual cycle	Segments of fallopian tube			
	Infundibulum	Ampulla	Isthmus	Intra-mural
Pro-oestrus	+++	++	+	+
Oestrus	+++	++	+	+
Meta-oestrus	++	++	+	+
Di-oestrus	+	±	±	±

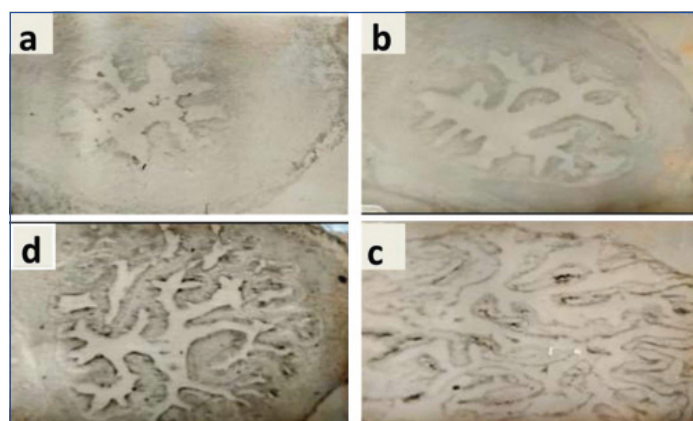
[Table/Fig-1]: Semi-quantitative assessment of Acid Phosphatase (ACP) activity [12]. Segmental Variation of ACP Activity; +(weak), ++(mild), +++(moderate), +- (irregular)

STATISTICAL ANALYSIS

Mean grading of stained slides was converted into quantitative data. The grade for intensity of ACP activity by three independent observers was considered equivalent to 0, + to 1, ++ to 2, and +++ to 3. The rounding off mean values of grading was taken into consideration. One-way ANOVA was applied for the analysis of data, using 16 version of JMP software.

RESULTS

The ACP activity was found to be maximum in pro-oestrus and oestrus phases. It was more in infundibulum segment of fallopian tube [Table/Fig-1,2]. The ACP activity of different segments of fallopian tube was compared. Intramural segment fallopian tube with minimum ACP activity (1.08) was compared with remaining three segments of fallopian tube- infundibulum, ampulla, isthmus. The maximum difference (1.42) was noticed between infundibulum and intramural segments, the difference was statistically significant ($p < 0.001$) [Table/Fig-3,4]. The ACP activity was found to be maximum in pro-oestrus and oestrus and minimum in di-oestrus phase of sexual cycle [Table/Fig-5].



[Table/Fig-2]: Photomicrograph: Modified Lead Nitrate Staining (X100). a) Intramural- Irregular/traces intensity; b) Isthmus- Weak intensity; c) Ampulla- showing mild intensity; d) Infundibulum- Moderate intensity.

The ACP activity was maximum in pro-oestrus (2.25) and minimum in dioestrus (1.08) phase of sexual cycle [Table/Fig-6]. The phase with minimum ACP activity (dioestrus) was compared with remaining three phases of sexual cycle [Table/Fig-7]. Maximum difference (1.16) was noticed between Prooestrus and Di-oestrus, the difference was statistically significant ($p < 0.001$) [Table/Fig-7].

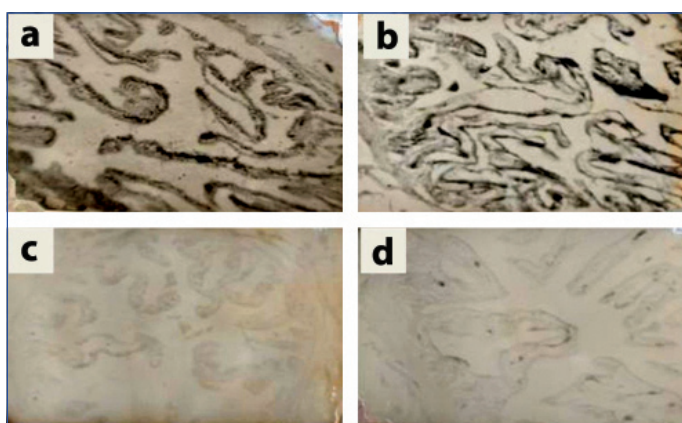
Segments of Fallopian Tube	Mean±SEM
Infundibulum	2.50±0.22
Ampulla	1.83±0.22
Isthmus	1.25±0.22
Intramural	1.08±0.22

[Table/Fig-3]: Mean values of ACP Activity in various segments.

Segments of Fallopian Tube	Segments of Fallopian Tube	Difference	p-value
Infundibulum	Intramural	1.416667	<0.0001
Ampulla	Intramural	0.750000	0.0208
Isthmus	Intramural	0.166667	0.5969

[Table/Fig-4]: Comparison of means of different segments of Fallopian tube for ACP activity.

ANOVA was used
Phasal Variation of ACP Activity



[Table/Fig-5]: Photomicrograph: Modified Lead Nitrate Staining (X100).

a) Pro oestrus-Moderate intensity; b) Oestrus-Moderate intensity; c) Meta Oestrus-Mild intensity; d) Di Oestrus-Irregular/traces.

Phases of Sexual Cycle	Mean±SEM
Pro-oestrus	2.25000±0.238
Oestrus	2.00000±0.238
Metestrus	1.33333±0.238
Dioestrus	1.08333±0.238

[Table/Fig-6]: Mean values of ACP Activity in various phases.

Phases of sexual cycle	Phases of sexual cycle	Difference	p-value
Pro-oestrus	Diestrus	1.166667	0.0012
Oestrus	Diestrus	0.916667	0.0091
Meta-oestrus	Diestrus	0.250000	0.4610

[Table/Fig-7]: Comparison of means of different phases of sexual cycle for ACP activity.

ANOVA was used

DISCUSSION

The fallopian tube is a target organ for two ovarian steroids viz., oestrogen and progesterone [13,14]. These hormones cause various morphological and biochemical changes in oviductal epithelial cells. These changes are essential for formation of an environment that can support fertilisation and early embryonic development. The oestrogen causes hypertrophy, active ciliation and secretion by atrophied epithelial cells in fallopian tube of immature or ovariectomised animals [15-18], and during follicular phase of oestrus cycle [19,20]. In contrast, progesterone usually antagonises the induction by oestrogen of the cyto-differentiation of oviductal epithelial cells [21,22]. In several species, the epithelial cells of ampulla and isthmus have been shown to undergo region specific morphological changes in response to oestrogen and progesterone [14]. The diverse actions of ovarian steroid hormones on these two anatomically and functionally distinct segments of fallopian tube may

also be a reflection of various regional differences along the tube and histochemical variation in various phases of oestrus cycle as well.

The ACP activity was found to be moderate to high in amount in ampulla and infundibulum, respectively [Table/Fig-2c,d] and least in isthmus and intramural segments of fallopian tube [Table/Fig-2a,b]. Gupta DN et al., found an increase activity in infundibulum perhaps due to physical presence of ova [10]. Since, the phosphatase activity was found more in infundibulum and ampulla, therefore these segments seem to be physiologically more active during sexual cycle. Kumar V and Srivastava A observed that the secretory and ciliated cells were crowded more in the infundibulum than in other segments, the intramural segments having least [23]. The secretory cells were found in mucosal folds and ciliated cells at the tip of the folds. The ciliary cells concentrated more in the infundibulum and this might be related to increased mechanical activity needed for transportation of ova towards the uterine end. Hence, ACP activity is maximum in infundibulum.

Stastna D et al., observed the largest relative volume of epithelial layer was at follicular phase along with entire fallopian tube [24]. The difference varies from 4.99% isthmus to 13.6% infundibulum and significant changes were seen between ciliary and secretory cells. Ciliary cells dominate infundibulum and ampulla, whereas secretory cells in isthmus. The statement is also reported by Katare B et al., (secretory cell more in luteal phase), Kumar V and Srivastava A, Barbara S and Richard L (secretory cells more in ampulla and during oestrus cycle), Steinhauer N et al., Abe H and Hoshi H (ciliated cells 27.6µm in ampulla during follicular phase), Arrighi S et al., (epithelium increase in highness in follicular phase) [9,23,25-28].

The ACP activity was found to be maximum in pro-oestrus and oestrus phases of sexual cycle [Table/Fig-5a,b], may be related to hyperoestrogenic status of the animal. Kumar V and Srivastava A revealed the structural and functional changes in relation to various phases of sexual cycle [12]. During pro-oestrus and oestrus phases the mucosa showed the structural cellular growth attesting relation with oestrogen, likewise the functional secretory activity seems to bear nutritional importance for passing ova through tube. The ciliary cells prominent during oestrus and pro-oestrus phases may be helpful in flushing the secretions along the tube. Odor DL et al., also reported as in early follicular phase most of the epithelial cells are non ciliated i.e., 89.9% in fimbriae, 80.4% in ampulla, 65.0% in isthmus and extensive deciliation in fimbria during second half of cycle leads to a significant increase in ciliated cells in these regions during late luteal phase (92.2% in fimbria, 81.2% in ampulla and 62.2% in isthmus) [20]. However, Gupta DN et al., reported an increase in ACP activity throughout the tube during passage of ova [29]. And it was suggested that enzymes play role in denudation of ova and removal of cumulus and corona cells debris. Lindenbaum ES et al., however observed in their ultrastructural study in human fallopian tube that ACP reaction product depicted the lysosome, which appeared as electron dense bodies of almost equal numbers in ciliated and secretory cells of all stages in menstrual cycle in human fallopian tube [30]. The ACP activity was found lesser in meta-oestrus and least in di-oestrus phases of sexual cycle. The minimum amount of ACP in di-oestrus phase may be due to lowered oestrogen level [Table/Fig-5c,d].

Arrighi S et al., reported that in luteal phase, the non ciliated cells prevailed in the epithelium to hide most of the ciliated cells [28]. This was either due to a significant decrease of ciliated cells in the Infundibulum and ampulla at luteal phase and or due to the presence of bulging protrusions of non ciliated cells in the lumen. Significant increase of tubal epithelial height together with prevalence of ciliated cells at the follicular phase was previously reported in goat by Abe H and Oikawa T, in sheep by Yániz JL et al., and in cattle by Abe H and Oikawa T; and Mokhtar DM [18,31,32].

Sharma RK et al., reported variation in iron as content that decreased from Infundibulum to isthmus (0.97 ± 20 , 0.74 ± 0.14 , 0.61 ± 0.06

ug/100 mg), respectively during follicular phase and increased from infundibulum to isthmus (0.83 ± 0.18 , 1.00 ± 0.14 , 1.28 ± 0.06 ug/mg, respectively) during luteal phase [33]. This statement supported the present study findings that enzymatic ACP activity was found moderate to high in ampulla and infundibulum and these segments are more active during pro-oestrus and oestrus phases of oestrus cycle. So, the iron contents decreased.

Limitation(s)

Present study has not considered progressive changes in epithelial components of the mucosa, qualitative and quantitative changes in the ciliary and secretory cells in different segments of fallopian tube at various phases of sexual cycle.

CONCLUSION(S)

The ACP activity was found more in oestrogenic phase, suggesting their relationship with oestrogenic level of the animal. It was found more in infundibulum and ampulla indicating their importance in these segments. It has also been observed that physiological changes are much more marked as compared to anatomical or segmental.

Acknowledgement

The very first author Professor Dr Virendra Kumar will ever remain indebted to his mentors and expert guides Professor Dr CD Gupta and Professor Dr VK Srivastava of SN Medical College, Agra where the entire work was carried out under their direct supervision. Also, thankful to Professor Dr CMS Rawat, Principal and Dean for his kind support and cooperation. Thanks to Dr Nidhi Nautiyal, Statistician (Community Medicine) for her statistical support.

REFERENCES

- [1] Vasudevan DM, Sreekumari S, Vaidyanathan K. Textbook of Biochemistry for medical students. New Delhi: Jaypee Brothers Medical Publishers; 2019. Pp. 844.
- [2] Zachariae F. Autoradiographic and histochemical studies of sulphomucopolysaccharides in the Rabbit Uterus, Oviducts and Vagina. *European Journal of Endocrinology*. 1958;29(1):118-34.
- [3] Bachhawat BK, Balasubramanian KA, Balasubramanian AS, Singh M, George E, Chandrasekaran EV. Chemistry and metabolism of glycosaminoglycans of the nervous system. *Advances in Experimental Medicine and Biology*. 1972;25:51-71.
- [4] Valocky I, Legath J, Lenhardt L, Lazar G, Novotny F. Activity of alkaline phosphatase, acidic phosphatase and nonspecific esterase in the oviducts of puerperal ewes after exposure to polychlorinated biphenyls. *Veterinari Medicina*. 2007;52(5):186-92.
- [5] Boshier DP. A histological and histochemical examination of implantation and early placentome formation in sheep. *Journal of Reproduction and Fertility*. 1969;19(1):51-61.
- [6] Contractor SF, Banks RW, Jones CJP, Fox H. A possible role for placental lysosomes in the formation of villous syncytiotrophoblast. *Cell and Tissue Research*. 1977;178:411-19.
- [7] Moulton BC, Koenig BB, Borkan SC. Uterine lysosomal enzyme activity during ovum implantation and early decidualization. *Biology of Reproduction*. 1978;19(1):167-70.
- [8] Leiser R, Wille KH. Cytochemical establishment of acid phosphatase in the bovine endometrium and trophoblast during implantation. *Anatomy & Embryology*. 1975;148(2):159-73.
- [9] Katare B, Singh G, Kumar P, Gahlot PK. Histomorphological studies on the oviduct of goat (*capra hircus*) during follicular and luteal phases. *Haryana Vet*. 2015;54(1):36-38.
- [10] Gupta DN, Karkun JN, Kar AB. Biochemical composition of different portions of rabbit fallopian tube. *Indian J Exp Biol*. 1967;5(2):124-25.
- [11] Pearse AGE. *Histochemistry, Theoretical and Applied*. London: J & A Churchill Ltd; 1968.
- [12] Kumar V, Srivastava A. Histological variations in fallopian tube during various phases of oestrus cycle. *J Anat Sci*. 2018;26(1):44-48.
- [13] Jansen RPS. Endocrine response in the Fallopian tube. *Endocrine Rev*. 1984;5:525-51.
- [14] Abe H. The mammalian oviductal epithelium: Regional variations in cytological and functional aspects of the oviductal secretory cells. *Histol Histopathol*. 1996;11:743-76.
- [15] Verhage HG, Brenner RM. Estradiol- Induced differentiation of the oviductal epithelium in ovariectomized cats. *Biology of Reproduction*. 1975;13:104-11.
- [16] Bajpai VK, Shiptone AC, Gupta DN, Karkun JN. Differential response of the ampullary and isthmic cells to ovariectomy and estrogen treatment: An ultrastructural study. *Endokrinologie*. 1977;69:11-20.
- [17] Pathak R, Bajpai VK, Shiptone AC, Karkun JN. The effect of estrogen withdrawal upon the tubal epithelium of immature ovariectomized rhesus monkey (*Macaca mulatta*) pretreated with estradiol dipropionat. *Endokrinologie*. 1979;74:287-96.

- [18] Abe H, Oikawa T. Observations by scanning electron microscopy of oviductal epithelial cells from wws at follicular and luteal phases. *Anat Rec.* 1993;235:399-410.
- [19] Verhage HG, Bareither ML, Jaffe RC, M A. Cyclic changes in ciliation, secretion and cell height of the oviductal epithelium in women. *Am J Anat.* 1979;156:502-22.
- [20] Odor DL, Gaddum-Rosse P, Rumery RE, Blandau RJ. Cyclic variations in the oviductal ciliated cells during the menstrual cycle and after estrogen treatment in the pig-tailed monkey, *Macaca nemestrina*. *Anat Rec.* 1980;198:35-57.
- [21] Verhage HG, RM RMB. A delayed antagonistic effect of progesterone on the estradiol-induced differentiation of the oviductal epithelium in spayed cats. *Biol Reprod.* 1976;15:654-60.
- [22] West NB, Verhage HG, Brenner RM. Suppression of the estradiol receptor system by progesterone in the oviduct and uterus of the cat. *Endocrinology.* 1976;99:1010-16.
- [23] Kumar V, Srivastava A. Histological differences in various segments of rabbit's fallopian tube. *J Anat Sci.* 1995;14(2):22-28.
- [24] Stastna D, Stastny P, Miluchova M, Gabor M. The morphological changes of oviductal mucosa in oestral cycle of sows. *Acta Fytotechn Zootechn.* 2019;22(2):34-41.
- [25] Shirley B, Reeder RL. Cyclic changes in the ampulla of the rat oviduct. *The Journal of Experimental Zoology.* 1996;276:164-73.
- [26] Steinhauer N, Boos A, Gunzel-Apel A-R. Morphological changes and proliferative activity in the oviductal epithelium during hormonally defined stages of the oestrous cycle in the bitch. *Reprod Dom Anim.* 2004;39:110-19.
- [27] Abe H, Hoshi H. Regional and cyclic variations in the ultrastructural features of secretory cells in the oviductal epithelium of the Chinese Meishan pig. *Reprod Dom Anim.* 2007;42:292-98.
- [28] Arrighi S, Bosi G, Frattini S, Coizet B, Groppetti D, Pecile A. Morphology and aquaporin immunohistochemistry of the uterine tube of saanen goats (*capra hircus*): comparison throughout the reproductive cycle. *Reprod Dom Anim.* 2016;51:360-69.
- [29] Gupta DN, Karkun J, Kar AB. Biochemical changes in different parts of the rabbit fallopian tube during passage of ova. *American J of Obstetrics & Gynaecology.* 1970;106(6):833-37.
- [30] Lindenbaum ES, Beach D, Peretz BA. Ultrastructural localization of alkaline and acid phosphatases in the human fallopian tube epithelium during the menstrual cycle. *Anat Rec.* 1982;203(1):67-72.
- [31] Yániz JL, Carretero T, Recreo P, Arceiz E, Santolaria P. Three-dimensional architecture of the ovine oviductal mucosa. *Anat Histol Embryol.* 2014;43(5):3310340.
- [32] Mokhtar DM. Microscopic and histochemical characterization of the bovine uterine tube during the follicular and luteal phases of estrous cycle. *J Microsc Ultrastruct.* 2015;3(1):44-52.
- [33] Sharma RK, Singh R, Bhardwaj JK. Temporal variations in trace element profile in different segments of fallopian tube during oestrous cycle in Caprines. *Applied Cell Biology.* 2013;2(3):105-09.

PARTICULARS OF CONTRIBUTORS:

1. Professor, Department of Anatomy, Veer Chandra Singh Garhwali Government Medical Science and Research Institute, Srinagar Garhwal, Uttarakhand, India.
2. Assistant Professor, Department of Biochemistry, Veer Chandra Singh Garhwali Government Medical Science and Research Institute, Srinagar Garhwal, Uttarakhand, India.
3. Assistant Professor, Department of Anatomy, Veer Chandra Singh Garhwali Government Medical Science and Research Institute, Srinagar Garhwal, Uttarakhand, India.
4. Professor, Department of Medicine, Veer Chandra Singh Garhwali Government Medical Science and Research Institute, Srinagar Garhwal, Uttarakhand, India.
5. Associate Professor, Department of Anatomy, Veer Chandra Singh Garhwali Government Medical Science and Research Institute, Srinagar Garhwal, Uttarakhand, India.

NAME, ADDRESS, E-MAIL ID OF THE CORRESPONDING AUTHOR:

Anil Kumar Dwivedi,
Associate Professor, Department of Anatomy, Veer Chandra Singh Garhwali Government Medical Science and Research Institute, Srinagar Garhwal, Uttarakhand, India.
E-mail: dranildwivedi2009@gmail.com

PLAGIARISM CHECKING METHODS: [Jain H et al.]

- Plagiarism X-checker: Aug 22, 2022
- Manual Googling: Feb 10, 2023
- iThenticate Software: Mar 01, 2023 (7%)

ETYMOLOGY: Author Origin

AUTHOR DECLARATION:

- Financial or Other Competing Interests: None
- Was Ethics Committee Approval obtained for this study? The work was carried out much earlier than the animal protection act came into existence. No drug has been used in the study. All the then existing guidelines of the institute were followed.

Date of Submission: **Aug 06, 2022**

Date of Peer Review: **Sep 16, 2022**

Date of Acceptance: **Mar 03, 2023**

Date of Publishing: **Apr 01, 2023**