



Pulmonary Involvement during Varicella in a Patient with Sickle Cell Disease: Diagnosis and Treatment

Daouda Thioub ^{a*}, Ndeye Amy Sarr ^a,
Christine Amengo Kogwapa ^a, Khardiata Diallo Mbaye ^a,
Ndeye Aïssatou Lakhe ^a, Aboubakar Sidikh Badiane ^a,
Daye Ka ^a, Ndeye Maguette Fall ^a,
Viviane Marie Pierre Cisse ^a and Moussa Seydi ^a

^a Infectious and Tropical Diseases Department, Fann National University Hospital (CHNU), Dakar, Senegal.

Authors' contributions

This work was carried out in collaboration among all authors. All authors read and approved the final manuscript.

Article Information

DOI: 10.9734/AJRID/2024/v15i2329

Open Peer Review History:

This journal follows the Advanced Open Peer Review policy. Identity of the Reviewers, Editor(s) and additional Reviewers, peer review comments, different versions of the manuscript, comments of the editors, etc are available here: <https://www.sdiarticle5.com/review-history/113592>

Case Study

Received: 20/12/2023

Accepted: 25/02/2024

Published: 28/02/2024

ABSTRACT

Introduction: Pulmonary involvement during chickenpox is one of the most serious complications. However, it can be difficult to distinguish between varicella pneumonia, bacterial superinfection and an acute chest syndrome. We report a case of varicella complicated by pneumonia in a young adult with sickle cell disease.

Observation: It was a 24-year-old woman with sickle cell disease. Examination on admission revealed generalized skin lesions of varying ages, associated with scratching lesions. On day 3 of hospitalization, she presented an acute respiratory distress associated with fever (40°C). Thoracic

*Corresponding author: E-mail: dave11690@gmail.com;

CT angiography revealed diffuse pulmonary nodules and micronodules in both lung fields. Blood culture isolated *Staphylococcus* spp. The patient was put on oxygen therapy combined with antiviral treatment and antibiotic therapy. The course was marked by symptoms regression, with disappearance of respiratory distress on day 2 and apyrexia on day 3 of treatment. The follow-up chest CT scan carried out at month 4, came back normal.

Conclusion: Although pneumonia is one of the most common complications of varicella, it can be difficult to diagnose in patients with sickle cell disease, considering the frequency of pulmonary involvement of various etiologies

Keywords: Chickenpox; sickle cell disease; infection; eruptive fever; varicella.

1. INTRODUCTION

Chickenpox is an infection caused by the varicella zoster virus (VZV), representing its primary infection [1,2]. It remains the most common eruptive fever, is extremely contagious, and mainly affects school-age children, with a prevalence up to 90%. Typically, it manifests itself as a vesicular rash with fever, which usually has a benign outcome [1,3,4]. However, in adults, pregnant women and immunocompromised, the infection can lead to many complications. Pulmonary involvement during chickenpox is one of the most serious complications, its frequency is increasing in recent years, with an estimated incidence in Europe and the United States of 5% and 50% respectively, and its mortality rate of up to 20% [5,6,7,8]. However, the epidemiology of varicella and its complications is still poorly described in low-income countries.

Sickle cell disease, a genetic hemoglobin disorder with autosomal recessive inheritance, is a frequent cause of immunosuppression in sub-Saharan Africa. It leads to increased susceptibility to infections [9].

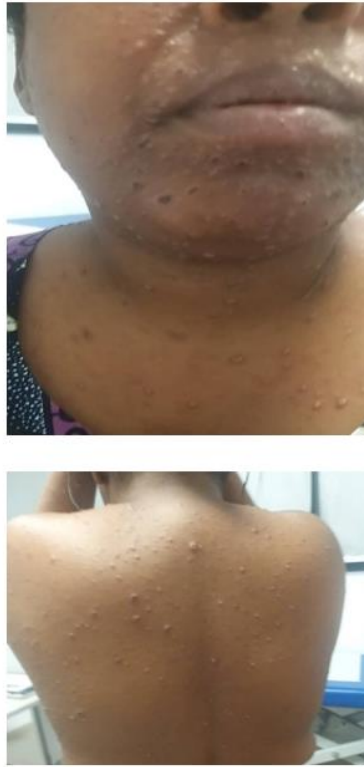When pulmonary involvement occurs during chickenpox in a patient with sickle cell disease, it can be challenging to distinguish between varicella pneumonia, bacterial superinfection and an acute chest syndrome. We report a case of varicella complicated by pneumonia in a young adult with sickle cell disease.

2. CASE PRESENTATION

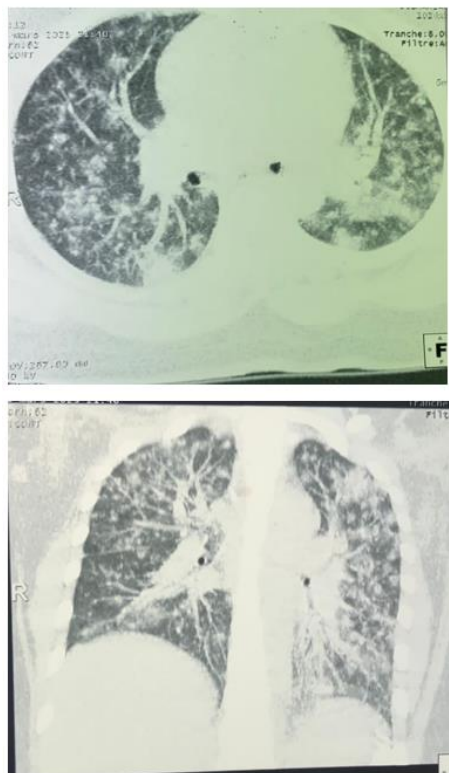
It was a 24-year-old woman with sickle cell disease, on folic acid 5 mg/day, reporting 2 to 3 mild vaso-occlusive attacks per year and a baseline hemoglobin level of 8 g/dl, with no other specific pathological history. Her vaccinations against pneumococcus, meningococcus, hepatitis B and Covid-19 were up to date. Symptoms began by a skin rash, made up of pruritic vesicles and papules. These lesions started on the neck and then extended to the

face, and were associated with fever, headache and insomnia linked to the pruritus. She went to the dermatology department 3 days after and was diagnosed with varicella, a symptomatic treatment was then initiated with cetirizine 10 mg, paracetamol (1000 mg x 3/day) and local care (eosin 2% and emollient gel).

Despite this treatment, the skin lesions became generalized, with a worsening of the initial symptoms, and the patient consult our clinic. Initial examination revealed generalized skin lesions of varying ages (vesicles, pustules, umbilicated papules and crusts), associated with scratching lesions (Figs. 1 and 2). Biological tests revealed anemia (8.8 g/dl), thrombocytopenia ($43,500/\text{mm}^3$), and a biological inflammatory syndrome with hyperleukocytosis ($12,600/\text{mm}^3$), predominantly neutrophils, and a positive C-reactive protein (160 mg/l). Creatinine level was unremarkable. On day 3 of hospitalization, the patient presented an acute respiratory distress with shortness of breath, signs of struggle and desaturation (80% on room air), associated with fever (40°C). Thoracic CT angiography showed pulmonary nodules and micronodules in both lung fields (Fig. 4.). Other laboratory tests revealed microcytic hypochromic anemia (hemoglobin = 6.8 g/dl), hyperleukocytosis ($\text{WBC} = 12,430/\text{mm}^3$), severe thrombocytopenia at $26,000/\text{mm}^3$, C-reactive protein at 160.35 mg/l, procalcitonin at 0.67 ng/ml and hepatic cytolysis with ASAT: 131 u/l and ALAT: 67 u/l. Blood culture isolated *Staphylococcus* spp. The patient received oxygen therapy (5 l/minute), combined with antiviral treatment based on oral aciclovir (1000 mg/day), antibiotic therapy (ceftriaxone 2 g/day) and preventive anticoagulation (Enoxaparin 0.4 ml/day). Other etiological tests were negative (TB PCR and Covid test). The course was marked by a regression of symptoms, with disappearance of respiratory distress on day 2 and apyrexia on day 3 of treatment. The follow-up chest CT scan carried out at 4 months came back normal (Fig. 5).



Figs. 1 and 2. Lesions of different ages (vesicles, pustules, umbilicated papules and crusts)



Figs. 3 and 4. Thoracic CT scan showing diffuse pulmonary nodules and micronodules in both lung fields

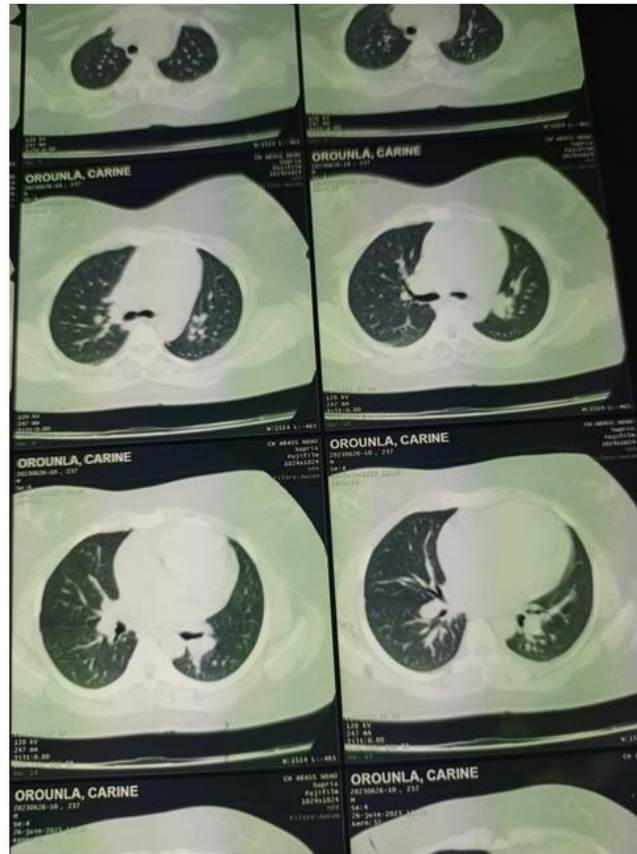


Fig. 5. Normal CT scan at month 4

3. DISCUSSION

The clinical presentation of chickenpox is a papulovesicular rash with intense pruritus and fever, most often occurring in early childhood [10]. Adults are affected in 20% of cases, with a 20-fold increase in the risk of complications compared with children [11]. One of the major complications of chickenpox is varicella pneumonia, which has an incidence of 16-33% and a mortality rate of over 20% [8]. Pulmonary involvement follows visceral dissemination of VZV and usually occurs in 1 to 7 days after rash onset. Symptoms include dry cough with occasional hemoptysis, chest pain, shortness of breath, fever, and sometimes a quickly evolving acute respiratory distress [12,13]. Chest imaging usually reveals well-limited nodules scattered over both lung fields, more rarely unsystematized helioform opacities or heterogeneous nodules, which may be associated with "ground-glass" images around these nodules or scattered in a mosaic pattern [14,15].

The risk factors identified for varicella pneumonia are smoking, immunosuppression, chronic lung

diseases, pregnancy, and a skin involvement with more than 100 elements [6,8,16].

Sickle cell patients have an increased susceptibility to infections, particularly pulmonary infections, which are mainly due to encapsulated bacteria [17,18]. Furthermore, sickle cell disease is itself a source of another pulmonary complication, the acute chest syndrome (ACS), which is defined by the association of any new chest radiological image with one or more of the following symptoms: fever, chest pain and respiratory signs (cough, dyspnea, wheezing, intercostal draught or nasal flaring, hemoptysis, etc.) [19,20]. Several clinical circumstances may cause ACS, either alone or in combination (hypoventilation, pulmonary infection or vascular occlusion), leading to reduced alveolar exchanges [21].

Therefore, it can be difficult to diagnose varicella pneumonia in patients with sickle cell disease, considering the diverse and sometimes intricate etiologies of pulmonary involvement. In our patient, even though the chest CT scan strongly reinforced the suspicion of varicella pneumonia,

the isolation of a staphylococcal strain on blood culture raised doubts about the bacterial origin of the pulmonary involvement. An acute chest syndrome cannot be formally ruled out, given the acute infection that may have triggered it.

In any case, the diagnosis of varicella pneumonia remains highly probable when respiratory symptoms occur after a skin rash suggestive of chickenpox, associated with bilateral interstitial lung disease, in high-risk patients. VZV polymerase chain reaction (PCR) and more rarely bronchial endoscopy (which may reveal vesicular lesions in the bronchial mucosa) can help to confirm the diagnosis. Other complications due to the viral dissemination have been described, including hepatic cytolysis, which was also found in our patient [14].

Treatment for varicella pneumonia remains intravenous acyclovir (10 mg/kg every 8 hours), or valaciclovir or ganciclovir for seven to ten days [6,8,15,22]. This treatment is often combined with local care, high-flow oxygen therapy and antibiotic therapy if superinfection is suspected. Clinical and radiological outcome is favourable when treatment is initiated early [15]. Our patient was treated with oral acyclovir (due to the unavailability of the injectable form in our country), antibiotic therapy and oxygen therapy, with a good clinical course and disappearance of radiological lesions at month 4 of follow-up (Fig. 5). Cases of death with lesional oedema and multi-organ failure have been reported in the literature, more frequently in immunocompromised patients and pregnant women, and usually, they are due to delayed management and no use of antiviral drugs [8,22].

The preventive measures, recommended for non-immune subjects, involve isolation and preventive treatment with immunoglobulins or acyclovir. The indications differ depending on whether prevention is envisaged before or after exposure to the virus, and on the subject exposed (immunocompetent, immunocompromised, or pregnant woman) [6].

4. CONCLUSION

Varicella pneumonia is one of the most frequent complications of chickenpox in adults, and requires searching for an underlying condition in those patients. In sickle cell disease, which is a frequent cause of immunodepression in our context, pulmonary varicella can be difficult to diagnose, given the frequency of lung involvement of various etiologies. Its treatment

involves early use of antiviral therapy such as acyclovir, which reduces mortality.

CONSENT

As per international standards or university standards, patient(s) written consent has been collected and preserved by the author(s).

ETHICAL APPROVAL

It is not applicable.

COMPETING INTERESTS

Authors have declared that no competing interests exist.

REFERENCES

1. University College of Infectious and Parasitic Diseases. Chickenpox, Shingles. Dance. PILLY Too much. 3rd web edition. Updated June 2022. www.infectiologie.com page. 2022;716-719.
2. Bennett JE, Dolin R, Blaser MJ. Mandell, Douglas and Bennett's Principles and practice of infectious diseases. 9th ed. Toronto: Elsevier Canada; 2019. Google Scholar
3. University College of Infectious and Parasitic Diseases. Varicella-zoster virus infection: Infectious and tropical diseases. In: E Pilly. 26th ed. 2017;421-424
4. World Health Organization. Varicella and herpes zoster vaccines: WHO position paper, June 2014. *Weekly Epidemiological Record*. 2014;89(25): 265-287.
5. Bertelli A, Carta V, Mangeri L, Caruso A, De Francesco MA. Varicella-Zoster Virus Prevalence among Pregnant Women: A European Epidemiological Review. *Life*. 2023;13:593. Available:<https://doi.org/10.3390/life13020593>
6. Benjelloun H, Zaghba N, Yassine N et al. Varicella pneumonia associated with bilateral pleurisy in an immunocompetent adult. *Rev Pneumol Clin*. 2013;69(5):287-290.
7. De Wals - Marc Brisson, N. Burden of chickenpox and shingles in Quebec, 1990-2008: Impact of the universal vaccination program, National Institute of Public Health of Quebec. Canada. Available:<https://policycommons.net/artifacts/2060762/fardeau-de-la-varicelle-et-du>

- zona-au-quebec-1990-2008/2813853/ on 04 Feb 2024. CID: 20.500.12592/gfr86s.
8. Kluger N, Puisto R, Suhonen J, Mazur W. Disseminated varicella zoster virus and herpes simplex virus co-infection in a lung-transplant recipient. *Ann Dermatol Venereol.* 2022;149(1): 71–3.
 9. Mattioni, Sarah, Stojanovic, Katia Stankovic, Girot, Robert et al. Sick cell anemia in France. *Rev Franc Lab.* 2016;(481): 61-66.
 10. Floret D. Chickenpox and shingles in children. *Journal of Pediatrics and Childcare.* 2020;33 (2): 52-68.
 11. Asse KV, Rekik H, Ropert JC et al. Fulminant pneumonia during chickenpox in an immunocompetent 16-month-old girl. *Arch Ped.* 2012;19(10):1074-1078.
 12. Ovetchkine P, Reinertn P. Chickenpox. *Encycl Med Chir (Infectious Diseases);* 2007.
 13. Aissa I, Darouaz S, Khattab A et al. Pleural and lung complications of chickenpox in the immunocompetent adult. *Rev Tun Infect.* 2009;3(1):33 – 36.
 14. Zhang M, Yang C, Guo Y. Computed tomography manifestations of a case of varicella zoster virus (VZV) pneumonia. *Respirology Case Reports.* 2023;11:01242. Available: <https://doi.org/10.1002/rcr2.1242>
 15. Jordan Mah, Anthony Lieu, Emma Heck, Danica Quickfall and Alejandra Ugarte-Torres. Primary varicella in 2 adult immigrants to Canada. *CMAJ.* 2023 February 27;195:300-303. DOI: 10.1503/cmaj.220951
 16. Nanthakumar MP, Sood A, Ahmed M, Gupta J. Varicella Zoster in pregnancy. *Eur J Obstet Gynecol Reprod Biol.* 2021; 258:283–287. [CrossRef]
 17. Ahmed SG. The role of infection in the pathogenesis of vaso-occlusive crisis in patients with sickle cell disease. *Mediterr J Hematol Infect Dis.* 2011;3(1):2011028. DOI: 10.4084/MJHID.2011.028. Epub 2011 Jul 8. PMID: 21869914; PMCID: PMC3152450.
 18. Cannas G, Merazga S, Viro E. Sick Cell Disease and Infections in High- and Low-Income Countries. *Mediterr J Hematol Infect Dis.* 2019 Jul 1;11(1):2019042. DOI: 10.4084/MJHID.2019.042. PMID: 31308918; PMCID: PMC6613623.
 19. Koehl JL, Koyfman A, Hayes BD, Long B. High risk and low prevalence diseases: Acute chest syndrome in sickle cell disease. *The American Journal of Emergency Medicine.* 2022;58: 235-244.
 20. Elizabeth S. Klings & Martin H. Steinberg. Acute chest syndrome of sickle cell disease: genetics, risk factors, prognosis, and management, Expert Review of Hematology. 2022; 15(2):117-125, DOI: 10.1080/17474086.2022.2041410
 21. Ouakil N, Benaziz H, Moussounda Mpika GS, Ijim M, Fikri O, Amro L. Varicella Pneumonia in Immunocompetent Adult: Clinical Case. *Sch J Med Case Rep.* 2023;11(12):2138-2141.
 22. Lamont RF, Sobel JD, Carrington D, Mazaki-Tovi S, Kusanovic JP, Vaisbuch E, Romero R. Varicella-zoster virus (chickenpox) infection in pregnancy: Chickenpox infection in pregnancy. *BJOG.* 2011;118:1155–1162. [CrossRef] [PubMed]

© Copyright (2024): Author(s). The licensee is the journal publisher. This is an Open Access article distributed under the terms of the Creative Commons Attribution License (<http://creativecommons.org/licenses/by/4.0>), which permits unrestricted use, distribution, and reproduction in any medium, provided the original work is properly cited.

Peer-review history:
The peer review history for this paper can be accessed here:
<https://www.sdiarticle5.com/review-history/113592>