

Prevalence of Mitral Valve Regurge with or without Prolapse and Left Atrial Volume among Patients with Secundum Type Atrial Septal Defect

Riham GabAllah Elgebaly^{a*}, Aliaa Elsayed Shaban^a, Ayman Ahmed Elsheikh^a,
Timoor Moustafa AbdAllah^a and Raghda Ghonemy Elsheikh^a

^a Cardiovascular Medicine Department, Faculty of Medicine, Tanta University, Tanta, Egypt.

Authors' contributions

This work was carried out in collaboration among all authors. All authors read and approved the final manuscript.

Article Information

DOI: 10.9734/CA/2022/v11i430224

Open Peer Review History:

This journal follows the Advanced Open Peer Review policy. Identity of the Reviewers, Editor(s) and additional Reviewers, peer review comments, different versions of the manuscript, comments of the editors, etc are available here: <https://www.sdiarticle5.com/review-history/89438>

Original Research Article

Received 18 May 2022
Accepted 22 July 2022
Published 28 July 2022

ABSTRACT

Background: An atrial septal defect (ASD) is a persistent interatrial communication. It is distinct from a patent foramen ovale wherein there is a flap with intermittent communication. The aim of this work was to assess prevalence of mitral valve regurge or prolapse and left atrial volume in patients with secundum type ASD.

Methods: This prospective study was carried out at the cardiovascular department, Tanta University Hospitals on 140 patients either adult or children who were diagnosed as atrial septal defect by 2-D echocardiography. They were subjected to detailed history, detailed clinical examination, chest x-ray and echocardiography (2-D echo & Doppler).

Results: 95% of patients were trivial or mild mitral regurgitation, 3.6% were moderate and 1.4% were severe. Cause of mitral valve regurgitation was 2.86% prolapse, 1.43% rheumatic and 0.71 dysplastic. Left atrial enlargement was found in 2.1% of patients. Mean LA diameter was 34.68 ± 3.9 mm, mean LA volume was 45.75 ± 3.44 ml and mean LA volume index was 24.14 ± 2.97 ml/m². 1.43% of patients have history of rheumatic fever. 51.4% of patients presented with fatigue, 45.7% presented with palpitation, 41.4% of the patients presented with exertional dyspnea and 22.8% presented with tachypnea.

Conclusions: The prevalence of mitral regurgitation is low in secundum ASD. Mitral regurgitation associated with secundum atrial septal defect could exist as a coexistent lesion, its recognition is important and most of them could be repaired with satisfactory results. Also, the left atrial volume was not affected except in sever mitral regurgitation.

*Corresponding author: E-mail: romabooka101@gmail.com;

Keywords: Mitral valve; regurge; prolapse; secundum; atrial septal defect; left atrial volume.

1. INTRODUCTION

An atrial septal defect (ASD) is a persistent interatrial communication. It is distinct from a patent foramen ovale wherein there is a flap with intermittent communication. ASD types strictly include ostium secundum (~75% of cases), ostium primum (15- 20%), and sinus venosus (5-10%), while rare coronary sinus defects are closely related [1].

The ostium secundum atrial septal defect is the most common type of atrial septal defect, and comprises 6- 10% of all congenital heart diseases. The secundum atrial septal defect occurs in the fossa ovalis, the central part of the atrial septum as a result of either excessive resorption of the septum primum or deficient growth of septum secundum. In case of excessive resorption of the septum primum, the defect is central with one or multiple holes. In case of abnormal development of the septum secundum, the defect is superiorly located and larger [2].

Surgical closure of atrial septal defects has been shown to have excellent results in both medium and long term studies [3]. Septal occluder devices such as the Amplatzer Septal Occluder (ASO) are now used in closure of secundum ASDs, This device has now become an accepted alternative to surgical repair to decrease complication rates, shorten hospital stays and cost-effectiveness [4].

Mitral regurgitation (MR) associated with secundum Atrial Septal Defect (ASD) is not widely recognized but the association is not unusual. MR has been found in less than 10% of adults with large ASD which is mainly caused by mitral valve prolapse (MVP) [5]. Mild mitral regurgitation (MR) associated with ASD is often improved after shunt closure which reduces right ventricular volume overload and restores ventricular septal configuration [6].

This study aimed to assess prevalence of mitral valve regurge or prolapse and left atrial volume in patients with secundum type ASD.

2. PATIENTS AND METHODS

This prospective study carried out 140 patients, 95 females and 45 males either adult or children, their ages ranged from 2 year to 48 years old

and diagnosed with ostium secundum Atrial Septal Defect by 2- D echocardiography. The study also included 30 patients as control group, age and sex matched with the patient group.

This study was conducted at the cardiovascular department, Tanta University Hospitals from June 2018 to December of 2020.

Hemodynamic unstable patients, small non-significant ASDs (less than or equal to 5ml), bad echo window, significant arrhythmia as ventricular arrhythmia, associated other congenital anomalies or complex lesions, unwilling patient were excluded.

All patients were submitted to:

Full history taking: With a special emphasis on patient's age, gender, family history and history of chronic disease.

Detailed clinical examination: General and local examination including body mass index (BMI), blood pressure, pulse, temperature, respiratory rate and local examination of the heart and lung and other systems.

Chest x-ray: Chest x-ray was done searching for cardiomegaly (right ventricle and right atrial enlargement), a prominent pulmonary artery segment and increased pulmonary vascular markings.

ECG: 12 leads ECG was done to detect heart rate, rhythm, right atrial over load, axis deviation and notching of R wave in inferior leads which is called crochetae sign in ASD.

Echocardiography, 2D echo & doppler was performed in all patients of ASD to obtain: Diagnosis of ASD, Mitral valve morphology, Estimation of the degree of mitral incompetence if present, Measurement of the left atrial volume by biplane modified Simpson (SIMP).

All patients were studied by an expert cardiologist using an ultrasound Vivid E9 (GE Healthcare, Milwaukee, WI) platform, with probe frequencies appropriate for body habitus and age. Gain and compression were optimized. Studies were performed with subject's breathing room air and echo Pac software for offline analysis.

The echocardiographic examination took place with the patient in the supine position or in left lateral semi recumbence. According to recommendation of ASE Standard 2D and M-mode echocardiograms were obtained in the apical 4 chamber, apical 2 chamber, apical 3 chamber, subcostal, suprasternal and left parasternal views with simultaneous ECG signals [7].

Diagnosis of ASD: The atrial septum can be evaluated fully using TTE. For defining the type of defect and its relationship to other structures, multiple views should be used. Subcostal sagittal and coronal views are best to define the ASDs [7]. The apical four-chamber view can also be especially useful in evaluation of the right heart. We do Visualization of ASD and characterization of its size, Determination of the direction of flow (by color doppler), Examination of right heart (by A4c view).

Mitral valve morphology: We evaluate the mitral valve by parasternal long- and short-axis views, allow direct visualization of mitral valve scallops and leaflet motion. Also, we detect if there is mitral regurgitation or not and assessing its severity as well as evaluating the etiology and mechanism of MR. M-mode allows accurate diagnosis of the mechanism of MR in patients with MV prolapse, adding color Doppler M-mode improves its diagnostic accuracy and helps determine whether MR is holosystolic or mid or late systolic, central or eccentric jet.

In case of presence of MR, we assess the severity of regurgitation by either semi quantitative assessment (Vena Contracta VC) or quantitative assessment (effective regurgitant orifice area EROA) [8]. $EROA = [(2r^2 \times V_{pisa}) / V_{mr}]$ (r: radius, PISA: proximal isovelocity surface area, vmr: mitral regurge velocity). To optimize the measurement of VC, the view that is

perpendicular to the jet width such as parasternal long-axis or 4-chamber views should be used.

Measurement of the left atrial volume by biplane modified Simpson (SIMP): Echocardiographic tracings were made in the apical long-axis two- and four-chamber views at end-systole (maximum LA size), just prior to MV opening. The LA endocardial border was traced, and the volumes were calculated. The LA appendage and the pulmonary veins confluence were excluded from the LA tracings, and a straight line was traced between the attachment points of the mitral annulus with the valve leaflets.

2.1 Statistical Analysis

All data were collected, tabulated and statistically analyzed using SPSS 22.0 for windows (SPSS Inc., Chicago, IL, USA). Qualitative data were represented as frequencies and relative percentages. Chi square test (χ^2) and Fisher exact was used to calculate difference between qualitative variables as indicated. Quantitative data were expressed as mean \pm SD (Standard deviation) and compared by unpaired T test. Multiple regression analysis was used. All statistical comparisons were two tailed with significance Level of P-value \leq 0.05 indicates significant.

3. RESULTS

There is no statistical significance in demographic data between patients and control [Table 1].

51.4% of patients presented with fatigue, 45.7% of patients presented with palpitation, 41.4% of the patients presented with exertional dyspnea, 22.8% presented with tachypnea and 7.8% were asymptomatic Fig. 1.

Table 1. Demographic characteristics among studied patients

		Patients (n=140)	Control (n=30)	P value
Age (years)	Range	2 – 48	6 – 43	0.594
	Mean \pm SD	27.81 \pm 15.21	29.31 \pm 4.25	
Sex	Male	45 (32.1%)	10 (33.3%)	0.899
	Female	95 (67.8%)	20 (66.7%)	
BMI (kg/m ²)	Mean \pm SD	24.92 \pm 3.65	23.85 \pm 3.18	0.139
Residence	Rural	82 (58.6%)	18 (60%)	0.885
	Urban	58 (41.4%)	12 (40%)	

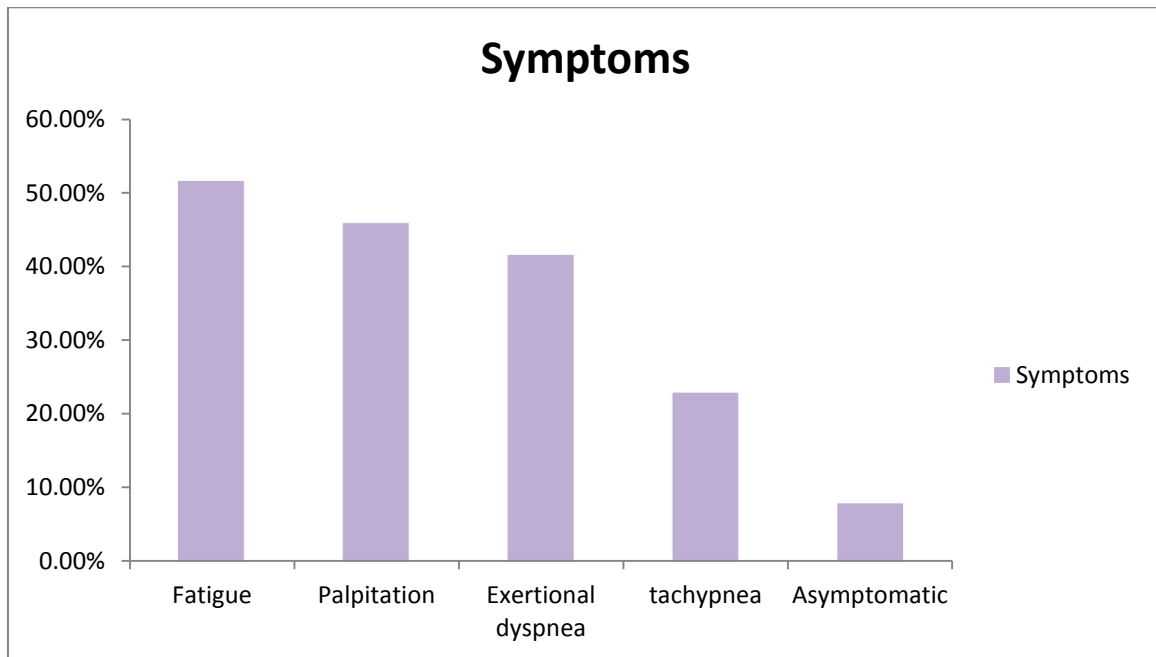


Fig. 1. Symptoms distributions among the studied patients

Table 2. Comparison of heart rate and blood pressure between patients and control group

Variables	Patients (n=140)	Control (n=30)	F / X ²	P value
HR (beat/min) Mean ± SD	85.64 ± 12.35	78.53 ± 10.61	2.931	0.004*
SBP (mmHg) Mean± SD	131.2 ± 8.63	129.2 ± 7.87	1.169	0.244
DBP (mmHg) Mean± SD	81.14 ± 9.82	78.2 ± 8.32	1.528	0.129

Heart rate was statistically significant between patients and control. SBP and DBP were insignificantly different between both groups [Table 2].

2.8% of patients have mitral prolapse. (N.B: In control group, patients with mitral prolapse were excluded.) [Table 3].

LA diameter ranged from 27mm to 44mm with a mean value of 34.68 ± 3.9 mm, LA volume ranged from 29ml to 60ml with a mean value of 45.75 ± 3.44 ml, LA volume index ranged from 18 ml/m² to 31 ml/m² with a mean value of 24.14 ± 2.97 ml/m² in patients. LA diameter ranged from 29mm to 39mm with a mean value of 35.19 ± 3.4 mm, LA volume ranged from 28ml to 48ml with a mean value of 43.19 ± 7.62 ml and LA volume index ranges from 17 ml/m² to 28 ml/m² with a mean value of 23.17 ± 3.52 ml/m² in control group. (LA volume index = LA volume / body surface area). (Non-significant difference

between patients and control group in LA parameters) [Table 4].

Regarding mitral regurgitation severity, (93%) of the patients were mild or trivial, and 5% were moderate and 1.4% were severe. There was no moderate or severe mitral regurgitation among the control group. (Non-significant difference between patients and control group according to MR) [Table 5].

Regarding mitral valve morphology 95% were average, 1.43% were rheumatic and 0.71% were dysplastic, and none was flail [Fig. 2].

There was non-significant difference between patients and control group in Echo parameters [Table 6].

Heart rate and mitral valve regurgitation were significant, other parameters showed no significant difference [Table 7].

Table 3. Electrocardiographic findings and mitral prolapse frequency among ASD patients

		Patients (n=140)	
		N	%
P-R interval	Normal	120	85.7
	Prolonged	20	14.2
Sinus tachycardia		96	68.5
Atrial fibrillation		4	2.8
Atrial premature beats		3	2.1
Axis deviation from normal	RAD	34	24.2
Right bundle branch block	Incomplete	57	40.7
Atrial enlargement	Right	57	40.7
	Left	3	2.1
Mitral prolapse frequency			
Non-prolapse		136	97.1
Mitral value prolapse		4	2.8

Table 4. Comparison between LA parameters of patients and control group

Variables	Patients (n=140)	Control (n=30)	T test	P value
LA diameter (mm)	27 – 44	29 – 39	0.662	0.508
Mean± SD	34.68 ± 3.9	35.19 ± 3.4		
LA volume (ml)	29 – 60	28 – 48	1.423	0.158
Mean± SD	45.56 ± 8.44	43.19 ± 7.62		
LA volume index (ml/m ²)	18 – 31	17 – 28	1.238	0.218
Mean± SD	24.14 ± 3.97	23.17 ± 3.52		

Table 5. Prevalence of mitral regurgitation and severity distribution among the studied groups

	Patients (n=140)		Control (n=30)		X ²	P value
	N	%	N	%		
Trivial or Mild	131	93.57	30	100	2.038	0.154
Moderate	7	5	0	0	1.562	0.211
Severe	2	1.4	0	0	0.429	0.510

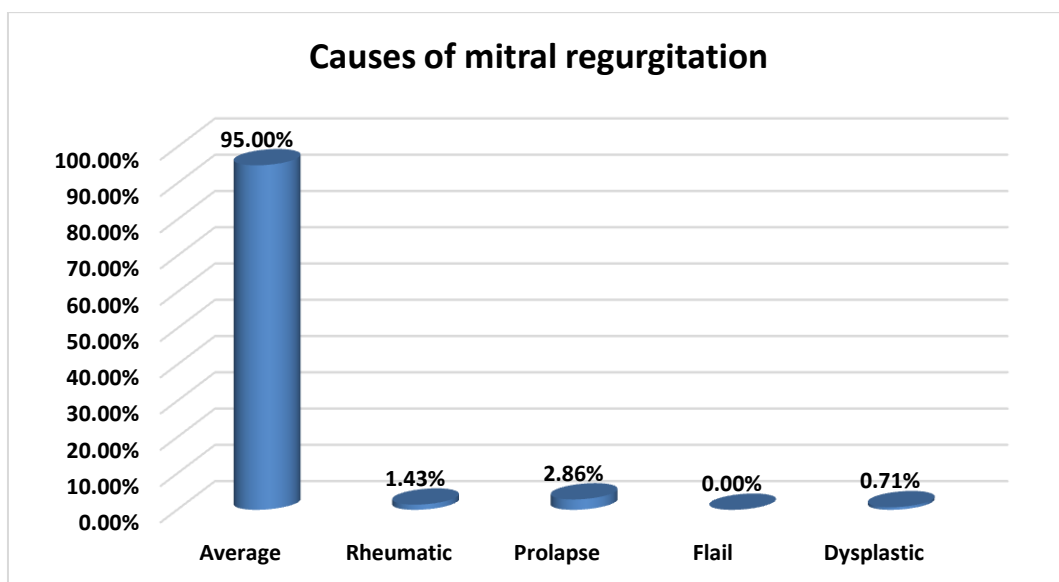


Fig. 2. Distribution of patients as regards causes of mitral regurgitation

Table 6. Relationship of echo parameters between patients and control

Variables	Patients (n140)	Control (n30)	T	P
Mitral valve regurge	9(6.7%)	0(0%)	2.039	0.154
Mitral valve prolapse	4(2.8%)	0(0%)	0.882	0.349
LVD	50.37 ± 5.61	48.92 ± 4.98	1.308	0.192
LVV	84.68 ± 17.52	79.67 ± 14.62	1.458	0.146
LVVI	76.91 ± 12.67	73.67 ± 11.49	1.286	0.198
LVEDD	4.61 ± 1.06	4.49 ± 0.98	0.569	0.570
LVSD	3.06 ± 0.34	2.97 ± 0.32	1.331	0.186
FS	38.24 ± 5.13	36.79 ± 4.18	1.449	0.150
EF (%)	59.13 ± 5.37	57.89 ± 4.98	1.159	0.247
Mean± SD				
LA diameter (mm)	34.68 ± 3.9	35.19 ± 3.4	0.662	0.508
Mean± SD				
LA volume (ml)	45.56 ± 8.44	43.19 ± 7.62	1.423	0.158
Mean± SD				
LA volume index (ml/m ²)	24.14 ± 3.97	23.17 ± 3.52	1.238	0.218
Mean± SD				

LVD: left ventricular diameter, LVV: left ventricular volume, LVVI: left ventricular volume index, LVEDD: left ventricular end diastolic diameter, LVSD: left ventricular end systolic diameter, FS: fractional shortening, EF: ejection fraction LA: left atrium

Table 7. Multiple regression analysis

Variables	OR	95% CI	P value	
Age (years)	0.652	0.187 – 5.324	0.215	
BMI (kg/m ²)	0.748	0.352 – 4.326	0.297	
Sex	0.485	0.358 – 2.627	0.195	
HR (beat/min)	0.584	0.234 – 0.745	0.008*	
SBP (mmHg)	0.589	0.269 – 4.526	0.325	
DBP (mmHg)	0.954	0.487 – 6.852	0.415	
MVR	0.358	0.058 – 0.745	0.005*	
MVP	2.512	0.548 – 9.215	0.095	
Rheumatic	3.627	0.579 – 11.652	0.106	
Dysplastic	2.528	0.495 – 8.526	0.149	
ECG parameters	P-R interval	0.685	0.418 – 5.632	0.258
	Sinus tachycardia	0.754	0.189 – 8.526	0.315
	Atrial fibrillation	0.398	0.148 – 2.323	0.362
	Atrial premature beats	0.428	0.298 – 5.638	0.418
	Axis deviation from normal	0.587	0.449 – 9.321	0.527
	Right bundle branch block	0.815	0.741 – 15.325	0.467
	Right Atrial enlargement	0.816	0.598 – 7.526	0.319
	Left Atrial enlargement	0.937	0.325 – 12.525	0.125
	LVD	0.524	0.148 – 5.214	0.296
	LVV	0.165	0.025 – 4.236	0.197
Echo parameters	LVVI	0.267	0.108 – 14.236	0.419
	LVEDD	0.419	0.327 – 2.308	0.338
	LVSD	0.168	0.039 – 5.412	0.259
	FS	0.519	0.257 – 1.635	0.137
	EF	0.354	0.249 – 6.527	0.208
	LA diameter	0.451	0.264 – 11.365	0.418
	LA volume	0.748	0.317 – 8.632	0.157
	LA volume index	0.408	0.207 – 5.631	0.216

LVD: left ventricular diameter, LVV: left ventricular volume, LVVI: left ventricular volume index, LVEDD: left ventricular end diastolic diameter, LVSD: left ventricular end systolic diameter, FS: fractional shortening, EF: ejection fraction LA: left atrium

4. DISCUSSION

The results demonstrated that 60% of patients have history of rheumatic fever. Another study by Ba-Saddik et al. [9] reported that mitral regurgitation was detected in 49.8% of rheumatic fever patients and 26.6% of them had mitral regurgitation with mitral valve prolapse.

Mitral regurgitation associated with secundum atrial septal defect could exist as a coexistent lesion or as the result of hemodynamic change occurred in secundum atrial septal defect. The etiologies are rheumatic valve and chronic infective endocarditis. Because of recurrent rheumatic fever, a large proportion of these patients have chronic rheumatic mitral valve disease requiring surgery [10].

In the current study, 51.4% of patients presented with fatigue, 45.7% presented with palpitation, 41.4% of the patients presented with exertional dyspnea and 22.8% presented with tachypnea.

This agrees with Haque et al. [11], who found that 76.66% and 56.66% of study patients presented with shortness of breath on exertion and fatigue, respectively. Other symptoms as palpitation, chest pain and recurrent respiratory infection was also reported.

Our results are supported by another study in which of all 80 patients with ASD, 62 reported exertional dyspnea (78 %) [12].

The most common presenting symptoms of ASD at adult age are palpitations and exercise intolerance manifested as either exertional dyspnea or fatigue, which increase with age [13]. From the result of this study, 2.8% were suffering from atrial fibrillation. The findings of another study indicated 40 % of the patients were suffering from atrial fibrillation [14].

Atrial arrhythmias or atrial fibrillation are significantly increased in patients with ASD. In unoperated adults, the estimated incidence of atrial arrhythmias is approximately 10 % under the age of 40 years, rising to at least 20 % with increased age, pulmonary arterial pressure and systemic hypertension. the incidence is increased in male patients, those with chronic obstructive pulmonary disease, reduced ejection fraction and hypertension [15].

ASD is associated with a high incidence of atrial arrhythmias that increase in frequency as the

patient ages. The later in life the ASD is repaired, the more likely atrial arrhythmias are to develop. Closure does not mitigate the development of arrhythmias [16].

Remodeling of both the right and left atrium contributes to arrhythmogenesis and the heterogeneity of that remodeling process between atria may contribute to the propensity for native arrhythmias in this patient group [17].

The results of this study demonstrated that 85.7% of patients presented with normal P-R interval, 68.5% with sinus tachycardia, 40.7% with incomplete right bundle branch block, 24.2% with axis deviation from normal, 2.8% with atrial fibrillation and 2.1% with atrial premature beats.

The results of this study agree with those of Bayar et al. [18] that reported incomplete right bundle branch block (56% vs. 5%), were more frequent in ASD patients compared to the control group patients.

ECGs of patients with ASD can be normal, or exhibit a large right atrium, large right ventricle, incomplete right bundle branch block, extended PR intervals, right axis deviation, or atrial arrhythmia [19].

ECG may be normal in young and uncomplicated patients with ASD. However, the classical findings of significant ASD are prolonged PR interval, QRS time, and the presence of incomplete right bundle branch block. ECG findings may change according to the type of ASD. Ostium secundum ASDs are the most frequent and are related to right axis deviation and incomplete right bundle branch block [20].

In this study, 93.5% were trivial or mild mitral regurgitation, 5% were moderate and 1.4% were severe. In agreement, Nishimura et al. [21] found that regarding severity mitral regurgitation was none in 60% of patients, mild in 39.5% of, and moderate in 0.5% of patients.

In contrast with our results Mayasari et al. [22] reported that the incidence of mitral regurgitation is 79.5% in subjects with defect ≥ 2 cm.

“Prevalence recognition is important because the clinical course of mitral regurgitation is altered by the presence of an atrial septal defect. Some patients with severe mitral regurgitation may not manifest symptoms of mitral regurgitation because the atrial septal defect unloads the left

atrium. If residual mitral regurgitation is significant following atrial septal defect closure, increased left atrial and pulmonary venous pressure develop and may produce or increase symptom. Closure of the atrial septal defect without repair of mitral regurgitation so might increase postoperative morbidity and mortality rates” [23].

The current study results showed the most prevalent causes were mitral valve prolaps in 4 patients, rheumatic heart disease in 2 patients or dysplastic mitral valve in 1 patient, also LV diastolic dysfunction was the cause in 3 patients. In another study of Waikittipong et al. [24] who stated that “the etiologies of mitral regurgitation in these 12 patients could be as follow: rheumatic heart disease in 3 patients, prolapsed anterior leaflet in 2 patients, congenital abnormality in 2 patients, specific pathophysiology complex in 4 patients, and chronic bacterial endocarditis in 1 patient”.

The current study results showed that 2.1% had left atrial enlargement. mean LA diameter was 34.68 ± 3.9 mm, mean LA volume was 45.75 ± 3.44 ml and mean LA volume index was 24.14 ± 2.97 ml/m².

In another study of Roberts-Thomson et al. [25] reported that “Patients with ASDs showed significant LA enlargement due to association of chronic left atrial stretch, which results in remodeling characterized by LA enlargement, loss of myocardium, and electrical scar that results in widespread conduction abnormalities”.

Also another study of Muzaffer et al. [26] reported that “The atrial diameters and the volumes are increased in ASD patients due to volume overload. It is known that increased atrial diameters and volume cause prolongation of conduction time, the LA reservoir function as an indicator of the mechanical function was not affected, conduction function was improved. this study show Effects of percutaneous closure of atrial septal defect on left atrial mechanical and conduction functions, but our study discuss the LA volume before closure only”.

Our study show no significant difference in LV parameters, another study of Chul et al.,2021 show augmentation of left ventricular (LV) and left atrial (LA) preload after device closure, they were normal before closure.

On physical examination, a patient with an ASD may have a right ventricular heave, systolic flow

murmur in the pulmonary valve region due to increased pulmonary flow, a fixed split-second heart sound, or a diastolic flow rumble across the tricuspid valve [27].

One of the limitations of this study is that it is a single-center study and may not be representative of the general population. Second, the study population was reported smaller, the effect of defined ECG findings, could not be evaluated for the prognosis. Third, the study was cross sectional in design and could not establish a causal relationship among study variables. Fourth, wide range of age (better one group either children or adults).

5. CONCLUSIONS

The prevalence of mitral regurgitation is low in secundum ASD. Mitral regurgitation associated with secundum atrial septal defect could exist as a coexistent lesion, its recognition is important and most of them could be repaired with satisfactory results. Also, the left atrial volume was not affected except in sever mitral regurgitation.

CONSENT AND ETHICAL APPROVAL

The study was approved by the Ethics Committee of the Faculty of Medicine, Tanta University. An informed consent was obtained from all participants in this research.

COMPETING INTERESTS

Authors have declared that no competing interests exist.

REFERENCES

1. Warnes CA, Williams RG, Bashore TM, Child JS, Connolly HM, Dearani JA, et al. ACC/AHA guidelines for the management of adults with congenital heart disease: a report of the American College of Cardiology/American Heart Association Task Force on Practice Guidelines (Writing Committee to Develop Guidelines on the Management of Adults With Congenital Heart Disease). Developed in Collaboration With the American Society of Echocardiography, Heart Rhythm Society, International Society for Adult Congenital Heart Disease, Society for Cardiovascular Angiography and Interventions, and

- Society of Thoracic Surgeons. *J Am Coll Cardiol*. 2008;52:e143-e263.
2. Blom NA, Ottenkamp J, Jongeneel TH, DeRuiter MC, Gittenberger-de Groot AC. Morphogenetic differences of secundum atrial septal defects. *Pediatr Cardiol*. 2005;26:338-43.
 3. Roos-Hesselink JW, Meijboom FJ, Spitaels SE, van Domburg R, van Rijen EH, Utens EM, et al. Excellent survival and low incidence of arrhythmias, stroke and heart failure long-term after surgical ASD closure at young age. A prospective follow-up study of 21-33 years. *Eur Heart J*. 2003;24:190-7.
 4. Du ZD, Hijazi ZM, Kleinman CS, Silverman NH, Larntz K. Comparison between transcatheter and surgical closure of secundum atrial septal defect in children and adults: results of a multicenter nonrandomized trial. *J Am Coll Cardiol*. 2002;39:1836-44.
 5. Hossain M, Joshi D, Acharya M, Tareq Morshed AJ, Khan O, Sunny S, et al. Congenital Ostium Secundum Atrial Septal Defect with Mitral Valve Prolapse and Mitral Regurgitation – A Case Report and Review of Literature. *University Heart Journal*. 2018;12:91.
 6. Hiraishi M, Tanaka H, Motoji Y, Sawa T, Tsuji T, Miyoshi T, et al. Impact of Right Ventricular Geometry on Mitral Regurgitation After Transcatheter Closure of Atrial Septal Defect. *Int Heart J*. 2015;56:516-21.
 7. Picard MH, Adams D, Bierig SM, Dent JM, Douglas PS, Gillam LD, et al. American Society of Echocardiography recommendations for quality echocardiography laboratory operations. *J Am Soc Echocardiogr*. 2011;24:1-10.
 8. Coats AJS, Anker SD, Baumbach A, Alfieri O, von Bardeleben RS, Bauersachs J, et al. The management of secondary mitral regurgitation in patients with heart failure: A joint position statement from the Heart Failure Association (HFA), European Association of Cardiovascular Imaging (EACVI), European Heart Rhythm Association (EHRA), and European Association of Percutaneous Cardiovascular Interventions (EAPCI) of the ESC. *Eur Heart J*. 2021;42:1254-69.
 9. Ba-Saddik IA, Munibari AA, Al-Naqeeb MS, Parry CM, Hart CA, Cuevas LE, et al. Prevalence of rheumatic heart disease among school-children in Aden, Yemen. *Ann Trop Paediatr*. 2011;31:37-46.
 10. Ali N. Congenital Heart Disease (Atrial Septal Defect) With Rheumatic Heart Disease (Mitral Regurgitation)-A Rare Association. *Journal of Medical Science And clinical Research*. 2017;5.
 11. Haque MS, Khan H, Mahmud RS. Presentation of Atrial Septal Defect (ASD)-Symptoms and Signs. *Journal of Dhaka Medical College*. 2011;20.
 12. Nassif M, Heuschen CB, Lu H, Bouma BJ, van Steenwijk RP, Sterk PJ, et al. Relationship between atrial septal defects and asthma-like dyspnoea: the impact of transcatheter closure. *Neth Heart J*. 2016;24:640-6.
 13. Komar M, Przewlocki T, Olszowska M, Sobien B, Podolec P. The benefit of atrial septal defect closure in elderly patients. *Clin Interv Aging*. 2014;9:1101-7.
 14. Nyboe C, Olsen MS, Nielsen-Kudsk JE, Hjortdal VE. Atrial fibrillation and stroke in adult patients with atrial septal defect and the long-term effect of closure. *Heart*. 2015;101:706-11.
 15. Chubb H, Whitaker J, Williams SE, Head CE, Chung NA, Wright MJ, et al. Pathophysiology and Management of Arrhythmias Associated with Atrial Septal Defect and Patent Foramen Ovale. *Arrhythm Electrophysiol Rev*. 2014;3:168-72.
 16. Karunanithi Z, Nyboe C, Hjortdal VE. Long-Term Risk of Atrial Fibrillation and Stroke in Patients With Atrial Septal Defect Diagnosed in Childhood. *Am J Cardiol*. 2017;119:461-5.
 17. Williams MR, Perry JC. Arrhythmias and conduction disorders associated with atrial septal defects. *J Thorac Dis*. 2018;10:S2940-s4.
 18. Bayar N, Arslan Ş, Köklü E, Cagirci G, Cay S, Erkal Z, et al. The importance of electrocardiographic findings in the diagnosis of atrial septal defect. *Kardiol Pol*. 2015;73:331-6.
 19. Shen L, Liu J, Li JK, Xu M, Yuan L, Zhang GQ, et al. The Significance of Crochetage on the R wave of an Electrocardiogram for the Early Diagnosis of Pediatric Secundum Atrial Septal Defect. *Pediatr Cardiol*. 2018;39:1031-5.
 20. Schiller O, Greene EA, Moak JP, Gierdalski M, Berul CI. The poor performance of RSR' pattern on electrocardiogram lead V1 for detection of

- secundum atrial septal defects in children. J Pediatr. 2013;162:308-12.
21. Nishimura S, Izumi C, Amano M, Miyake M, Tamura T, Kondo H, et al. Incidence and Predictors of Aggravation of Mitral Regurgitation After Atrial Septal Defect Closure. Ann Thorac Surg. 2017;104:205-10.
 22. Mayasari NME, Anggrahini DW, Mumpuni H, Krisdinarti L. The Incidence of Mitral Valve Prolapse and Mitral Valve Regurgitation in Patient with Secundum Atrial Septal Defect. ACI (Acta Cardiologia Indonesiana).1.
 23. Jalal Z, Hascoet S, Baruteau AE, Iriart X, Kreitmann B, Boudjemline Y, et al. Long-term Complications After Transcatheter Atrial Septal Defect Closure: A Review of the Medical Literature. Can J Cardiol. 2016;32:1315.e11-e18.
 24. Waikittipong S. Mitral Regurgitation Associated with Secundum Atrial Septal Defect. The Thai Journal of Surgery. 2010;31.
 25. Roberts-Thomson KC, John B, Worthley SG, Brooks AG, Stiles MK, Lau DH, et al. Left atrial remodeling in patients with atrial septal defects. Heart Rhythm. 2009; 6:1000-6.
 26. Aslan M, Erturk M, Turen S, Uzun F, Surgit O, Ozbay Ozyilmaz S, et al. Effects of percutaneous closure of atrial septal defect on left atrial mechanical and conduction functions. European Heart Journal - Cardiovascular Imaging. 2014;15:1117-24.
 27. Martin SS, Shapiro EP, Mukherjee M. Atrial septal defects- clinical manifestations, echo assessment, and intervention. Clin Med Insights Cardiol. 2014;8:93-8.

© 2022 Elgebaly et al.; This is an Open Access article distributed under the terms of the Creative Commons Attribution License (<http://creativecommons.org/licenses/by/4.0>), which permits unrestricted use, distribution, and reproduction in any medium, provided the original work is properly cited.

Peer-review history:

The peer review history for this paper can be accessed here:
<https://www.sdiarticle5.com/review-history/89438>