

Cryptogenic Stroke with a Patent Foramen Ovale in a Patient with Pulmonary Embolism and Thrombophilia: A Case-based Discussion

Ghali Bennani ^{a*}, Soukaina Zahri ^a, Hanane Choukrani ^a, Salim Arous ^a, Ghali Bennouna ^a, Abdenasser Drighil ^a, Leila Azzouzi ^a and Rachida Habbal ^a

^a *Department of Cardiology, University Hospital of Ibn Rochd, Casablanca, Morocco.*

Authors' contributions

This work was carried out in collaboration among all authors. All authors read and approved the final manuscript.

Article Information

Open Peer Review History:

This journal follows the Advanced Open Peer Review policy. Identity of the Reviewers, Editor(s) and additional Reviewers, peer review comments, different versions of the manuscript, comments of the editors, etc are available here: <https://www.sdiarticle5.com/review-history/92138>

Case Study

Received 24 July 2022
Accepted 28 September 2022
Published 06 October 2022

ABSTRACT

The patent foramen ovale (PFO) is a common abnormality that is often associated with cryptogenic stroke in young people. The management of PFO requires endovascular closure which prevents recurrence better than antithrombotic treatment. In the presence of concomitant thrombophilia, the risk of recurrence of stroke after closure of the PFO is increased, and one needs to institute antithrombotic therapy. The choice and duration of the treatment are controversial. Our study focuses on a 37-year-old patient admitted for ischemic vascular accident in whom a patent foramen ovale was found with an interatrial septal aneurysm (ASIA) on a ground of thrombophilia associated with a left pulmonary embolism and an occlusion. total left internal carotid artery. Since at present, there is no optimal therapeutic strategy for these patients, the indications must be considered on an individual basis. The aim of the clinical case is to relate our experience in the management of cryptogenic stroke associated with PFO on a ground of thrombophilia.

Keywords: *Cryptogenic stroke; patent foramen ovale; hypercoagulability; thrombophilia.*

1. INTRODUCTION

Patent foramen ovale is a congenital hole between the right and the left atria. In 15-30% of the population PFOs tend to persist through adulthood. In the majority of the population PFOs remain asymptomatic, but clinical manifestations are believed to be associated with PFOs, such as cryptogenic stroke, especially in patients with atrial fibrillation [1-3]. The increased risk of ischemic stroke has been reported in several studies in patients with PFOs and acute pulmonary embolism. The risk of ischemic stroke is shown to be higher in patients with PE and PFO compared to those without PFO, as reported by several studies with small number of subjects [4]. The present case study highlights the Cryptogenic stroke with a patent foramen ovale in a patient with pulmonary embolism and thrombophilia.

2. CLINICAL CASE

A 37-year-old patient with no particular pathological history presents for left hemiplegia with dysarthria and exertional dyspnea evolving for 2 months.

The clinical examination found a patient with a tachycardia at 114 bpm with no other associated

abnormalities. Cerebral magnetic resonance imaging objectified a right sylvian ischemic stroke with signs of hemorrhagic infarction (Fig. 1). The electrocardiogram showed sinus tachycardia with an S1Q3 pattern and negative T waves anteriorly. The holter ECG didn't find any particular abnormality.

Transthoracic ultrasound revealed an aspect of acute cor pulmonale with a right ventricle dilated at 49 mm and systemic pulmonary arterial pressures at 73 mmHg (Fig. 2). Pulmonary CT angiography confirmed left pulmonary embolism (Fig. 3). The venous echo-Doppler of the lower limbs did not objectify deep vein thrombosis. Transesophageal ultrasound revealed a PFO with an interatrial septum aneurysm (ASIA) of 16x10 mm (Fig. 4). CT angiography of the supra-aortic trunks showed total occlusion of the left IC without dissection (Fig. 5).

The biological assessment for thrombophilias found a protein C and antithrombin 3 deficiency. The assay was taken as part of an immunological assessment, before taking any treatment. No genetic test could be performed.

The decision was to administer the patient unfractionated heparin and then anticoagulant treatment based on acenocoumarol.

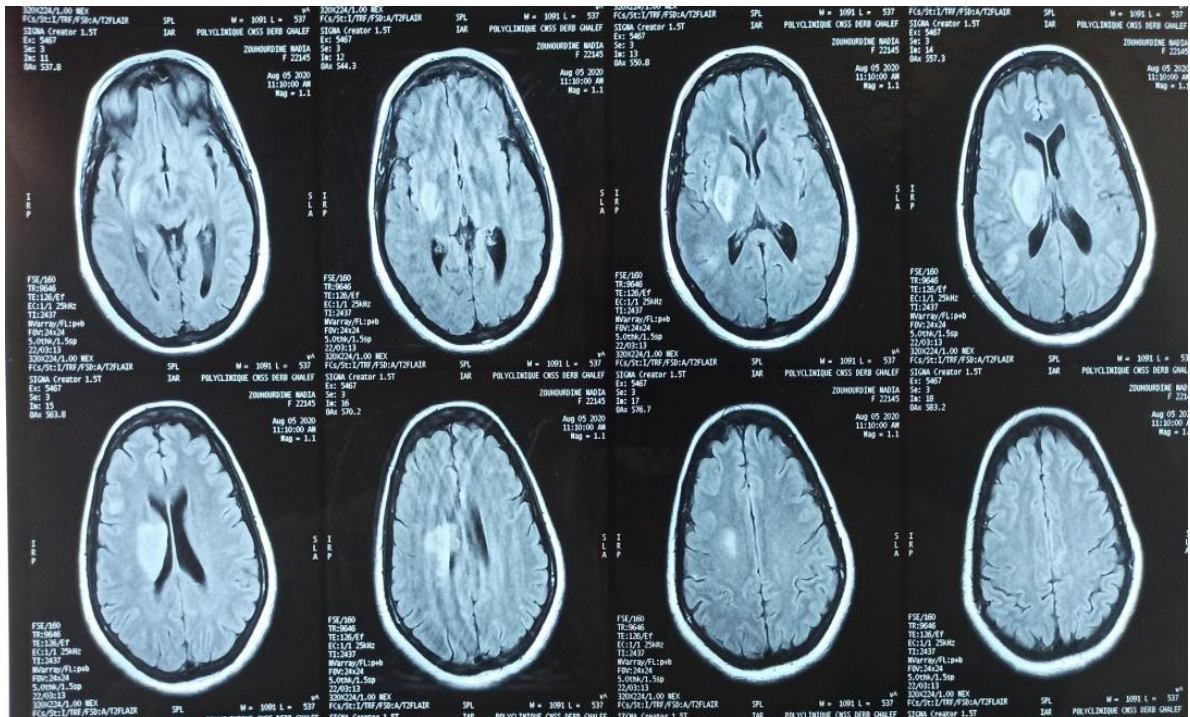


Fig. 1. Brain MRI

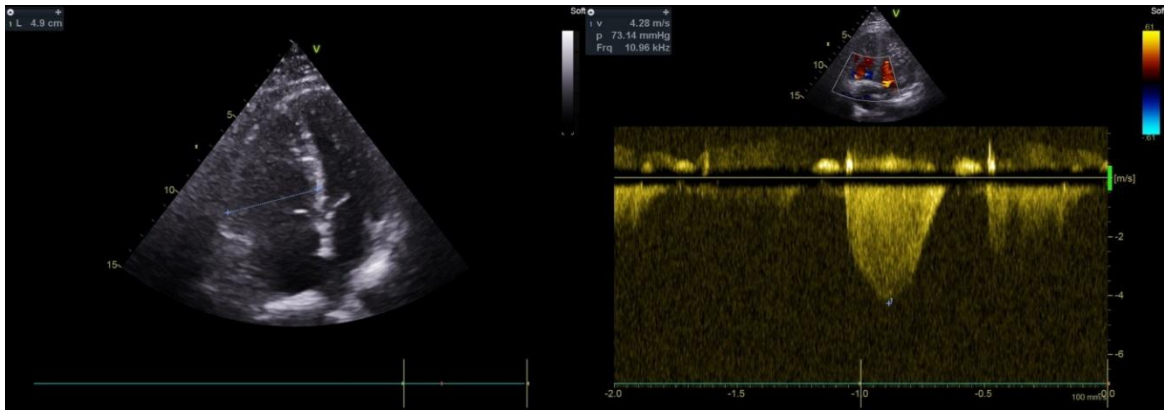


Fig. 2. ETT

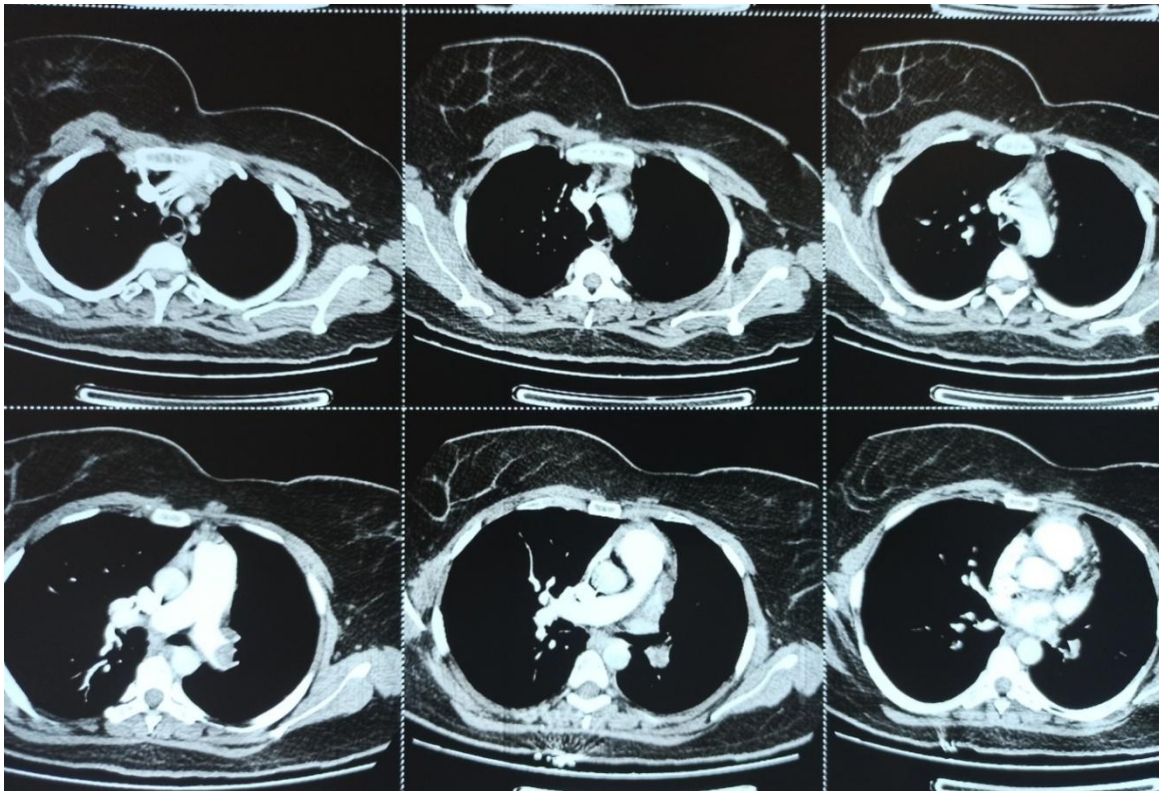


Fig. 3. Chest CT angiography

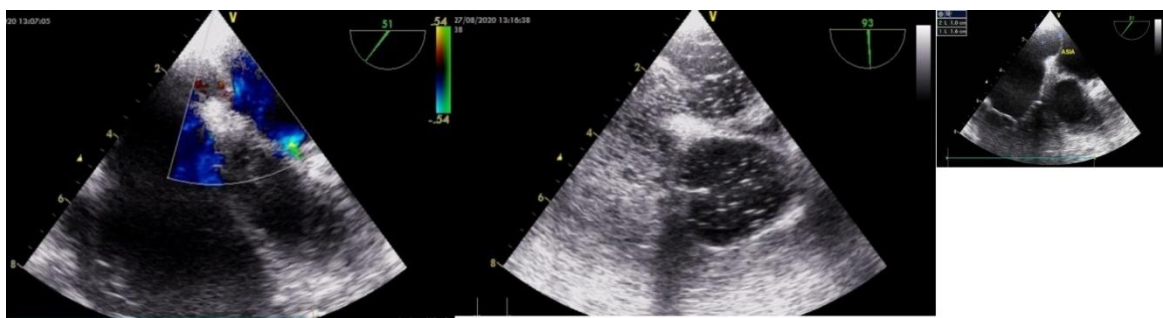

Fig. 4. ETO, a: PFO ; b: Bubble test ; c: interatrial septal aneurysm

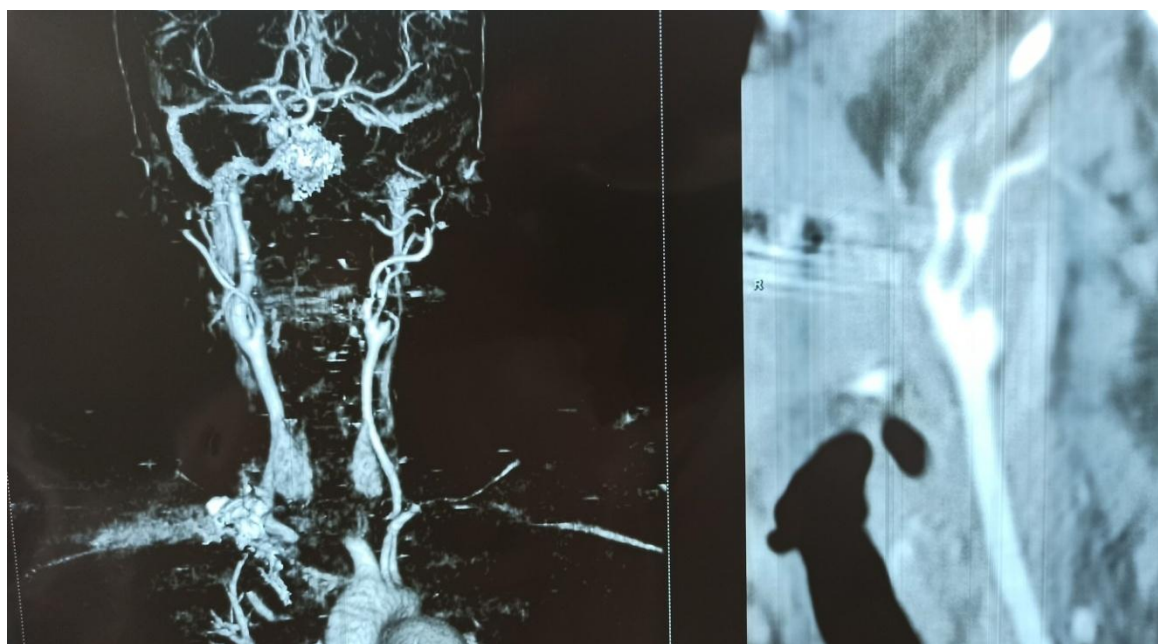


Fig. 5. CT angiography of the supra-aortic trunks

3. DISCUSSION

The management of patients with PFO-related stroke is complex. The choice of a treatment is based on the following criteria: the anatomical characteristics of the severity of the PFO, a high risk of stroke recurrence on the risk of paradoxical embolism score (RoPe) and an unfavorable benefit/risk ratio of the antithrombotic treatment [5,6]. Recent trials demonstrated that closure of high-risk PFO can reduce the risk of recurrent stroke compared to antithrombotic therapy [7].

Few data are available on the impact of thrombophilia in patients with cryptogenic stroke [8]. Current studies demonstrate an increased risk of cryptogenic stroke in patients with thrombophilia and PFO [9]. In our case, the deficiency in antithrombin 3 and in protein C constitutes a significant risk factor.

The origin of the patient's stroke remains doubtful. The first hypothesis is the increased risk of venous thrombosis with paradoxical embolism, in front of the association of FOP/ASIA with thrombophilia. Closing the PFO is then an optimal choice. In our case, the high pressures of the right cavities secondary to the massive left pulmonary embolism mean that closure of the PFO cannot be considered at this phase.

The second hypothesis is that her embolism was purely of arterial origin, given the total occlusion

of the left internal carotid artery that she presents, or that her neurological lesion was intracerebral. Closing the PFO would then provide no additional benefit.

Some studies recommend that antithrombotic treatment, despite PFO closure, should be considered on an individual basis [8]. There is a significant reduction in stroke recurrence in patients on anticoagulants compared to antiplatelets [10]. The American Heart Association recommends anticoagulant therapy for high-risk patients with coexisting venous thrombosis [11].

4. CONCLUSION

For patients with thrombophilia, with an indication for anticoagulation, closure of the PFO seems reasonable but prolonged antithrombotic treatment remains a subject of debate.

CONSENT

As per international standard or university standard, patients' written consent has been collected and preserved by the author(s).

ETHICAL APPROVAL

As per international standard or university standard written ethical approval has been collected and preserved by the author(s).

COMPETING INTERESTS

Authors have declared that no competing interests exist.

REFERENCES

1. Hara H, Virmani R, Ladich E, Mackey-Bojack S, Titus J, Reisman M, Gray W. et al. Patent foramen ovale: current pathology, pathophysiology, and clinical status. *J. Am. Coll. Cardiol.* 2005;46(9):1768–1776.
DOI: 10.1016/j.jacc.2005.08.038
2. Wu LA, Malouf JF, Dearani JA, Hagler DJ, Reeder GS, Petty GW, Khandheria BK. Patent foramen ovale in cryptogenic stroke: current understanding and management options. *Arch Intern Med.* 2004;164(9):950–956.
DOI: 10.1001/archinte.164.9.950
3. Kerut EK, Norfleet WT, Plotnick GD, Giles TD. Patent foramen ovale: a review of associated conditions and the impact of physiological size. *J Am Coll Cardiol.* 2001;38(3):613–623.
DOI: 10.1016/S0735-1097(01)01427-9.
4. Roy S, Le H, Balogun A, Caskey E, Tessitore T, Kota R, Hejirika J, Yu S, Nguyen L, Lazo AL, Yard C. Risk of Stroke in Patients With Patent Foramen Ovale Who Had Pulmonary Embolism. *Journal of Clinical Medicine Research.* 2020;12(3):190.
5. Hart RG, Diener HC, Coutts SB, Easton JD, Granger CB, O'Donnell MJ, et al; Cryptogenic Stroke/ESUS International Working Group. Embolic strokes of undetermined source: the case for a new clinical construct. *Lancet Neurol.* 2014;13(4):429-38.
6. Abdelghani M, El-Shedoudy SAO, Nassif M, Bouma BJ, de Winter RJ. Management of Patients with Patent Foramen Ovale and Cryptogenic Stroke: An Update. *Cardiology.* 2019;143(1):62-72.
7. Garg A, Thawabi M, Rout A, Sossou C, Cohen M, Kostis JB. Recurrent Stroke Reduction with Patent Foramen Ovale Closure versus Medical Therapy Based on Patent Foramen Ovale Characteristics: A Meta-Analysis of Randomized Controlled Trials. *Cardiology.* 2019;144(1-2):40-49.
8. Hviid CVB, Simonsen CZ, Hvas AM. Recurrence Risk in Patients with Cryptogenic Stroke, Patent Foramen Ovale, and Thrombophilia: A Systematic Review and Meta-Analysis. *Thromb Haemost.* 2019;119(11):1839-1848.
9. Gerstein NS, Clegg SD, Levin DB, Fish AC, Tolstrup K, Nakanishi K, et al. A Case-Based Discussion on the Management of Cryptogenic Stroke and Patent Foramen Ovale in the Patient With a Hypercoagulable Disorder. *J Cardiothorac Vasc Anesth.* 2019;33(12):3476-3485.
10. Sagris D, Georgiopoulos G, Perlepe K, Pateras K, Korompoki E, Makaritsis K, et al. Antithrombotic Treatment in Cryptogenic Stroke Patients With Patent Foramen Ovale: Systematic Review and Meta-Analysis. *Stroke.* 2019;50(11):3135-3140.
11. Kernan WN, Ovbiagele B, Black HR, et al. Guidelines for the prevention of stroke in patients with stroke and transient ischemic attack. A guideline for healthcare professionals from the American Heart Association/American Stroke Association. *Stroke.* 2014;45:2160–236.

© 2022 Bennani et al.; This is an Open Access article distributed under the terms of the Creative Commons Attribution License (<http://creativecommons.org/licenses/by/4.0>), which permits unrestricted use, distribution, and reproduction in any medium, provided the original work is properly cited.

Peer-review history:

The peer review history for this paper can be accessed here:

<https://www.sdiarticle5.com/review-history/92138>