

Outcome of Distal Fitting Revision Hemiarthroplasty in Failed Osteosyntheses of Trochanteric Fractures in Elderly – A Cross Sectional Retrospective Study

S. Ram Sudhan ^{a*#}, Rajkumar Vijayakumar ^{b≡}, Dheepan Kumar ^{c≡},
Viswanathan Muthiah ^{d^o} and Aravind Venkatasamy Ayothi ^{e†}

^a Department of Orthopaedics, Sunrise Hospital Changaramukulam, Kerala, 679575, India.

^b Department of Orthopaedics, Govt' Medical College & Hospital, Omandurar Govt' Estate, Chennai, 600002, India.

^c Department of Orthopaedics, Velammal Medical College Hospital, Madurai, 625009, India.

^d Department of Orthopaedics, Multicare Hospital, Karaikudi, 630002, India.

^e Department of Orthopaedics, Sri Venateshwara Medical College Hospital, Ariyur, Puducherry, 605107, India.

Authors' contributions

This work was carried out in collaboration among all authors. All authors read and approved the final manuscript.

Article Information

Open Peer Review History:

This journal follows the Advanced Open Peer Review policy. Identity of the Reviewers, Editor(s) and additional Reviewers, peer review comments, different versions of the manuscript, comments of the editors, etc are available here: <https://www.sdiarticle5.com/review-history/82651>

Original Research Article

Received 20 November 2021

Accepted 25 January 2022

Published 28 January 2022

ABSTRACT

Background: Treating failed internal fixation of intertrochanteric fractures are challenging due to patient factors and surgical hurdles which may include internal fixation or salvage arthroplasty (HA or THA). In our study we analysed the clinical and radiographic outcomes of 12 elderly failed osteosynthesis patients who were operated with a modular, uncemented long stem distal fitting prosthesis as a salvage procedure.

Methods: We did a cross sectional, retrospective, analytical study of patients who attended Orthopaedic outpatient department of Sunrise Hospital, Kerala, India between 2018 to 2020. We included only failed osteosyntheses patients with intertrochanteric fractures. The outcome was analysed by taking into account the increasing defects, bone remodelling in proximal femur &

Junior Consultant;

≡ Asst' Professor;

^o Consultant;

† Senior Resident

*Corresponding author: Email: sudhansubramaniam@gmail.com;

union, subsidence and stem fixation to bone in radiographs taken immediately postsurgery and comparing it on successive reviews.

Results: The mean age of the study participants and mean operation age of the index operation was 75 (12) and 74 years (range 62–87) respectively. The commonly encountered failure modes, following index surgery, were cut-out (n = 5), and femoral neck screw migration (n =4). We observed union among 10 cases, while restoration of proximal bone defects in 6, bony ingrowths in 7 and subsidence in 2 stems. Two patients were revised during the follow up period due to recurrent dislocation.

Conclusion: The prosthesis used was advantageous as it allows fixation distal to the fracture system aiding restoration of proximal bone and soft tissue complex. Radiographic outcomes were satisfactory with minimal complications. Thus, the use of distal fitting modular bipolar prosthesis might prove to be effective in improving the morbidity and mortality in the elderly by assuring early weight bearing in failed fixation of intertrochantric fractures.

Keywords: Failed osteosyntheses; proximal femoral nailing; revision hemiarthroplasty; intertrochantric fractures; distal fitting stem.

1. INTRODUCTION

Fractures of the hip joint are one among the commonest injuries encountered by the elderly i.e., in patients over 60 years of age. Intertrochanteric (IT) fractures are frequently encountered in clinical settings, which usually amount to almost half of the hip fractures cases occurring worldwide, thereby hindering the reconstructive and rehabilitative services provided [1,2]. Treatment options available for IT fractures especially among the elderly are limited and challenging, as internal fixation becomes difficult and result in greater chances of failure [3,4]. Despite these, most treatment options for IT fractures are associated with a 0.5 to 56% failure rate, majorly depending on the type of fracture, the condition of the patient, and the extent of reduction and fixation [5]. In addition, patients who experience failed treatment have many complications such as pain, prolonged recumbency related issues thereby causing major disability to them [6]. The major indications for reoperation/ revision surgery are non-union, malunion, implant failures, avascular necrosis of head of femur and post traumatic arthritis [7]. There are frequent occurrences of failed treatment of hip fractures which usually leads to severe functional disability, pain and poor quality of life thereby affecting the individual's activities of daily living. Other than nonoperative treatment, which is done among certain group of patients, commonly encountered treatment options for patients who have an intertrochanteric hip fracture that has failed following previous index surgery are internal fixation of the nonunited fracture or salvage treatment with a hip arthroplasty. The hip arthroplasty can be Total Hip Arthroplasty or Hemiarthroplasty (HA).

Nevertheless, bipolar hemiarthroplasty (HA) is now an upcoming option for treating these fractures [8,9]. Recently, Salvage osteosynthesis and distal fitting hemiarthroplasty have emerged as mainstay treatment for the failed internal fixation of IT fractures [10]. These procedures are further complicated by several reasons including residual bone deformity, breakage of implants, and distorted soft tissue anatomy etc. which are often linked with excessive perioperative morbidity, increased duration of surgeries, increased blood loss and early dislocation [7]. Thus, we undertook this review, the outcome of Distal Fitting Revision Hemiarthroplasty in Failed Osteosyntheses among elderly patients with either Proximal Femoral Nailing/dynamic hip screw/ LCP.

2. PATIENTS AND METHODS

This was a cross sectional, retrospective, analytical study done among the elderly patients who underwent Distal Fitting Revision Hemiarthroplasty surgery in cases of failed osteosyntheses who were initially operated with Proximal Femoral Nailing/ DHS/ LCP. The study was done among the elderly patients who attended the orthopaedic outpatient department (OPD) of the Sunrise Hospital in Ernakulam, Kerala, India between 2018 to 2020. The patients were recruited consecutively. We had employed an inclusion criterion of patients >60 years of age with failed osteosyntheses and who underwent Distal Fitting Revision Hemiarthroplasty for the same following either Proximal Femoral Nailing/DHS/LCP for intertrochanteric fractures. We finally identified around 21 patients who fulfilled the inclusion criteria and who were

operated with distal fitting long stem bipolar prosthesis. The stem which was utilised among the patients mainly acted as a primary THA in a salvage procedure after failed internal fixation of intertrochanteric fractures. The basic details, clinical history and radiographs were collected and examined from all the patients. We excluded around 9 patients, out which 3 patients had a radiographic follow-up of less than 6 months and 6 patients with pathological fractures. Thus, we finally arrived at our final sample size of around 12 patients who underwent revision hemiarthroplasty using distal fitting modular bipolar prosthesis. The long revision stem (bipolar) prosthesis we used consists of a proximal modular neck segment and a distal CoCr corundum blasted stem for cementless fixation. The stem geometry has 5 longitudinal ridges, intended to engage the femoral cortex distal to the fracture system, thus enhancing bony apposition & optimum rotational stability. The prosthesis is impacted and fixed rigidly to maintain the axial and torsional stability with the femoral canal. Various stem lengths and

diameters allow independent and individualised fitting on the diaphysis.

3. OUTCOME MEASUREMENTS

We used the Jensen- Michaelsen classification to address the Trochanteric hip fractures [11]. Furthermore, they were then further classified using the AO/OTA classification (widely used and accepted) as type 31-A and type 32-A as shown in table 1(which were further subdivided into A1–B3) [12]. The radiographs were compared between the ones obtained right after the prosthesis placement with films taken during review follow-up at 6months, 12 months, 18 months and on successive years. The parameters studied were bone defects, union & bone remodelling in proximal femur, subsidence/ stem migration and stem fixation to bone. We classified bone remodelling in proximal femur as increasing defects, no change, or osseous restoration [13]. We used Engh et al criteria to classify the uncemented stem as “bony in growth”, “Stable fibrous”, or “unstable”.

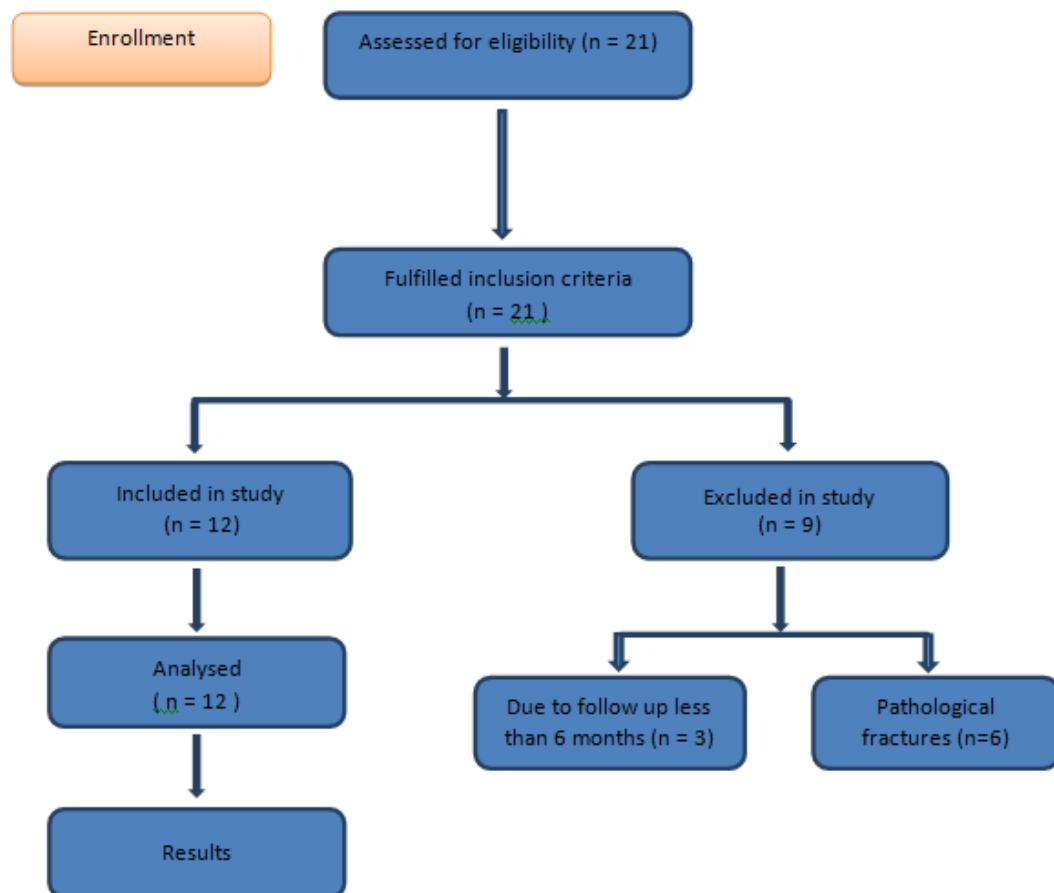


Fig. 1. CONSORT flow diagram showing flow of patients through the study

Table 1. Distribution of subjects based on classification

Fracture classification (Evan's with Jensen-Michaelsen modification)	
TYPES	RESPECTIVE NUMBER OF SUBJECTS
1 / 2 / 3 / 4 / 5	1 / 1 / 2 / 2 / 6
AO/OTA	
31, A1.1 / A1.2 / A1.3	2 / 0 / 0
31, A2.1 / A2.2 / A2.3	1 / 0 / 1
31, A3.1 / A3.2 / A3.3	1 / 0 / 1
32, A1.1 / A2.1 / A3.1	1 / 0 / 0
32, B1.1 / B2.1 / B3.1	2 / 2 / 1

The distance between fixed points on distal fitting long revision stem prosthesis and any reproducible mark on femur was used to calculate vertical femoral migration. The lesser trochanter, greater trochanter tip, screw holes, or trochanteric wires were the commonly used fixed points [14]. Any migration of more than 5 mm of the femur over the prosthesis distally was considered as subsidence [15]. Booker et al classification was used to grade the heterotopic ossification [16]. An independent senior radiologist who is not a part of the author panel was employed to assess the radiographs digitally using the Sectra PACS software IDS5 (Sectra-Imtec AB, Linköping, Sweden).

3.1 Statistical Analysis

The data was collected using a structured proforma from the clinical records and were entered into Microsoft excel. The analysis was performed using SPSS 21.0. The continuous variables were reported as mean (sd) or median (iqr) based on normality. Categorical variables were summarised as frequency and proportions. "Reoperation" was defined to include all types of

new surgical procedures following the main operation in the same hip. "Revision" was used when one or more components or the entire prosthesis were removed or exchanged. A p value of <0.05 was considered statistically significant.

4. RESULTS

Table 2 & Table 3 describes the characteristics of the study participants. We finally included 12 patients for our analysis. Most of the patients were operated either with an intramedullary nail (n = 8) or by a sliding hip screw device (n = 3) or LCP (n = 1). The common modes of failure encountered were dominated by cut-out (n = 5) followed by femoral neck screw migration (n = 4) as shown in table 3 (& Fig 2). We also observed that the average duration between the surgical operation and the follow up operation with the long revision stem prosthesis was 3.6 (SD 4.8) years Median 2 (IQR 1) years. We observed that around 7 patients had undergone minimum of one surgical procedure and around 5 underwent 2 or more operations before the salvage procedure (Table 4).

Table 2. Demographic characteristics of subjects in the study

Characteristics	AGE		SEX	
	61-75	>75	MALE	FEMALE
Frequency (%)	6(50)	6(50)	3(25)	9(75)

Table 3. Distribution of implant type on primary fixation and distribution of modes of failure

Type of implant during primary fixation		Modes of failure during primary fixation	
Intramedullary nail	8 (66.7)	Cut out	5 (41.6)
Sliding hip screw	3 (25)	Femoral neck screw migration	4 (33.3)
Others (LCP)	1 (8.3)	Implant breakage	2 (16.6)
		Disassembly	1(8.3)

Table 4. Distribution of frequency of surgeries before index operation

Frequency of operations before index operation	
One	7 (58.2)
More than one	5 (41.8)

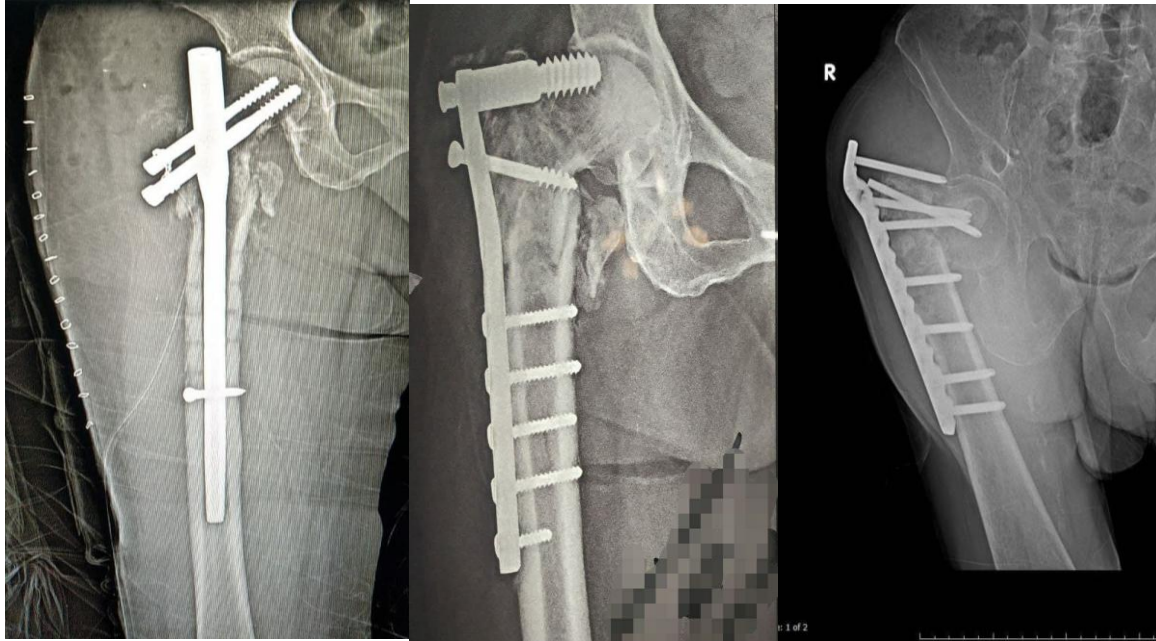


Fig. 2. Common modes of failure by conventional methods

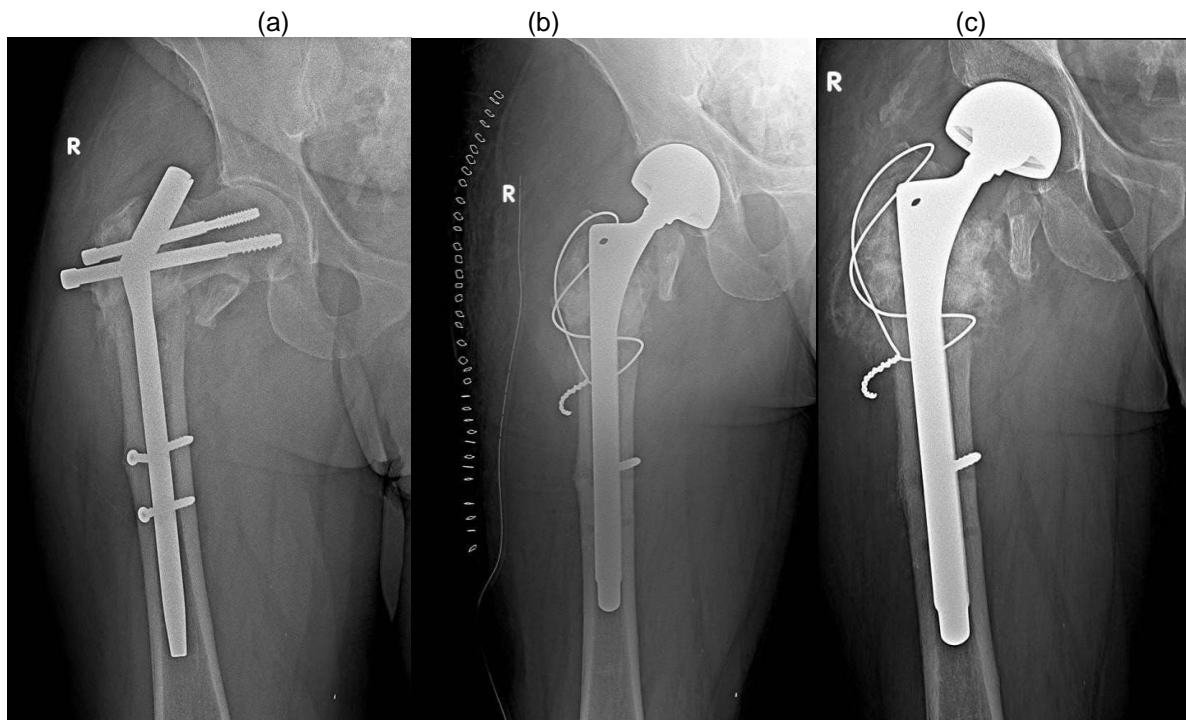


Fig. 3. a) radiograph of failed osteosyntheses following PFN, b) immediate post op radiograph after bipolar hemiarthroplasty using distal fitting stem and c) follow up radiograph after 18months

The mean age of the patients during their first operation with distal fitting long revision stem prosthesis was found to be 74 years (range 62–87) years. The patients recruited had a followup duration of 4 years (range 1-4 years). Around 8 were operated with a posterior approach and 4 were operated with a lateral approach. Cerclage wires were used in 7 patients.

The radiographs taken soon after the trauma, showed that around 8 of 12 trochanteric fractures were unstable (shown in Table 1). During the follow up, after long revision stem prosthesis placement, we found that radiological union was observed in 10 of the 12 cases. We observed restoration of proximal bone defects in around 6 patients, bony ingrowths in 7 patients and subsidence in 2 stems (Table 5). We also observed that around seven patients had varying degrees of heterotopic ossifications during the follow up period, while two had increased degrees of ossifications when compared to radiographs taken just after the index operation.

4.1 Revisions and Complications

Two patients were revised during the follow up period due to recurrent dislocation, by exchange of prosthesis. Closed reduction due to dislocation done in one subject.

5. DISCUSSION

In our study we evaluated 12 patients who were operated by a salvage procedure with a Distal Fitting Revision Hemiarthroplasty, following failed hip fracture fixations. Our study showed that commonly observed outcome was fracture union, bony ingrowths, proximal bone restoration while only two patients had subsidence. Reoperation was needed for only two patients. To the best of our knowledge, only a few literature articles are available, that provides evidence regarding this intervention with varying results. The failure rate reported for this prosthesis varies between 4% and 17% that too commonly in patients with pre-existing osteoporosis [17,18]. Several studies have also established age could be associated with high failure rates as experienced in our study, where the mean age of index operation before prosthesis was 74 years [16]. Hemiarthroplasty has been proven to show dramatic relief of pain and improved function in

many studies, especially for whom it is undertaken as a salvage procedure to overcome failed osteosynthesis. Despite the technical difficulties associated with the procedure, low complication rate, durable prosthesis and favourable survival made this procedure reliable. Our study showed comparable survival results and outcome profile when compared to previous studies from outside India [19,20]. Our study also showed high cut out rates when compared to previous studies from western literature, which could be explained by variation in clinical settings, rate of follow up and available services [21,22].

Usually, the decision whether to perform a hemiarthroplasty (HA) or Total Hip Arthroplasty (THA) solely depends on extent of acetabular cartilage anatomy and the functional demand of patients. THA always remained a better salvage procedure for 'cut-out' and 'cut-through' after fixation of IT fractures. But recent literature shows that a metanalysis (14 article) which included six studies with 188 patients (100 THA and 88 HA) to compare the long-term benefits of THA and HA showed that there was no significant difference between both with respect to postoperative dislocations, reoperations, infections, intraoperative or postoperative fractures, and stem subsidence. This evidence underscores the importance of HA in patients with failed osteosynthesis as a salvage procedure. Furthermore, Harris Hip Scores were observed to be higher among THA operated patients than HA during their 14-month follow-up [23].

In general, THA is often used in patients with poor bone quality, signs evident of osteoarthritis and among elderly. Evidence have documented varying results in the use of conventional hip stems as a salvage procedure [21,24]. THA usually fails to offer the use of conventional femoral components for various reasons in this setup. Thus, to overcome the same, uncemented modular revision implants are used. Our Distal fitting Long revision stem prosthesis is one among those procedures, which allows separate preparation of the proximal and distal femoral shaft to maximise prosthesis fill, provides more adjustment length, individual adjustment of offsets, and anteversion, thus enabling stability and fixation in more distal femoral bone.

Table 5. Radiological characteristics of the study participants (N=12)

Characteristics	Frequency (%)	Characteristics	Frequency (%)
Union of fracture		Subsidence, migration (>5 mm)	
Yes	10 (83.3)	Yes	2 (16.7)
No	2 (16.7)	No	10 (83.3)
Proximal bone defects		Stem fixation	
Restoration	6(50)	Bony ingrowth	7 (58.3)
No change	4 (33.3)	Stable fibrous	3(25)
Increasing	2 (16.7)	Unstable	1 (8.3)
Distal stem migration (mm)		Not possible to identify	1(8.3)
Trochanteric	2 (3)		

Our radiographic results are in line with other studies which has utilised and seen the effectiveness of modular implants [6,25]. A more laborious screening methodology involving careful examination of these patients, with special focus to ruleout & prevent postoperative infection is recommended for future follow up studies.

Our study had certain strengths, to the best of our knowledge this was one among the very few studies that explored the effect of Distal Fitting Revision Hemiarthroplasty in Failed Osteosyntheses with either Proximal Femoral Nailing/DHS/LCP in Elderly. We included only patients with complete available records both preoperatively and postoperatively with good follow-up especially among the elderly population. Furthermore, we utilised standardised radiographical procedures to evaluate the fractures and used validated and accepted scoring systems for classifying the fractures. Despite the strengths our study had certain limitations, we could get only a limited sample size, from a single tertiary health centre, to demonstrate the effect, which was a major limitation. Thus, future studies are warranted using multicentric approach and larger sample size to establish the benefit of Distal Fitting Revision Hemiarthroplasty among the various salvage procedures available for failed osteosynthesis of intertrochanteric fractures of hip.

6. CONCLUSION

Since the chance of internal fixation failure on elderly are greater due to various innate reasons, and with high complication rates & surgical hurdles in reoperation, altogether make them challenging for both orthopaedic surgeons and patients, the alternative use of distal fitting long stem prosthesis might prove as better salvage alternative as the uncemented stem allows

fixation distally in the femur. Our results indicate that stable fixation of the implant can be achieved with a good radiographic outcome, thereby assuring early weight bearing and ambulation which are of cardinal importance in improving morbidity and mortality in the elderly.

CONSENT

All the eligible patients who attended the OPD for review were recruited in the study after detailed explanation with written and informed consent.

ETHICAL APPROVAL

The study was reviewed and approved by the Institutional Ethics Committee of Sunrise Hospital, Ernakulam, Kerala.

COMPETING INTERESTS

Authors have declared that no competing interests exist.

REFERENCES

1. Karampinas PK, Kollias G, Vlamis J, Papadelis EA, Pneumaticos SG. Salvage of failed hip osteosynthesis for fractures with modular hip prosthesis. *Eur J Orthop Surg Traumatol.* 2015; 25(6):1039–45. Available: <https://doi.org/10.1007/s00590-015-1622-5>.
2. Dziadosz D. Considerations with failed intertrochanteric and subtrochanteric femur fractures: how to treat, revise, and replace. *J Orthop Trauma.* 2015;29(Suppl 4):S17–21. Available: <https://doi.org/10.1097/BOT.000000000000289>.
3. Zhang B, Chiu KY, Wang M. Hip arthroplasty for failed internal fixation of

- intertrochanteric fractures. *J Arthroplasty*. 2004;19:329-33.
4. Hsu CJ, Chou WY, Chiou CP, Chang WN, Wong CY. Hemi-arthroplasty with supplemental fixation of greater trochanter to treat failed hip screws of femoral intertrochanteric fracture. *Arch Orthop Trauma Surg*. 2008;128:841-5.
 5. Bercik MJ, Miller AG, Muffly M, Parvizi J, Orozco F, Ong A. Conversion total hip arthroplasty: a reason not to use cephalomedullary nails. *J Arthroplast*. 2012;27(8 Suppl):117-21. Available:<https://doi.org/10.1016/j.arth.2012.04.009>.
 6. Thakur RR, Deshmukh AJ, Goyal A, Ranawat AS, Rasquinha VJ, Rodriguez JA. Management of failed trochanteric fracture fixation with cementless modular hip arthroplasty using a distally fixing stem. *J Arthroplast*. 2011; 26(3):398-403. Available:<https://doi.org/10.1016/j.arth.2010.01.103>.
 7. Muller F, Galler M, Zellner M, Bauml C, Fuchtmeier B. Total hip arthroplasty after failed osteosynthesis of proximal femoral fractures: revision and mortality of 80 patients. *J Orthop Surg*. 2017;25(2): 2309499017717869. Available:<https://doi.org/10.1177/2309499017717869>.
 8. Celiktas M, Togrul E, Kose O. Calcar preservation arthroplasty for unstable intertrochanteric femoral fractures in elderly. *Clin Orthop Surg*. 2015;7:436-42.
 9. Kayali C, Agus H, Ozluk S, Sanli C. Treatment for unstable intertrochanteric fractures in elderly patients: internal fixation versus cone hemiarthroplasty. *J Orthop Surg (Hong Kong)*. 2006;14: 240-4.
 10. Smith A, Denehy K, Ong KL, Lau E, Hagan D, Malkani A. Total hip arthroplasty following failed intertrochanteric hip fracture fixation treated with a cephalomedullary nail. *Bone Joint J*. 2019; 101-B(6_Supple_B):91-6. Available:<https://doi.org/10.1302/0301-620X.101B6.BJJ-2018-1375.R1>.
 11. Jensen J S. Classification of trochanteric fractures. *Acta Orthop Scand* 1980; 51: 803-10.
 12. OTA: Orthopaedic Trauma Association Committee for Coding and Classification. Fracture and Dislocation Compendium. *J Orthop Trauma*. 1996;10(Suppl 1):31-5.
 13. Bohm P, Bischel O. Femoral revision with the Wagner SL revision stem: Evaluation of one hundred and twenty-nine revisions followed for a mean of 4.8 years. *J Bone Joint Surg (Am)*. 2001;83:1023-31.
 14. Engh CA, Glassman AH, Suthers KE. The case for porous-coated hip implants. The femoral side. *Clin Orthop*. 1990;261:63-81.
 15. Sporer SM, Paprosky WG. Femoral fixation in the face of considerable bone loss: the use of modular stems. *Clin Orthop* 2004;429:227-31
 16. Brooker AF, Bowerman JW, Robinson RA, Riley LH, Jr. Ectopic ossification following total hip replacement. Incidence and a method of classification. *J Bone Joint Surg (Am)*. 1973;55:1629-32.
 17. Koval KJ, Aharonoff GB, Rosenberg AD, Bernstein RL, Zuckerman JD. Functional outcome after hip fracture.Effect of general versus regional anesthesia. *Clin Orthop Relat Res*. 1998;(348):37-41.
 18. Meijerink HJ, Gardeniers JW, Buma P, Lemmens JA, Schreurs BW. Hydroxyapatite does not improve the outcome of a bipolar hemiarthroplasty. *Clin Orthop Relat Res*. 2004;421:143-50.
 19. Chirodian N, Arch B, Parker MJ. Sliding hip screw fixation of trochanteric hip fractures: outcome of 1024 procedures. *Injury*. 2005;36:793-800.
 20. Jones HW, Johnston P, Parker M. Are short femoral nails superior to the sliding hip screw? A meta-analysis of 24 studies involving 3,279 fractures. *Int Orthop* 2006; 30:69-78.
 21. Haidukewych GJ, Berry DJ. Hip arthroplasty for salvage of failed treatment of intertrochanteric hip fractures. *J Bone Joint Surg (Am)*. 2003;5:899-904.
 22. Simpson AH, Varty K, Dodd C A. Sliding hip screws: modes of failure. *Injury*. 1989; 20:227-31.
 23. Luthringer TA, Elbuluk AM, Behery OA, Cizmic Z, Deshmukh AJ. Salvage of failed internal fixation of intertrochanteric hip fractures: clinical and functional outcomes of total hip arthroplasty versus hemiarthroplasty. *Arthroplasty Today*. 2018;4(3):383-91. Available:<https://doi.org/10.1016/j.artd.2018.06.002>
 24. Mehlhoff T, Landon G C, Tullos H S. Total hip arthroplasty following failed internal fixation of hip fractures. *Clin Orthop* 1991;269:32-7.

25. Laffosse JM, Molinier F, Tricoire JL, Bonneville N, Chiron P, Puget J. Cementless modular hip arthroplasty as a salvage operation for failed internal fixation of trochanteric fractures in elderly patients. Acta Orthop Belg. 2007;73(6):729–36.

© 2022 Sudhan et al.; This is an Open Access article distributed under the terms of the Creative Commons Attribution License (<http://creativecommons.org/licenses/by/4.0>), which permits unrestricted use, distribution, and reproduction in any medium, provided the original work is properly cited.

Peer-review history:
The peer review history for this paper can be accessed here:
<https://www.sdiarticle5.com/review-history/82651>