



## **Evaluation of the Sub Acute Toxicity of the Stem Bark of *Andira inermis***

**Maxwell Osaronowen Egua<sup>1\*</sup>, Florence Chimezie Nwinyi<sup>2</sup>,  
Ode Julius Okwoche<sup>2</sup>, Onakpa Micheal Monday<sup>2</sup>, Akande Motunrayo Ganiyat<sup>2</sup>,  
Samson Eneajo Abalaka<sup>3</sup>, Mikail Hudu Garba<sup>2</sup>, Akumka David Dezi<sup>2</sup>  
and Adamu Mohammed<sup>2</sup>**

<sup>1</sup>Department of Pharmacology and Therapeutics, College of Health Sciences, University of Abuja, Nigeria.

<sup>2</sup>Department of Pharmacology and Toxicology, Faculty of Veterinary Medicine, University of Abuja, Nigeria.

<sup>3</sup>Department of Pathology, Faculty of Veterinary Medicine, University of Abuja, Nigeria.

### **Authors' contributions**

The research was carried out in collaborations of all the authors. All authors read and approved the final manuscript.

### **Article Information**

DOI: 10.9734/EJMP/2021/v32i130368

#### Editor(s):

- (1) Dr. Paola Angelini, University of Perugia, Italy.  
(2) Prof. Marcello Iriti, Milan State University, Italy.

#### Reviewers:

- (1) Venkatesan Sundaram, The University of the West Indies, Trinidad and Tobago.  
(2) Luís Felipe Espíndola-Castro, Universidade de Pernambuco, Brazil.

Complete Peer review History: <http://www.sdiarticle4.com/review-history/65577>

**Original Research Article**

**Received 14 December 2020**  
**Accepted 17 February 2021**  
**Published 12 March 2021**

### **ABSTRACT**

The aqueous methanolic *Andira inermis* stem bark extract was screened in evaluation of its potential for its toxic effect in a 28 days study using the oral route only. The sub acute study was carried out in Wistar rats divided into 4 groups of 5 rats each; control group (a) received distilled water while the aqueous methanolic *Andira inermis* stem bark extract treatment groups (b), (c), and (d), received 100, 200, and 400 mg/kg of the extract respectively, for a period of 28 days, with their intake of feeds, water and signs of abnormality observed. At the end of the sub acute study, the rats were anaesthetized with chloroform and blood collected by cardiac puncture for biochemical and haematological evaluation. And the visceral organs (liver, kidneys, lungs, heart and spleen) excised for weighing and patho-morphological examination. The aqueous methanolic *Andira inermis* stem bark extract was found to; reduce the intake of water weekly, drop intake of feeds;

\*Corresponding author: E-mail: [egua.osaronowen@uniabuja.edu.ng](mailto:egua.osaronowen@uniabuja.edu.ng);

significantly increased the red blood cell count (RBC), the haemoglobin concentration (HB), as well as the pack cell volume (PCV). The renal indices, showed the electrolytes sodium and chloride of the treatment groups (b, c and d) to be significantly different from the control. Urea was noticed to have reduce significantly and creatinine insignificantly. The organs weights across the *Andira inermis* treatment groups were noticed to be insignificantly ( $P > 0.05$ ) different from the control for all the organs sampled (Lungs, Liver, Heart and Spleen) except for the kidney (organ weight which was noticed to have increased significantly). The patho-morphologies of the organs showed the heart to be normal, the kidney was normal in the control and the other treatment groups 100 mg 400 mg and 200 mg but a rat (an outlier) in one of the 200 mg group was noticed with tubular necrosis; the liver indicated a non concentration-dependent hepatitis while the lungs and the spleen presented an infective process. It was concluded that, the aqueous methanolic extract of *Andira inermis* is a safe medicinal plant with the capacity to; raise red blood cell count (RBC), haemoglobin concentration (HB) as well as the pack cell volume (PCV); proffers a nepro- protective property; shrunken spleen; have a hepato-protective property and as well was non toxic to the heart and lungs. These findings warrants further pharmacognostic efficacy experimental research to harness the array of benefits of *Andira inermis* as discovered in this study.

**Keywords:** Sub-acute; extract; *Andira inermis*; biochemical; heamatological and patho-morphological.

## 1. INTRODUCTION

It is common to see several herbal products on sale openly in public places, like markets, bus stops/ parks, travelling vehicles and even on the streets, of developing countries- a sign of their acceptance. Most of such herbal products are yet to undergo scientific scrutiny or toxicity evaluations. Also, some of these commercial herbal products have efficacy and safety study reported [1]. Pharmacological and toxicological evaluations of medicinal plants are essential for drug discovery, and there lay in nature's bank a lot of uncovered chemicals useful for the treatment of numerous diseases that inflict man [2]. It is common practice to screen herbs and indeed medicinal materials (whether animals or plant) for the possibility of toxicity being that some traditional medicines/formula contain toxic and potentially lethal constituents: *Ricinus communis* (Phytotoxicans – Toxalbumins); *Hedera helix* and *Digitalis purpurea* (glycosides); *Dieffenbachia spp* [oxalates] [3]. There have been reports of herbal medicines toxicity worldwide; examples are Garlic(*Allium sativum*), mostly associated with normal exposures resulting in dermatitis or eczema, a few cases of bleeding complications secondary to high dietary garlic; Ginseng (*Panax ginseng*) known for "Ginseng abuse syndrome" is associated with apparent aggressive behavioral changes/hypertension in over users [4]; Ephedra (*Ephedra Sinica*;) known for the "Sympathomimetic syndrome" tachycardia, hypertension agitation, altered mental status, heart failure, rhabdomyolysis, eosinophilia-myalgia syndrome, acute hepatitis,

hypersensitivity myocarditis, myocardial infarction, psychosis, seizure, stroke and death and St. John's Wort (*Hypericum perforatum*) is associated with phototoxicity serotonin syndrome [4].

Apart from reports and awareness of the toxicity of herbal products, acute toxicity study is one of the appropriate/ designated pharmacognostic studies in the evaluation of plant herbal products undergoing medicinal scientific scrutiny. In this light, following an earlier acute toxicity study [5] of *Andira inermis* (AI) stem bark (reported to be 5000 mg/kg), this study is designed to evaluate the toxicity (subacute) of the aqueous methanolic *Andira inermis* stem bark extract in adult Wister rats with an aim to provide more information for future research on the efficacy study on the stem bark. The pharmacognostic medicinal property /purpose for which the plant *Andira inermis* is being studied is its antihyperglycaemic effect [5] which warrants daily usage /dosages hence the subacute toxicity evaluation presently embarked on. Also, usage of herbal medicinal plants without evaluating the safety profile may result in species organ damage, commonly the kidney and the liver which are organs involved in the metabolism and excretion of compounds ingested [6]. Other organs/systems may be affected depending on whether the extract has a direct toxic effect on them (such as lungs, heart, and spleen).

*Andira inermis* (AI) is a tall evergreen tree with a luxuriant, spreading canopy of large, glossy, rich green leaves and attractively scented small flowers [7], bark fissured and scaly, with an

unpleasant cabbage-like smell. The trunk frequently forms buttresses up to 3 metres tall. The leaves alternate, imparipinnate, 15-40 cm long, with 7-17 leaflets, bright tan when young and shiny green when mature [8]. A decoction of the leaves is used as a beverage (leaf decoction also used for washing in Africa), the fruits are eaten, the bark is used as a vermifuge, an antihelmintic, narcotic and purgative [7], the inner bark is used to treat snake bites [7] and the seeds have purgative and narcotic properties [8] and are also toxic [7].

## 2. MATERIALS AND METHODS

### 2.1 Plant Collection and Preparation

*Andira inermis* stem bark was collected from Suleja, Niger State in December 2017. It was identified and deposited in the herbarium (with a herbarium number NIPRD.H.7073) of the National Institute for Pharmaceutical Research and Development (NIPRD) Abuja, Nigeria, by a plant taxonomist with the ethnobotany and herbarium section of the institution.

The *Andira inermis* stem bark was air-dried and pulverized; two kilograms (2 kg) of the powder was collected, double macerated and extracted with 5 litres of 80% methanol following agitation on a shaker for 24 hours. The 80% methanol extract was then concentrated in a rotary evaporator and air-dried for use in the subacute toxicity.

### 2.2 Animals

Albino Wistar Rats of both sexes were obtained from National Institute for Pharmaceutical Research and Development (NIPRD) and used for the study. The rats were housed in metal cages in the experimental house of the Faculty of Veterinary Medicine, University of Abuja, Nigeria. They were maintained at room temperature (37°C); 12 h/12 h light/dark cycle, and allowed free access to standard rat feeds and water. They were left to acclimatize for 2 weeks before the commencement of the experiment. Twelve hours before the commencement of the experiment, the feed was withdrawn but the water was made available *ad libitum*.

### 2.3 Instrument, Consumables and Reagents

Analytical grade chemicals, freshly prepared solutions and standard drugs were used for the

experiments. Methanol was obtained from Riedel-deHaen, Germany; tetraoxosulphate (VI) acid, Giemsa stain (Sigma, St. Louis, Missouri, USA), and 10% formal saline. Chloroform was obtained from Sigma Aldrich, USA, and used in the experiments. Analytical weighing balance (Mettler), Top-loading Balance (Ohaus scale), Table Centrifuge (Heraeus Christ), Rotary Evaporator (Buchi, USA), and Distilled water.

### 2.4 Sub-Acute Toxicity

Thirty-two (32) rats were randomly selected and divided into four groups labeled A to D. The initial weights of the rats were recorded. The animals in group A were administered distilled water to serve as a control, while those in Groups B, C and D received 100, 200, and 400 mg/kg respectively, of the aqueous methanolic *Andira inermis* stem bark extract daily. The administration of the extract was oral, by feeding tube for 28 days. The male rats were separated from the female rats within the groups. The feed and water consumption of the animals were observed daily. The Organization for Economic Co-operation and Development (OECD) Guideline 407 for the sub-acute oral toxicity test [9] was followed with moderate modifications.

Twelve hours (12 hrs) to the commencement of the experiment, all the rats (all groups) were fasted but allowed free access to water. On the last day of the experiment (29th day), blood samples were collected through cardiac puncture following chloroform anaesthesia. Blood samples for biochemical analysis were collected in non-heparinized bottles and that for hematological studies in EDTA bottles. The lungs, liver, heart, spleen and kidney were collected, weighed, and stored in 10% formalin, for histopathological study. The experimental procedure adopted standard methods [9,10,11].

### 2.5 Haematological Studies

The blood sample in EDTA bottles was evaluated for hematological parameters such as the red blood cell count (RBC), hemoglobin concentration (Hb), packed cell volume (PCV), mean corpuscular volume (MCV), mean corpuscular hemoglobin (MCH), mean corpuscular hemoglobin concentration (MCHC) and white blood cell count (WBC), determined using a MeCan three Parts differential Haematology auto-analyzer (MCL-3800 MeCan Medical China).

## 2.6 Biochemical Studies

The blood samples collected were centrifuged, using centrifuge model 8000D, for 5 minutes and the sera were collected in plain test tubes and stored in the deep freezer at  $-17^{\circ}\text{C}$  until required for the following analysis.

### 2.6.1 Assessment of renal function

i. Urea determination (Randox kit, Urease – Bertholot method) ii. Creatinine determination [12] iii. Determination of Sodium and Potassium (flame photometry method) iv. Biocarbonate determination (Slyke titration method)

### 2.6.2 Assessment of liver function

The two following parameters were assessed to determine the functions or damage to the liver; i. Alanine amino Transferase (ALT) (The Randox kit) ii. Aspartate amino Transferase (AST) (Randox kit).

## 2.7 Gross and Histopathological Studies

The animals were sacrificed after general anesthesia, with chloroform, a day after the last dose of the drug administration. At necropsy, the lungs, liver, heart, spleen, and kidney of each rat were removed, grossly examined, and weighed. The tissue samples were then fixed in formalin for histopathological examination. The tissues were fixed in formalin-acetic acid fixative, embedded in paraffin wax, sectioned, and stained with Haematoxylin and Eosin for histological examination.

## 2.8 Statistical Analysis

The SPSS statistical software (version 2.0) was employed for the analysis. Results were expressed as Mean  $\pm$  SEM. Data were analyzed using one-way analysis of variance (ANOVA) while the Tukey test was used for the post hoc analyses. The significance level was set at  $p \leq 0.05$ .

## 3. RESULTS

### 3.1 Adverse Effects and Mortality of the Crude Extract

There were no mortalities recorded over the 28 days experimental period. As well there were no overt clinical signs of toxicity, stress or changes

in appearance or behavioral changes observed in the rats amidst the groups.

### 3.2 Feed and Water Consumption of the Animals

As seen from Fig. 1 there was a drop in the intake of water weekly throughout the experiment. This was also realized to be statistically significant ( $P \leq 0.000$ ) in the ANOVA between groups. Also noticed is the treated groups consumed more volume of water throughout the experiment.

There was a slight drop in the feed intake of the rats treated with AI but the control was far much reduced at the end of the research Fig. 2. The reduction in feed intake was significant ( $P \leq 0.01$ ) only in the fourth (last) week of the experiment.

### 3.3 The Effect of AI on Hematological Indices of the Rats

The AI extract was seen to have significantly ( $P \leq 0.05$ ) improved/ increased the red blood cell count (RBC) in a dose-dependent manner. The extract also reflected a significant ( $P \leq 0.02$ ) increase in the haemoglobin concentration (HB) as well as the pack cell volume (PCV). This significance did not extend to the mean corpuscular volume (MCV), mean corpuscular haemoglobin (MCH) and mean corpuscular haemoglobin concentration (MCHC). The platelet was seen to double its number/concentration from the control to the AI treated groups, though not statistically significant Table 1.

The total WBC was seen to be statistically insignificant ( $P > 0.05$ ), as well as the differential WBC; neutrophil, lymphocytes, monocytes, eosinophil, and basophil Table 2.

### 3.4 The Effects of AI on the Kidney

The renal indices, showed the electrolytes sodium and chloride of the AI group to be significantly different from the control, with a P value of  $P \leq 0.01$  and  $P \leq 0.02$  respectively. The  $\text{Na}^+$  was seen to have been slightly raised in a dose-dependent manner from the control. And the  $\text{Cl}^-$  was seen to have reduced, though not dose-dependently from the control, the 200 mg/kg group (C) being the closest (to the control), then the 400 mg/kg group (D) and the 100 mg/kg group (A) being lowest.  $\text{K}^+$  and  $\text{HCO}_3^-$  in the AI treated groups were insignificant statistically from the control groups. The urea was noticed to have

been reduced significantly ( $P \leq 0.002$ ) with the AI treated groups (B, C, D) being far lower than the control. The creatinine also showed the AI group to have reduced values on comparing with the control, though insignificantly ( $P \geq 0.13$ ) (Table 3).

### 3.5 The Effects of AI on the Liver

The two parameters, Alanine amino Transferase (ALT) and Aspartate Amino Transferase (AST) in the control were seen to be insignificantly different from the AI treated groups statistically.

Looking at the values of the AST, the AI treated groups had very low values, the 100 mg/kg and the 200 mg/kg having  $54.80 \pm 22.99$  and  $106.00 \pm 45.61$  respectively to the control ( $159.20 \pm 65.12$ ) while the 400 mg/kg ( $156.60 \pm 42.80$ ) was close to the control. The ALT also had two treated groups exhibiting lower values to the control that is, the 200 mg/kg and the 400 mg/kg having  $50.60 \pm 16.20$  and  $65.80 \pm 17.76$  respectively but the 100 mg/kg ironically had a value ( $80.60 \pm 23.94$ ) slightly higher than the control ( $79.00 \pm 32.49$ ) group (Table 4).

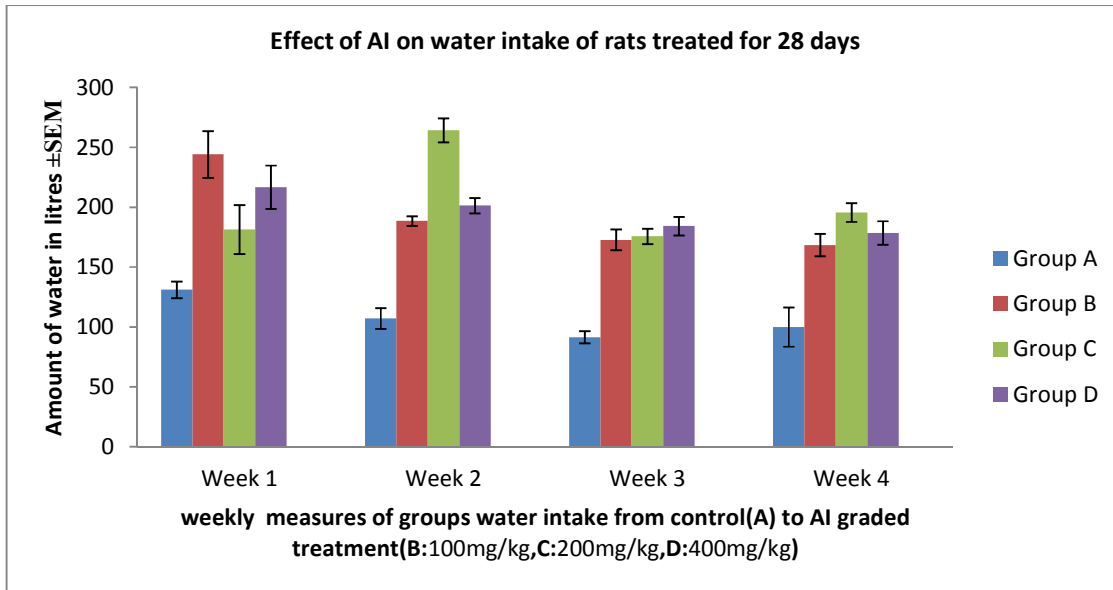


Fig. 1. Effect of AI on water intake of rats treated for 28 days

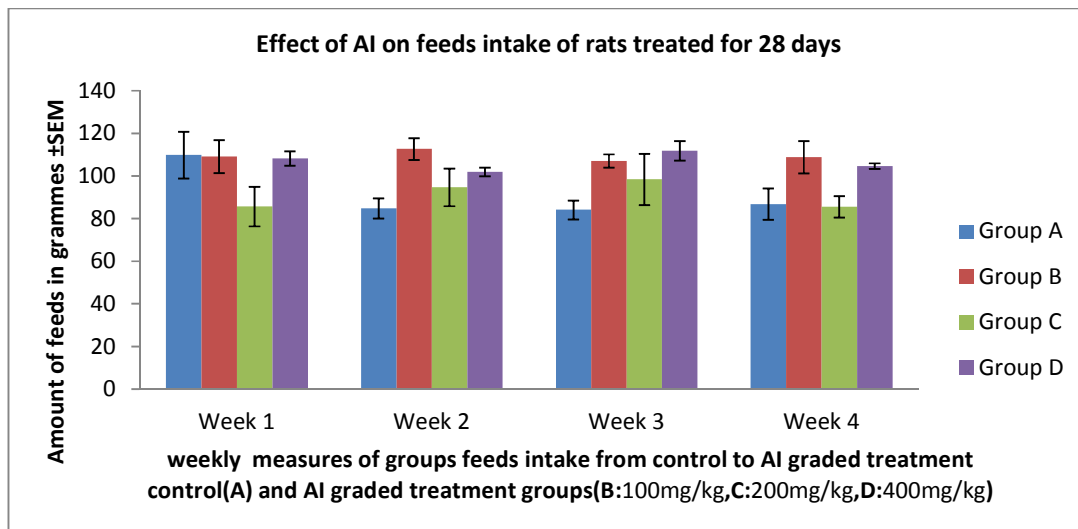


Fig. 2. Effect of AI on feeds intake of rats treated for 28 days

**Table 1. Effect of AI on red blood cells parameters and platelets**

	<b>RBC</b>	<b>HB</b>	<b>PCV</b>	<b>MCV</b>	<b>MCH</b>	<b>MCHC</b>	<b>PLATELETS</b>
Group A	5.89±	13.47±	42.63±	72.50±	22.97±	31.53±	401.00±
(Control)	0.15	0.35	0.72	1.64	0.54	0.32	97.62
Group B	5.82±	13.60±	43.07±	73.97±	23.43±	31.77±	846.33±
(100mg/kg)	0.32	0.46	2.82	0.69	1.29	2.03	60.08
Group C	6.11±	13.73±	44.27 ±	73.27±	22.60±	30.97±	855.00±
(200mg/kg)	0.23	0.52	0.32	3.02	0.31	1.16	141.05
Group D	6.18±	14.10±	47.50±	77.00±	22.70±	29.53±	847.00±
(400mg/kg)	0.20	0.25	1.47	1.17	0.40	0.48	306.56
ANOVA	0.05	0.02	0.02	0.55	0.18	0.54	0.36
B/W groups							

Mean ±SEM

RBC (red blood cell count); HB (haemoglobin concentration); PCV (pack cell volume); MCV (mean corpuscular volume); MCH (mean corpuscular haemoglobin); MCHC (mean corpuscular haemoglobin concentration)  
Units of parameters: MCV- femtoliters (fL); MCH- pictograms(pg); MCHC- (gm/dL); HB-(gm/dL); RBC- ( $\times 10^6$  / $\mu$ L); PCV- %

**Table 2. The effects of AI on white blood cells of rats treated for 28 days**

	<b>WBC</b>	<b>Neutrophil</b>	<b>lymphocytes</b>	<b>Monocytes</b>	<b>Eosinophil</b>	<b>Basophil</b>
Group A	13.47±	17.00±	77.00±	5.00±	0.33±	0.33±
(Control)	1.17	3.61	5.69	1.73	0.33	0.33
Group B	14.00±	19.33±	75.67±	4.33±	0.67±	0.00±
(100mg/kg)	1.65	2.85	3.18	0.88	0.33	0.00
Group C	8.67±	20.33±	72.00±	5.00±	2.33±	0.00±
(200mg/kg)	0.58	0.88	1.53	1.00	1.20	0.00
Group D	10.10±	14.00±	80.67±	4.33±	0.00±	0.00±
(400mg/kg)	0.95	4.16	2.33	1.21	0.00	0.00
ANOVA	0.18	0.47	0.39	0.83	0.28	0.46
B/W groups						

Mean ±SEM

**Table 3. The effects of AI on renal indices of rats treated for 28 days**

	<b>Na +</b>	<b>K</b>	<b>Cl</b>	<b>HCO3</b>	<b>UREA</b>	<b>Cr</b>
Group A (Control)	142.00±	6.34±	105.60±	12.80±	11.80±	32.60±
	1.05	0.41	0.81	2.42	0.52	3.91
Group B (100 mg/kg)	142.80±	6.18±	102.60±	14.80±	9.18±	28.60±
	0.73	0.31	1.12	1.28	0.40	1.86
Group C (200 mg/kg)	143.20±	7.28±	104.00±	13.20±	9.48±	26.60±
	0.66	0.69	0.71	0.86	0.43	3.04
Group D (400 mg/kg)	143.60±	5.94±	103.80±	16.00±	9.38±	29.80±
	0.40	0.35	0.37	0.71	0.58	2.52
ANOVA B/W groups	0.01	0.26	0.02	0.63	0.002	0.13

Mean ±SEM

#### 4. THE OUTCOMES OF THE ASSESSMENTS OF THE GROSS AND HISTOPATHOLOGICAL ORGAN PARAMETERS

Grossly, the organs (lungs, liver, heart, spleen, and kidney) looked healthy without any obvious pathological/structural abnormality.

#### 4.1 The Organ Weights of Animals

The organs weights across the groups (AI treated) were noticed to be insignificantly ( $P > 0.05$ ) different from the control for all the organs sampled (lungs, liver, heart and spleen) except for the kidney. The kidney organ weight was noticed to have increased significantly ( $P \leq 0.01$ )

in the groups treated with AI, though not dose-dependently as the 100 mg/kg (group B) AI treated showed the highest increase in organ size (0.016 g) and the 400 mg/kg and the 200 mg/kg having 0.015 g and 0.014 g respectively from the control (0.012 g).

#### 4.2 Histopathological Report (Photomicrograph)

Photomicrograph 1(H & E stain): Of the lungs tagged (a) is of the control Wistar rat exposed to distilled water. Note the alveolus (A) with the unicellular septum (arrows).

Photomicrograph 2 (H & E stain): The lungs of a Wistar rat tagged b exposed to aqueous methanolic *Andira inermis* stem bark extract at 100 mg/kg for 28 days. Note the thickened alveoli septa with mononuclear cellular infiltration (X) and pulmonary hemorrhage (arrows). The same features were seen in the 200 and 400 mg group. This concentration-dependent thickened alveoli septa with mononuclear cellular infiltration and pulmonary hemorrhage are indicative of interstitial pneumonia.

Photomicrograph 3 (H & E stain): Micrograph (tagged a) of the liver of a control Wistar rat exposed to distilled water. Note the portal triad (X) and the hepatic cord (arrow). The same feature was seen in the 400 mg group.

Photomicrograph 4(H & E stain): Micrograph (tagged c) of the liver of a Wistar rat exposed to aqueous methanolic *Andira inermis* stem bark extract at 200 mg/kg for 28 days. Note the hepatic necrosis (X) with mononuclear cellular infiltration (arrows). The same feature was seen in the 100mg group indicating a non-concentration-dependent hepatitis.

Photomicrograph 5(H & E stain): Micrograph (tagged a) of the heart of a control Wistar rat exposed to distilled water. Note the nucleus of the cardiomyocyte (arrowhead) and a branching cardiomyocyte (arrow)(no obvious lesion).

Photomicrograph 6(H & E stain): Micrograph (tagged c) of the heart of a Wistar rat exposed to aqueous methanolic *Andira inermis* stem bark extract at 200 mg/kg for 28 days. Note the nucleus of the cardiomyocyte (arrowhead) and a branching cardiomyocyte (arrow). Also with no obvious defeat and same reflected in the 100 and 400 mg groups.

Photomicrograph 7(H & E stain): Micrograph (tagged a) of the spleen of a control Wistar rat exposed to distilled water. Note the germinal follicle (arrow) and the red pulp (X).

Photomicrograph 8 (H & E stain): Micrograph (tagged d) of the spleen of a Wistar rat exposed to aqueous methanolic *Andira inermis* stem bark extract at 400 mg/kg for 28 days. Note the germinal follicle (arrow), the red pulp (X), and the melano-macrophage center (arrowhead). Those of the 100 mg were with the same features as 400 mg having a melano-macrophage center, indicating a non-concentration-dependent increased phagocytic activity. The 200 mg group presented normal features as the control.

Photomicrograph 9 (H & E stain): Micrograph (tagged a) of the kidney of a control Wistar rat exposed to distilled water. Note the glomerulus(G), distal convoluted tubule (D), and proximal convoluted tubule (P).

Photomicrograph 10(H & E stain): Micrograph (tagged d) of the kidney of a Wistar rat exposed to aqueous methanolic *Andira inermis* stem bark extract at 400 mg/kg for 28 days. Note the glomerulus(G), distal convoluted tubule (D), and proximal convoluted tubule (P). the same was seen in the control and the other treatment groups 100 mg and 200 mg but a rat (an outlier) in one of the 200 mg group was noticed with tubular necrosis .

## 5. DISCUSSION

The aqueous methanolic AI stem bark extract median lethal dose was above 5000 mg/kg [5] indicating the extract is relatively safe for single oral consumption. Since the plant is being investigated for its anti-diabetic effect [5] which may demand more frequent administration, the present study suffices for further deductions of the toxicity profile of the plant. However, the arrays of findings from this study were supportive at some instances of its relative safety and differ in another.

In this sub-acute toxicity study, the drop in the intake of water weekly throughout the experiment was statistically significant, and additionally, the significant reduction in feeds intake in the fourth (last) week of the experiment may be suggestive of poor appetite induced by the extract and or probable electrolyte imbalance that developed in the experimental period as was seen in the electrolyte assay with Na<sup>+</sup> haven been slightly

raised in a dose-dependent manner from the control and a balancing effect of Cl<sup>-</sup> that dropped. It could also be explained that the AI extract does not affect the vascular bed to cause vasodilatation that might stimulate taste that would demand increase intake of water as was the case of a study reporting an increase in water intake in rats treated with *Dracaena cinnabari* resin methanol extract [11].

The haematological indices suggest a desirable effect of AI extract (for anaemia) as it improves significantly ( $P \leq 0.02$ ) red blood cell count (RBC), haemoglobin concentration (HB) as well as the pack cell volume (PCV) dose-dependently. Though this did not extend to the mean corpuscular volume (MCV), mean corpuscular haemoglobin (MCH), and mean corpuscular haemoglobin concentration (MCHC). This confers on the extract erythropoietin potential which might be the reason for this increase that would, in turn, improve the oxygen-carrying capacity of the blood and amount of oxygen delivered to the tissues. This improvement of RBC was also reported of aqueous leaves to

extract of *Ocimum gratissimum* in rats in a subacute toxicity study [13]. Also, the platelet was seen to improve by double its concentration from the control to the AI treated groups, though not statistically significantly relevant ( $P > 0.05$ ), this may confer on the users a robust coagulation pathway sufficient to be useful in coagulopathies/ blood dyscrasias. Furthermore, the total white blood cell count and differentials (neutrophil, lymphocytes, monocytes, eosinophil, and basophil) counts which were insignificantly different statistically in-between groups (control and AI treated) implies that the extract did not trigger an autoimmune reaction/ germline proliferation. Or this may also imply that the extract was not contaminated enough to trigger any kind of inflammation or has no toxic effect on the white blood cells' germline. It suffices to mention that the AI treatment group had a shrunken spleen size relative to the control Fig. 3 which may be supportive of the drawn inference above. There was a report of aqueous extracts of *viscum album* (mistletoe) improving germline proliferation [14] in rats studied for 14 days.

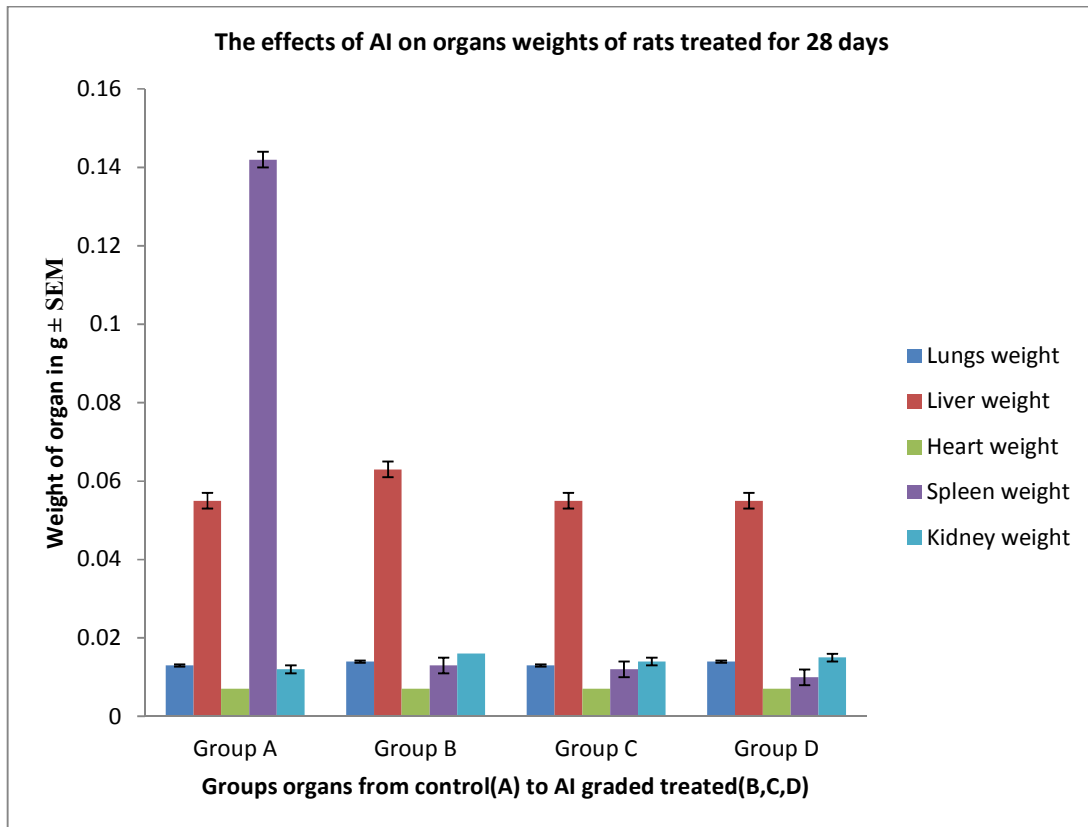
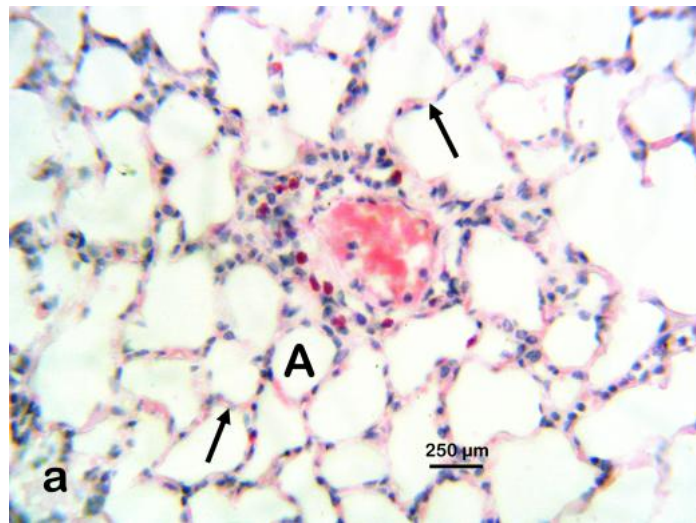


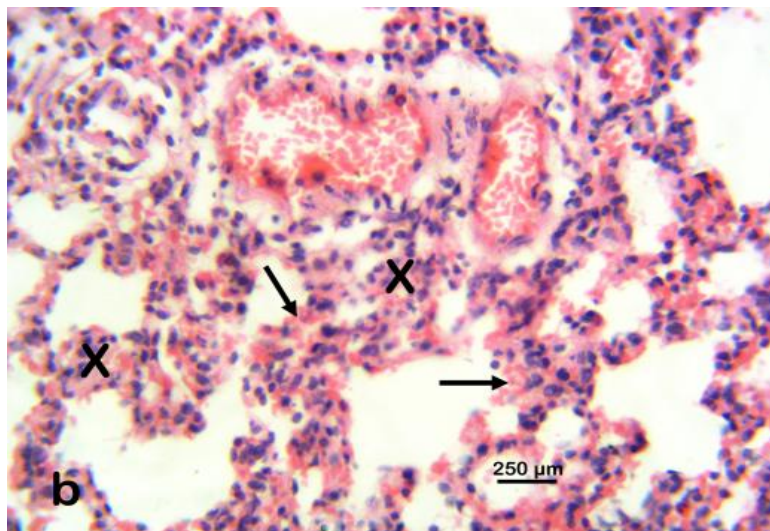
Fig. 3. The effects of AI on organs weights of rats treated for 28 days



**Lungs**



**Photomicrograph 1**



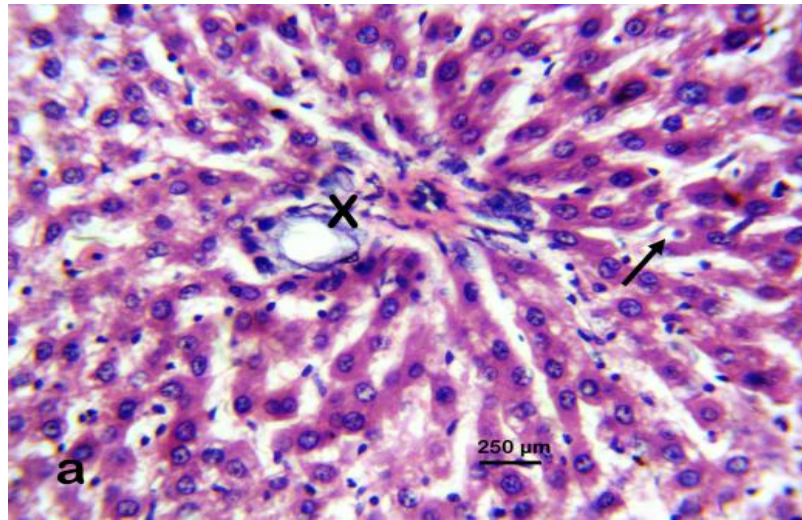
**Photomicrograph 2**

**Table 4. The effects of AI on hepatic enzymes of rats treated for 28 days**

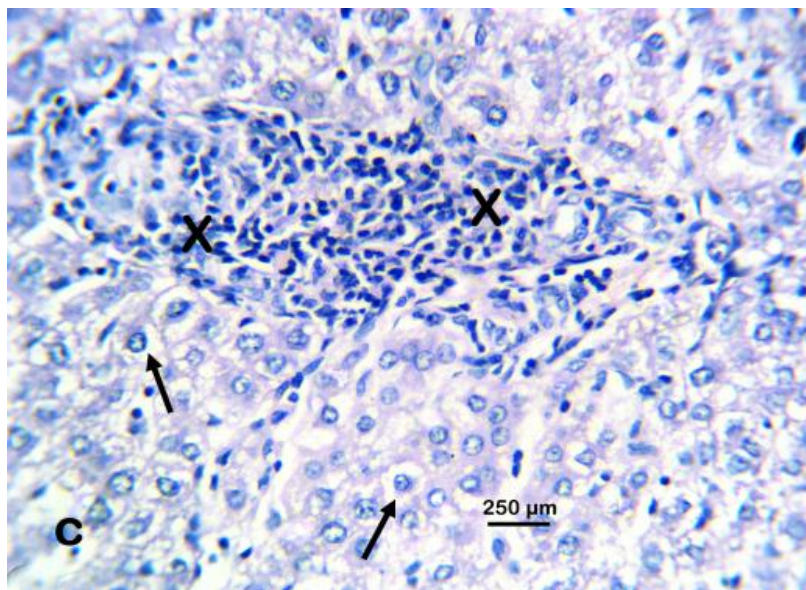
	<b>AST</b>	<b>ALT</b>
Group A (Control)	159.20± 65.12	79.00± 32.49
Group B (100 mg/kg)	54.80± 22.99	80.60± 23.94
Group C (200 mg/kg)	106.00± 45.61	50.60± 16.20
Group D (400 mg/kg)	156.60± 42.80	65.80± 17.76
ANOVA B/W groups	0.37	0.79

*Mean ±SEM*

## Liver



Photomicrograph 3



Photomicrograph 4

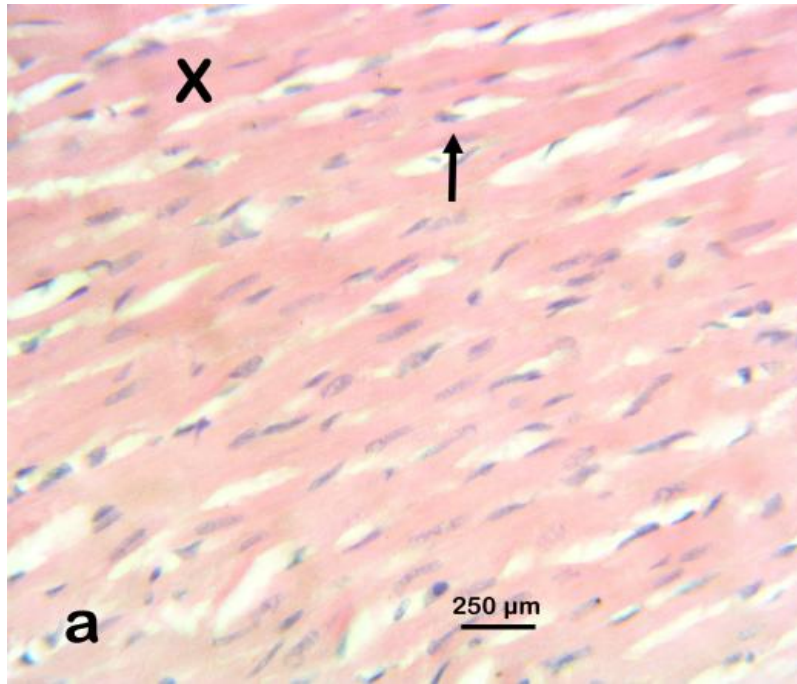
The renal indices, urea, seem to support the fact that the AI extract has or proffers a nephroprotective property being statistically significantly ( $P \leq 0.002$ ) reduced in the treatment group with the control with a higher concentration/ value. There is a recent report of *Sonchus oleraceus* extract (a medicinal plant) being nephroprotective [15]. This nephroprotective quality was supported by the creatinine level which also showed the AI group to have reduced values from the control, though

insignificantly Table 3. Furthermore, in concordance with the above argument, the electrolytes, chloride, and sodium of the AI group were significantly different from the control, with P values of  $P \leq 0.01$  and  $P \leq 0.02$  respectively. Ironically the kidney was rather larger in the organ treated groups (B, C and D) than with the control ( $P \leq 0.01$ ) Fig. 3. But the histopathology report showed the organ to have normal glomerulus, distal convoluted tubule, and proximal convoluted tubule (photomicrograph 9)

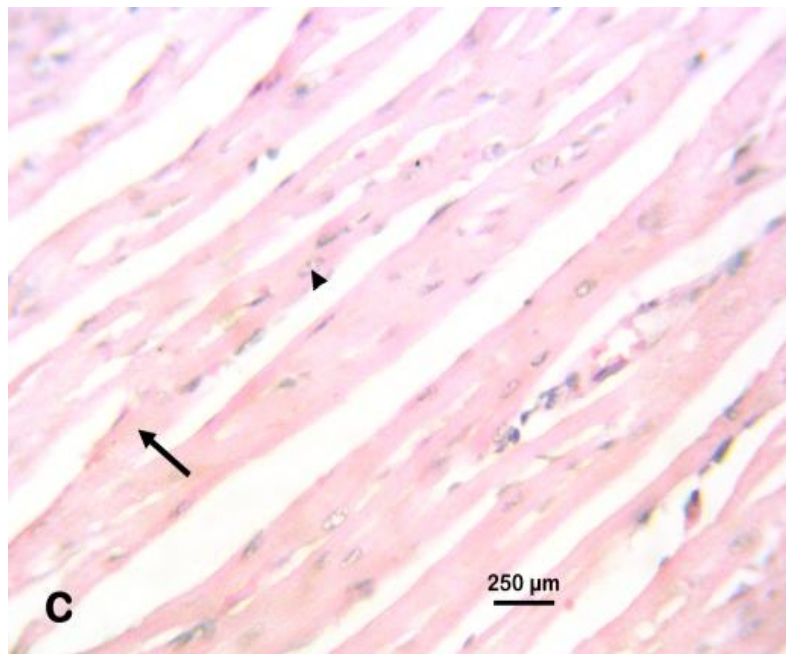
in the control and the other treatment groups 100 mg 400 mg and 200 mg but a rat (an outlier) in

one of the 200 mg group was noticed with tubular necrosis (photomicrograph 10).

### Heart



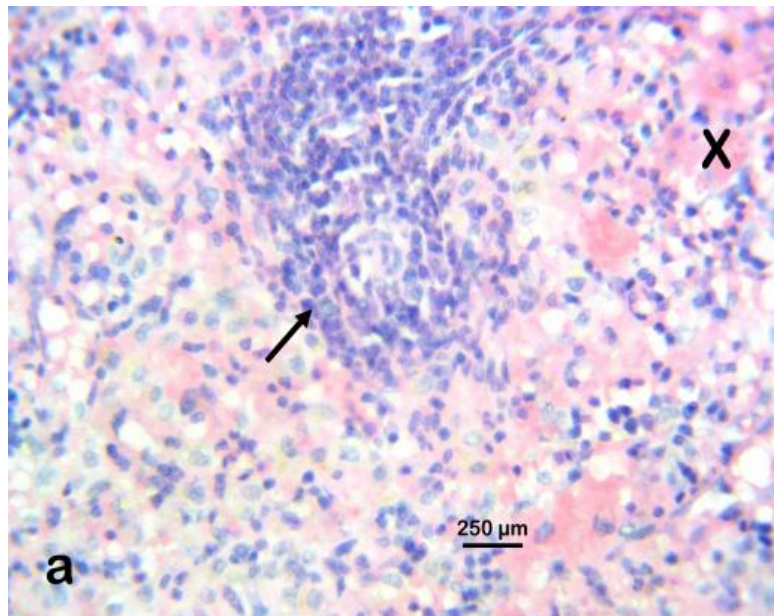
Photomicrograph 5



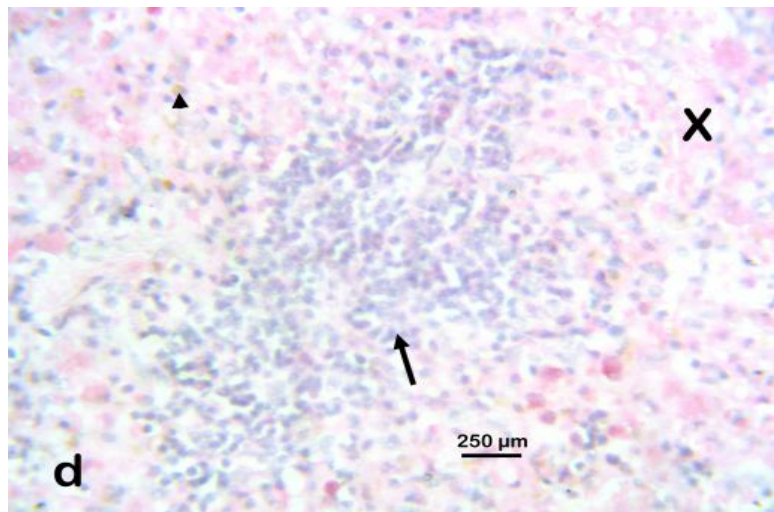
Photomicrograph 6



## Spleen



Photomicrograph 7

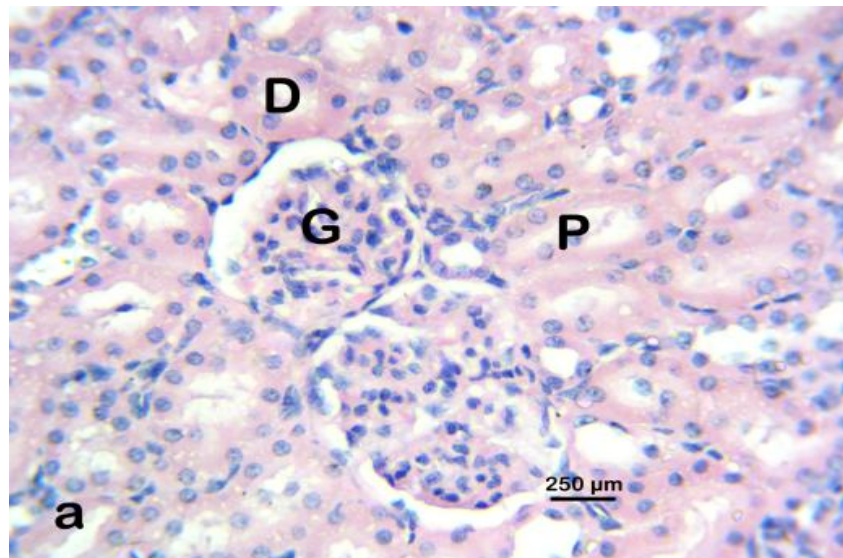


Photomicrograph 8

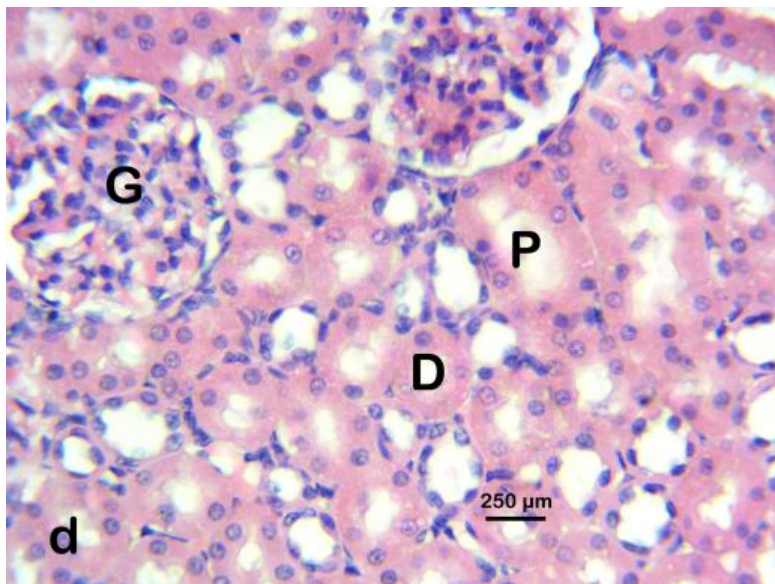
The results obtained from the hepatic enzymes assayed, aspartate aminotransferase (AST) and alanine aminotransferase (ALT), inferred that the AI extract might have hepatoprotective properties, though the obvious relative lower levels of the enzymes from the control were not statistically significant Table 4. Likewise, the sizes of the liver were insignificantly different among the treatment groups and the control. Additionally, the histopathological report that was

normal in the control and the 400 mg groups (photomicrograph 3) and the presence of hepatic necrosis with mononuclear cellular infiltration at 100 mg/kg and 200 mg/kg (photomicrograph 4) might infer a non concentration-dependent hepatitis. This might also have resulted from an infection picked up in the course of the experiment or due to the supplying laboratory as was reported in a study [16].

## Kidney



Photomicrograph 9

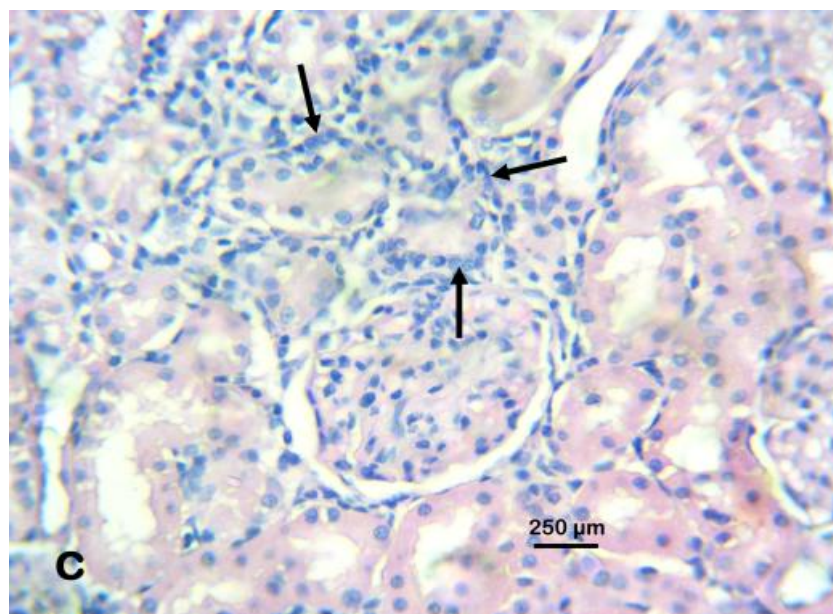


Photomicrograph 10

The heart was seen to be normal (photomicrograph 5) without any pathologic effect. This finding was supported by the gross heart weight in the treated groups being indifferent from that of the control group.

These two organs histopathological reports; lungs (interstitial pneumonia) (photomicrograph 2) and spleen (non-concentration-dependent increased phagocytic activity) photomicrograph

(photomicrograph 7&8) are supportive of the notion of an infective process earlier inferred which might have developed in the course of the experiment. Ironically, although the spleen weights in the treated AI extract group were insignificantly different from the control, the control group spleen organ size was extremely large and the treatment AI group has shrunken like – Fig. 3).



Photomicrograph 11

## 6. CONCLUSION

In conclusion, the aqueous methanolic extract of AI is a safe medicinal plant with the capacity to increase red blood cell count (RBC), hemoglobin concentration (HB) as well as the pack cell volume (PCV) and is non toxic to the heart. Additionally, it may have hepato-protective property, nephro- protective property and the ability to shrunken the spleen. Therefore, further pharmacognostic experimental research, as well as the new array of benefits suspected, can be carried out on the plant.

## CONSENT AND ETHICAL APPROVAL

All data related to this manuscript are presented within the text. Ethical approval and consent to participate. Ethical approval was gotten from the University of Abuja Research Ethics Committee on animal use (UAECAU/2018/002). The internationally accepted principles for laboratory animal use and care contained in the Canadian Council on Animal Care Guidelines were followed.

## ACKNOWLEDGEMENTS

The authors would like to appreciate the technical staff and animal holding unit of the

National Institute for Pharmaceutical Research and Development (NIPRD) Abuja, Nigeria.

## COMPETING INTERESTS

Authors have declared that no competing interests exist.

## REFERENCES

1. Obi RK, Iroagba II, Ojiako OA. Virucidal potential of some edible Nigerian vegetables. *African Journal of Bio technology*. 2006;5:1785–1788.
2. Maxwell Osaronowen Egua. In: *Pharmacognosy-medicinal plants* (, Intech Open). *Pharmacognostic Study of a Plant Seed Extract* (chapter 13); 2019. DOI:<http://dx.doi.org/10.5772/intechopen.81860>
3. Bruneton J. *Toxic plants dangerous to human and animals*. Lavoisier Publishing, Inc., Secaucus, N.J; 1999. (Isbn -1-898298-62-9)
4. Karem Kirven, Thomas Wyatt. *Herbal medicine Minnesota poison control system*; 2002. Available: [www.natap.org](http://www.natap.org).
5. Maxwell Osaronowen Egua, Florence Chimezie Nwinyi, Ode Julius Okwoche, Onakpa Micheal Monday, Akande



- Motunrayo Ganiyat, Onoja Samuel Okwudili, et al. Evaluation of *Andira inermis* stem bark extract for hypoglycaemic and antioxidant effects. *Clinical Phytoscience*. 2020;6:76. DOI: <https://doi.org/10.1186/s40816-020-00225-5> (Egua et al., 2020)
6. Hodges RE, Minich DM. Modulation of metabolic detoxification pathways using foods and food-derived components: A scientific review with clinical application. *J Nutr Metab*. 2015;2015:760689. DOI: 10.1155/2015/760689. Epub 2015 Jun 16. PMID: 26167297; PMCID: PMC4488002.
  7. Tropical Plants Database, Ken Fern. *Tropical*. The ferns.info. 2019-10-08. Tropical; 2014. Available:[theferns.info/viewtropical.php?id=Andira+inermis](http://theferns.info/viewtropical.php?id=Andira+inermis).
  8. Orwa et al. *Agroforestry database 4.0*; 2009. Available:[www.worldagroforestry.org](http://www.worldagroforestry.org).
  9. Organization for Economic Co-operation and Development (OECD). Test no. 407: Repeated dose 28-day oral toxicity study in rodents. Adopted: 3 October 2008: OECD Publishing; 2008.
  10. EO Etuk, V Igbokwe, OP Ajagbonna, MO Egua. Toxicological studies of a Nigerian commercial polyherbal product in albino rats. *Research Journal of Medicinal Plants*. 2009;3(2):52-60. ISSN1819-3435 ©Academic Journals Inc. Available:[www.academicjournals.com](http://www.academicjournals.com)
  11. Nashwan Abdullah Al-Affifi, Aied Mohammed Alabsi, Marina Mohd Bakri, Anand Ramanathan. Acute and sub-acute oral toxicity of *Dracaena cinnabari* resin methanol extract in rats. *BMC Complementary and alternative medicine*. 2018;18:50. DOI: 10.1186/s12906-018-2110-3
  12. Teco Diagnostics Kit Method. Teco diagnostics 1268 N. Lakeview Ave Anaheim, ca 92807 U.S.A; 1996.
  13. OE Ofem, EJ Ani, AE Eno. Effect of aqueous leaves extract of *Ocimum gratissimum* on hematological parameters in rats. *International Journal of Applied and Basic Medical Research Wolters Kluwer -- Medknow Publications*; 2012.
  14. Olusola Ladokun, Matthew Ojezele, Oluwatosin Arojoye. Comparative study on the effects of aqueous extracts of *viscum album* (mistletoe) from three host plants on hematological parameters in albino rats. *African Health Sciences*. 2015;15(2).
  15. Liliana Torres-González, Eduardo Cienfuegos-Pecina, Marlene M Perales-Quintana, Gabriela Alarcon-Galvan, Linda E Muñoz-Espinosa, Edelmiro Pérez-Rodríguez, et al. Nephro protective effect of *Sonchus oleraceus* extract against kidney injury induced by ischemia-reperfusion in wistar rats. *Hindawi. Oxidative Medicine and Cellular Longevity*. 2018;7. Article ID 9572803. Available:<https://doi.org/10.1155/2018/9572803>.
  16. Boot R, van Herck H, van der Logt J. Mutual viral and bacterial infections after housing rats of various breeders within an experimental unit. *Lab Anim*. 1996;30(1):42-5. DOI: 10.1258/002367796780744929. PMID: 8709572.

© 2021 Egua et al.; This is an Open Access article distributed under the terms of the Creative Commons Attribution License (<http://creativecommons.org/licenses/by/4.0>), which permits unrestricted use, distribution, and reproduction in any medium, provided the original work is properly cited.

Peer-review history:

The peer review history for this paper can be accessed here:  
<http://www.sdiarticle4.com/review-history/65577>