



Effect of Warm Water Bathe on the Testes and Sperm Quality of Adult Wistar Rats

Ugochukwu Samuel Aguwa ^{a*}, Ibeh Chidubem Temple ^a, Eze Echezona ^a,
Chioma Nwosu ^b, David Izuchukwu Okonkwo ^c, Adline Uchechi Uzoahia ^a,
Janeth, Adedokun ^a and Ifeanyichukwu Michael Owoh ^a

^a Nnamdi Azikiwe University, Nnewi Campus, Nigeria.

^b College of Nursing Sciences, Amichi, Nigeria.

^c Nnamdi Azikiwe University Teaching Hospital, Nnewi, Nigeria.

Authors' contributions

This work was carried out in collaboration among all authors. All authors read and approved the final manuscript.

Article Information

DOI: 10.9734/JOCAMR/2022/v18i230350

Open Peer Review History:

This journal follows the Advanced Open Peer Review policy. Identity of the Reviewers, Editor(s) and additional Reviewers, peer review comments, different versions of the manuscript, comments of the editors, etc are available here:

<https://www.sdiarticle5.com/review-history/88135>

Original Research Article

Received 07 April 2022

Accepted 11 June 2022

Published 20 June 2022

ABSTRACT

Hot water bathe is both therapeutic and habitual. Studies have shown that the testis functions optimally at temperatures slightly below body temperature. This study is designed to evaluate the effect of regular warm water bath on the histoarchitecture of the testis and the sperm quality in Wistar rats. Twenty rats were divided into four groups of five rats each based on closeness of body weight. Rats were soaked fully (except head and neck) inside water of varying temperatures. The control group A was soaked in normal water at room temperature. The other rats in groups B, C and D were exposed to warm water at 30°C, 35°C and 40°C respectively for 10 minutes every day for 14 days. Twenty four hours after the last exposure, the animals were weighed and sacrificed using chloroform sedation. The semen was extracted from the tail end of the epididymis for analysis of sperm quality while the testes were fixed in 10% formal saline for histological studies. Data was analyzed using the SPSS (version 21). Results obtained were expressed as Mean \pm SD in each group. Tested parameters were subjected to one-way analysis of variance (ANOVA) and differences between means were regarded significant at $P < 0.05$

The findings of the present study showed that warm water bath at 30°C and 35°C did not cause reduction in sperm count or rat weight. However, at 40°C spermatogenesis was adversely affected.

Keywords: Warm water bath; sperm parameters; testes; sperm motility.

1. INTRODUCTION

The testes are a paired organ within the scrotum surrounded by a strong capsule [1]. The testicular parenchyma is composed of 250 – 350 lobules, which drain through the mediastinum testis to the epididymis. A lobule of the testis consists of one or several seminiferous tubules, which end and start at the rete testis [1]. The testes are the male gonads. Like the ovaries to which they are homologous, testes are components of both the reproductive system and the endocrine system. The primary function of the testes is to produce sperm (spermatogenesis) and produce androgens, primarily testosterone [2]. Both functions of the testicles are influenced by gonadotropic hormones produced from the anterior pituitary [2]. The testicles are located in the scrotal sac which hangs outside of the male's body. This is to ensure that they are maintained at a temperature 2-3 degrees lower than that of body temperature. It is true that high temperatures may affect spermiogenesis, however the level of temperature and the duration of exposure determines how much impact it has [3].

Supporting cells called sertoli cells play important roles in spermatogenesis by nourishing of developing sperm cells. They also act as phagocyte consuming residual cytoplasm during spermatogenesis [3], whereas the leydig cells are the main sources of androgen production [4]. Both types of cells can readily be affected by high temperature [5]. Alteration in functions of these cells may lead to a change in male hormone balance, hence disturbing the process of spermatozoa [6]. Investigators believe that excessive exposure to heat in the form of hot bathing water can significantly affect the testicular functions and may compromise spermatogenesis [7]. This study was designed to verify these claims.

Bathing is the washing of the body with a liquid, usually water or an aqueous solution or the immersion of the body in water [8]. It is a means of achieving cleanliness by washing away dead skin cell, dirt, and soil and as a preventative measure to reduce the incidence and spread of disease [8]. It may also be practiced for religious ritual or therapeutic purposes [8]. Any agent that increases the temperature inside the testicles (radiations, hot water, ultrasound waves etc.) can compromise the process of

spermatogenesis and may lead to impaired fecundity and infertility [9].

Hydrotherapy has been practiced for centuries. Both the use of hot and cold water can have beneficial effects on the body [10]. Showering is the most common form of bathing worldwide. Daily immersion of rat scrotum in warm water ($44\text{ }^{\circ}\text{C} \pm 1\text{ }^{\circ}\text{C}$) for a period of 8 weeks caused loss of testicular weight, atrophy of tubules and degeneration of the germinal epithelium. On reproductive performance, the rats were found to be infertile [11]. Although many authors believe that the effects of heat are fully reversible, there is now evidence of long-term effects, following either locally applied heat or temporary induced cryptorchidism. These long-term effects appear to be different from those seen following irradiation, and may indicate a failure of sertoli cell function. Sperm produced by mice which had been exposed to a hot environment bind to ova normally but are less able to fertilize in vivo and in vitro, even when motile sperm are selected by a swim-up procedure, and many of the resultant embryos do not develop normally [11].

2. MATERIALS AND METHODS

The materials used for this study include 20 adult male Wistar rats weighing 120g-180g, Metal mesh grid cages, Top feed growers mash (Premier feed mills co. LTD, Plateau state, Nigeria), gas burner, plastic basin of 10 liters deep, Weighing Balance, Dissecting kit, Measuring cylinder, Conical flask, Rotatory microtome (Leica products, MRM-1120), formal saline, hand lens, Neuber counting chamber, (superior Marienfed, Germany), Light binocular microscope (Olympus, china with serial number X52-10TBN), Glass slide, Spatula, Freshly prepared bouin's fluid, Thermostat oven, Haier Thermocool refrigerator.

2.1 Location and Duration of Study

This study was carried out at the Animal House of the Department of Anatomy, Faculty of Basic Medical Science, Nnamdi Azikiwe University, Nnewi, Anambra State.

2.2 Research Protocol

Twenty (20) adult male Wistar rats weighing between 120-180g were purchased from Nnamdi Azikiwe University animal farm in Okofia, Nnewi south L.G.A, Anambra state. The animals were

housed in well ventilated cages under normal temperature. They were fed with standard diet and water and were acclimatized for a period of fourteen days. The floors of the cages were overlaid with sawdust obtained from a nearby sawmill and the cages cleaned every two days to prevent infections. The weight of the rats were taken and documented after the acclimatization period. The Guide for the Care and Use of laboratory Animals was followed [12].

The twenty rats were divided into four groups (A, B, C, D) of five rats each. Rats in the control group were immersed in normal room temperature water for 10 minutes daily for 14 days. The immersion was such that the water was deep enough to contain the whole body of the rats but shallow enough to have them raise their head out of the water to avoid drowning. The other groups were immersed in warm water at 30°C, 35°C and 40°C for rats in groups B, C and D respectively. After each day's exposure the rats were returned to their cages.

2.3 Animal Sacrifice

Twenty-four hours after the last exposure, the rats were weighed and the weight documented. Rats were then sacrificed by chloroform sedation according to the method reported by Aguwa et al., [13]. Immediately after sedation, sperm was retrieved from the epididymis of each rat for semen analysis, after which the testes were harvested and fixed in 10% formal saline.

2.4 Sperm Parameters

A thin smear of liquefied well-mixed semen was made on a slide. While still wet, the smear was fixed with diluted neutral buffered formalin (1:20) and with the aid of light microscope at x400 magnification the smear was examined for normal and abnormal spermatozoa. A count of 100 was made and the percentage showing normal and abnormal morphology was recorded.

Morphological changes were clear under the power of x400. In this study, a spermatozoon was considered abnormal morphologically if it had one of the following features: rudimentary tail, round head and detached head. Sperm count, sperm morphology and sperm motility were recorded for each rat.

2.5 Tissue Processing

After 48 hours, the testis was processed at the Histology Laboratory, Anatomy department, Nnamdi Azikiwe University Nnewi campus using the routine H & E method according to Drury and Wallington [14]. The tissues were subjected to dehydration, clearing, infiltration, sectioning and staining after which slides were examined under light microscope.

2.6 Data Analysis

Data was analyzed using the SPSS (version 21) software package. Results obtained were expressed as Mean value ± SD in each group. Tested parameters were subjected to one-way analysis of variance (ANOVA). Differences between means were regarded significant at P<0.05.

3. RESULT OF PHYSICAL CHANGES

During the period of acclimatization, all the Wistar rats were healthy, with smoothly laid hairs on their skins, pinkish eyes, and normal skin color. After commencement of the experiment, all the groups showed no clinical sign.

Results are presented as Mean ± S.D of 5 rats in each group.

Means of rat weight were compared using the student's t-test and values are considered statistically significant at P < 0.05.

Table 1. Result of rat body weight changes following immersion in warm water for 14 days

Group	Initial weight	Final weight	P-value
A	149 ± 1.15	183.5 ± 12.12	0.0006
B	148.5 ± 2.88	173 ± 5.77	0.0001
C	146.75 ± 0.5	168 ± 3.46	0.0000
D	166 ± 4.62	186 ± 6.93	0.0015

The result of rat weight as presented in Table 1 above shows that, animals in the control group had a significant weight gain at the end of the experimental period (FINAL) compared to the initial period (INITIAL). This was observed for rats in the experimental groups, B, C and D which all had significant weight gain at the FINAL compared with INITIAL.

FORMULAR:
$$\frac{\% \text{ weight gain} = \text{weight difference} \times 100}{\text{Initial weight}}$$

Data were analyzed using One-way ANOVA and multiple comparison, and data were considered significant at P<0.05.

The result of semen analysis shows that there was no statistically significant different in the sperm count of rats in the experimental groups B, C and D compared to the control. Recall that rats in the experimental group B, C and D were immersed in warm water at 30°C, 35°C and 40°C respectively.

The result of the sperm status showed percentage of normal and abnormal sperm for the experimental group3 compared to the control. The control group had the highest percentage of normal sperm cells while experimental group B had the least percentage of normal sperm cells.

Table 2. Showing percentage rat weight gain following immersion in warm water for 14 days

Group	Initial weight (g)	Final weight (g)	Weight difference	Percentage weight gain (%)
A	149	183.5	34.5	23.15
B	148.5	173	24.5	16.49
C	146.75	168	21.25	14.48
D	166	186	20	12.04

Table 3. Effect of warm water bath on relative testicular weight

Group	Relative Weight of Testis (%)	p-value
Group A	1.64±0.09	
Group B	1.64±0.13	0.98
Group C	1.53±0.23	0.69
Group D	1.66±0.26	0.95

Table 4. Effect of warm water bath on sperm count in Wistar Rats

Group	Sperm count	P-valve
A	225.00 ± 6.22	
B	152.50 ± 7.99	0.0823
C	603.00 ± 9.61	0.1024
D	560.50 ± 1.2	0.0935

Table 5. Effect of warm water bath on sperm status in Wistar rats

Group	Normal (%)	Abnormal (%)
A	82.5	17.5
B	77.5	22.5
C	81.5	18.5
D	80	20

Result of histological

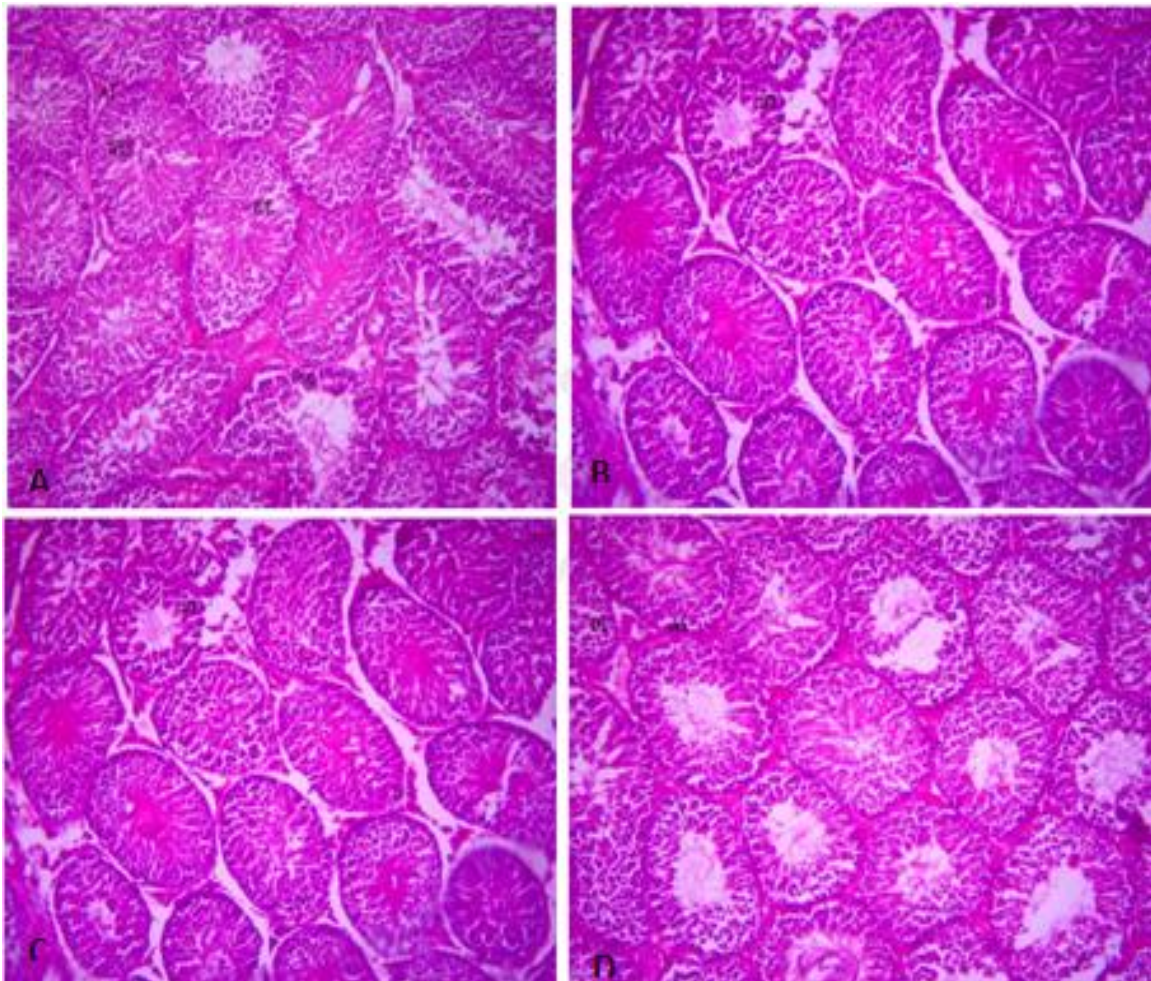


Fig. 1. Representative Photomicrograph of rat testis: A (control) shows normal testicular architecture with active seminiferous tubules that are lined with interstitial cells of leydig (ICL), sertoli cell (SC) and well enhanced spermatogenesis (ES); B (rats exposed to 30°C warm water) shows mild distortion (D) of the seminiferous tubules otherwise normal with moderately enhanced spermatogenesis (S); C (rats exposed to 35°C warm water shows normal seminiferous tubules with mild focal area hemorrhage (H) within the basal layer; D (rats exposed to 40 C warm water) shows seminiferous tubules with moderate arrest of the spermatogenesis (AS) and areas of cellular distortion. (H/E) (x400)

4. DISCUSSION

This study was principally carried out to investigate the effect of warm water bath on the testes and semen parameters of adult male Wistar rats. The result of this study reveals that immersion of rats in warm water at 30°C, 35°C, and 40°C respectively caused some characteristic physical changes as evident in the physical activities of the rats. The rats in the control group showed no observable changes in their physical appearance as they remained healthy throughout the experiment. Stool color

remained normal in all groups. There was aggressiveness when exposed or immersed in water in group B, C and D, which were immersed in 30°C, 35°C, and 40°C respectively. Group B rats however showed less reactivity when immersed in water.

Observation showed that from the period of acclimatization to the end of administration, there was significant increase in body size in all groups. This could be physiological as the only substance they were exposed to was food and water. The increase in body weight of the rats

indicated that the warm water bath had no adverse effect on the body weight of the rats [15,16]. This agrees with the work done by Venkatachalam and Ramanathan, [16], which reported a general increase in body weight following exposure to warm water ($44 \pm 1^\circ\text{C}$). The relative organ weight result shows there was a non-significant difference in relative weight of testis in Groups B, C and D when compared to the control. This is in line with the work of Olurode et al., [17] on testicular histomorphometry and semen parameters of West African Dwarf bucks.

The result from the analysis of variance ANOVA obtained from the semen analysis carried out showed that there was a non-significant difference in sperm count in Group B, C and D which received 30°C , 35°C , and 45°C respectively when compared to group A. This does not agree with the work done by Gbotolorun et al., [18] who reported that warm water caused morphological changes in the testis and significant reduction in motile sperm count and sperm motility. In the present study, it was observed that after exposure to warm water, there was no statistically significant difference in active sperm motility when compared with Group A (control). This does not agree with the work done by Gbotolorun et al., [18] which reported a significant increase in active sperm motility on short-term scrotal exposure to elevated temperature prior to mating.

The result from histological studies of the control group A showed normal testicular architecture with active seminiferous tubules that are lined with interstitial cells of the Leydig, Sertoli cell and well enhanced spermatogenesis. However, group B micrographs show mild distortion of the seminiferous tubules but otherwise normal testicular histoarchitecture. This agrees with the result of Venkatachalam and Ramanathan, (1961), who studied the effect of moderate heat on the testes of rats and monkeys and reported that there was a mild destruction of cells of the seminiferous tubules, though the mechanism was unclear. It is understood that the scrotal sac confers some level of protection on the testes. Group C which received 35°C showed mild focal area hemorrhage within the basal layer of testis. This agrees with the result of Gbotolorun et al., [18], who reported disintegration in the arrangement of the cells of the spermatogenic series and slight widening and destruction of the interstitium and sperm cells following testicular exposure to heat. Group D which received 40°C

showed moderate arrest of the spermatogenesis and areas of cellular distortion. This is due to the adverse effect of heat on the testis. This agrees with the result of Venkatachalam and Ramanathan, (1961), who reported generalized atrophy of the tubular epithelium with complete absence of spermatogenic activity.

Submerging ourselves in water, whether in a bathing receptacle or in a natural body of water is something we do for personal hygiene, leisure and health, but the habitual practice of warm water bath may enhance the chances of testicular damages (Venkatachalam and Ramanathan, 1961).

5. CONCLUSION

The findings of the present study showed that warm water bath at 30°C and 35°C did not cause reduction in sperm count or rat weight. However, water at 40°C adversely affected spermatogenesis.

6. RECOMMENDATION

Following the result of this study, it is imperative to suggest possibility of testicular damage that result from the habitual bathing of warm water at 40°C . We therefore recommend that oxidative stress parameter of rats be examined in future studies.

CONSENT

It is not applicable.

ETHICAL CLEARANCE

The ethical approval was obtained from the ethical committee of Faculty of Basic Medical Sciences, Nnamdi Azikiwe University, Nnewi, before the commencement of the research and was assigned the number NAU/CHS/NC/FBMS/230.

COMPETING INTERESTS

Authors have declared that they have no known competing financial interests OR non-financial interests OR personal relationships that could have appeared to influence the work reported in this paper.

REFERENCES

1. Chaurasia BD. Human anatomy, volume I. 4th Edition. New Delhi: CBS Publishers; 2010.

2. Hepner DL, Harnett M, Segal S, Camann W, Bader AM, Tsen LC. Herbal medicine use in parturients. *Anesthesia & Analgesia*. 2002;94(3):690-693.
3. Seco-Rovira V, Beltrán-Frutos E, Ferrer C, Sáez FJ, Madrid JF, Pastor LM. The death of sertoli cells and the capacity to phagocytize elongated spermatids during testicular regression due to short photoperiod in Syrian hamster (*Mesocricetus auratus*). *Biology of reproduction*. 2014;90(5):107-1.
4. Zirkin BR, Papadopoulos V. Leydig cells: formation, function, and regulation. *Biology of reproduction*. 2018;99(1):101-111.
5. Pei Y, Wu Y, Cao J, Qin Y. Effects of chronic heat stress on the reproductive capacity of male Rex rabbits. *Livestock Science*. 2012;146(1):13-21.
6. Mieusset R, Bujan L. Testicular heating and its possible contributions to male infertility: A review. *International journal of andrology*. 1995;18(4):169-184.
7. Mohamed SS, Abdelatif AM, Adam AAG. Effects of exposure to solar radiation on thermoregulation and semen characteristics of sudanese desert rams (*Ovis aries*). *Global Vet*. 2012;9:502-507.
8. Reece WO, Rowe EW. *Functional anatomy and physiology of domestic animals*. John Wiley & Sons; 2017.
9. Clarke AE. Introduction: Gender and reproductive technologies in East Asia. *East Asian science, technology and society: an international journal*. 2008; 2(3):303-326.
10. Prankel S. *Hydrotherapy in practice*. In practice. 2008;30(5):272-277.
11. Setchell BP, Waites GM. The exocrine secretion of the testis and spermatogenesis. *Journal of reproduction and fertility*. Supplement. 1971;13:15-27.
12. Albus U. *Guide for the care and use of laboratory animals* (8th edn); 2012.
13. Aguwa US, Nnamdi OS, Nnabuihe ED, Elizabeth EC, et al. Evaluating the effect of chloroform inhalation as a method of euthanasia on the cerebellum and hippocampus of adult wistar rats. *Journal of Advances in Medical and Pharmaceutical Sciences*. 2020;14-25.
14. Drury RAB, Wallington EA. *Carleton's histological technique* 5th ed. New York: Churchill Livingstone; 1980.
15. No TA. Mayo foundation for medical education and research. *Intellectual Property*. 2001;632(2386300):632-5539480.
16. Venkatachalam PS, Ramanathan KS. Effect of moderate heat on the testes of rats and monkeys. *Reproduction*. 1962; 4(1):51-56.
17. Olurode SA, Adebayo AO, Dawodu AO, Oyekan IO. Testicular histomorphometry and semen parameters of West African Dwarf bucks. *Sokoto Journal of Veterinary Sciences*. 2018;16(1):24-30.
18. Gbotolorun SC, Yama OE, Dosumu OO, Kusemiju TO, Adebajo AO. Short-term scrotal exposure to elevated temperature prior to mating increase male ratio at birth in Sprague-Dawley rats. *African Journal of Biomedical Research*. 2017;20(2):183-188.

© 2022 Aguwa et al.; This is an Open Access article distributed under the terms of the Creative Commons Attribution License (<http://creativecommons.org/licenses/by/4.0>), which permits unrestricted use, distribution, and reproduction in any medium, provided the original work is properly cited.

Peer-review history:
The peer review history for this paper can be accessed here:
<https://www.sdiarticle5.com/review-history/88135>