



# Mucocele: A Case Report with Etiopathogenesis, Clinical Features and Various Treatment Options

Chaurasia Priya Dayashankar<sup>1\*</sup>, Sheela Kumar<sup>1</sup> and Usha Hegde<sup>1</sup>

<sup>1</sup>Department of Periodontology, JSS Dental College and Hospital, JSS University, Mysuru-570015, India.

## Authors' contributions

This work was carried out in collaboration between all authors. All authors read and approved the final manuscript.

## Article Information

DOI: 10.9734/BJMMR/2016/28157

### Editor(s):

(1) Karl Kingsley, Biomedical Sciences and Director of Student Research University of Nevada, Las Vegas - School of Dental Medicine, USA.

### Reviewers:

(1) Raghu Dhanapal, AIMST University, Malaysia.  
(2) R. Sudarshan, Best Dental Science College, India.

Complete Peer review History: <http://www.sciencedomain.org/review-history/16057>

## Case Report

Received 4<sup>th</sup> July 2016  
Accepted 21<sup>st</sup> August 2016  
Published 5<sup>th</sup> September 2016

## ABSTRACT

A mucocele is a benign, mucous-containing cystic lesion of the minor salivary glands presenting as a distinct, fluctuant, painless swelling of the mucosa. Mucocele is a clinical term used that includes mucous extravasation phenomenon and mucus retention cyst. Because each has a distinctive pathogenesis and microscopy, they are considered separately. Extravasation mucocele is the most common type of the two and the most common reason for mucocele is traumatic injury to the minor salivary ducts. They can appear at any site where minor salivary gland is present. The most common site is lower lip followed by the tongue, floor of mouth and buccal mucosa. There are various modalities for the treatment of mucocele.

This paper reviews a case of extravasation type of mucocele; its etiopathogenesis, clinical features and various treatment options.

**Keywords:** Mucocele; mucus extravasation cyst; traumatic injuries.

## 1. INTRODUCTION

The mucocele is a common lesion of the oral mucosa that results from rupture of a salivary

gland duct and spillage of mucin into the surrounding soft tissue [1]. This spillage is most commonly due to the local trauma in the region. Most common region for mucocele is lower lip.

\*Corresponding author: E-mail: [smilealot19@yahoo.in](mailto:smilealot19@yahoo.in);

Mucocele rarely develops on the upper lip. This is in contradiction to salivary gland tumors, which are not unusual in upper lip but are distinctly uncommon in the lower lip. Morphologically, there are two types of mucocele: Extravasation mucoceles and Retention mucoceles [1].

Extravasation mucocele- results from a broken salivary gland duct, with the subsequent spillage of mucous into the soft tissue around the gland accompanied by infiltrative changes.

As a result of blockage of salivary gland ducts, distention and accumulation of secretions takes places which results in the formation of retention type of mucocele.

The extravasation mucocele is the most frequent type of mucocele. The term "extravasation mucocele" of the Anglo-American literature is identical with the term "mucus granuloma" ("Schleimgranulom") [2]. The main signs of the mucus granulomas are: Predominant location at the lower lip, age peak in the second decade and more frequent occurrence in the male sex [2]. Three stages of development can be distinguished in the pathogenesis of the mucus granulomas: An initial stage (interstitial mucus lakes), a resorption stage (mucus granulomas with macrophages, foam cells and foreign body giant cells) and a terminal stage with the development of a pseudocyst (capsule of collagen tissue, no epithelial demarcation) [2]. The retention mucocele (synonym: mucus retention cyst) is a rare type of mucocele. The main signs are: nearly equal occurrence in all oral regions, age peak in the 8th decade, and moderate predominance of the female sex. Unlike the mucus retention cyst, extravasation mucocele is not a true cyst because it lacks an epithelial lining.

## 2. ETIOPATHOGENESIS

The two main etiological factors for mucocele are:

1) Traumatic injuries 2) Obstruction of salivary gland duct [3].

Bagan et al. [4] conducted a clinical and histopathological study of 25 mucoceles of the oral cavity. Incidence was found to be greatest between age 10 and 20, with no significant differences in terms of sex. The lower lip was most frequently affected, with other locations being much less common. The main etiology amongst the cases was traumatic injuries.

Among the extravasation mucoceles, the occurrence of initial phase was 11.7% and reabsorption stage was and reabsorption stage 76.4% [4].

### 2.1 Clinical Features

Mucocele typically appears as dome shaped mucosal swelling that ranges from 1 to 2 mm to few centimeters in size. They are most common in children and young adults and can also occur in older individuals. Spillage of mucin in the connective tissue takes place. The spilled mucin imparts a bluish translucent hue to the swelling. Similar lesion in the floor of the mouth is called as ranula.

### 2.2 Diagnosis

Diagnosis of mucocele is very simple. Mostly it can be identified and diagnosed clinically. The appearance of mucoceles is pathognomonic and the following data are crucial: lesion location, history of trauma, rapid appearance, and variations in size, bluish colour and the consistency [5]. Other method for diagnosis of mucocele is fine needle aspiration biopsy (FNAB), especially when differential diagnosis of angiomatous lesion is involved. The clinical differential diagnosis for mucocele are: fibroma, lipoma, haemangioma, varix, epidermoid cyst, salivary duct cyst, traumatic neuroma, mucoepidermoid carcinoma, pyogenic granuloma, granular cell carcinoma, lymphangioma and blue nevi which can be differentiated and a final diagnosis arrived at by histopathological examination [6].

### 2.3 Histopathological Findings

The majority of mucocele, being of the extravasation type, consists of a circumscribed cavity in the connective tissue and submucosa, producing an obvious elevation of the mucosa with thinning of the epithelium as though it were stretched. The cavity itself is not lined by epithelium and is therefore not a true cyst.

### 2.4 Treatment

There are many treatment options for mucocele. The conventional treatment includes surgical excision of the mucocele followed by histopathological examination to avoid any diagnosis of tumorous lesion. Other options are

marsupialization, CO2 lasers, cryosurgery, laser vaporization and electrocautery for the treatment of mucocele. The recurrence rate is not common for mucocele, so as a safety measure we should excise the surrounding glandular acini and remove the lesion till the muscular layer.

## 2.5 Case Report

A 17 years old male patient reported to the outpatient Department of Periodontology in JSS Dental College, Mysuru. This patient was hit by a cricket bat. A small swelling was noted on the left side of the lower lip. During this visits to the department of periodontology it was noted that the lower lip swelling had gradually attained 9 mm (Fig. 1) × 8 mm (Fig. 2) diameter and soft, fluctuant, palpable and non-tender in nature.

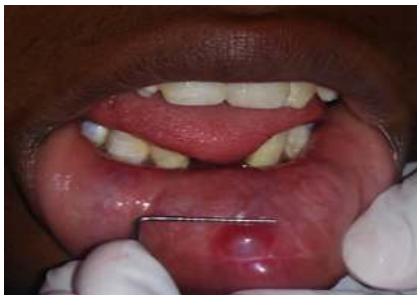

Fig. 1. Horizontal dimension of mucocele

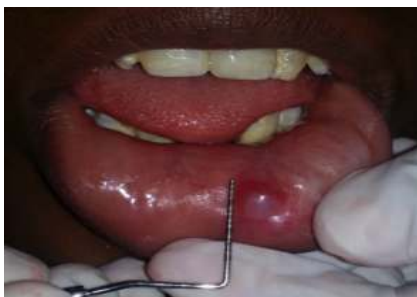

Fig. 2. Vertical dimension of mucocele

The swelling was painless and no history of fever or malaise was present. Patient was informed about the increasing nature of the swelling and he was advised excision of the same. Patient agreed and signed an informed consent for the surgery.

The lab investigations were conducted and the values were well within the normal range.

The differential diagnosis were made was focal fibrous hyperplasia, salivary gland tumor

(Especially mucoepidermoid carcinoma), vascular malformation, mucus retention cyst, mucus extravasation phenomenon, venous varix and soft tissue neoplasm such as neurofibroma or lipoma [1].

Local infiltration was given in the lower lip with 2% lignocaine. Elliptical incision was given near the borders of the mucocele (Fig. 3). Complete excision of the mucocele was done (Fig. 4). The surgical site was irrigated with Povidine iodine saline solution and primarily closed with 3-0 silk sutures. All postoperative instructions were given and analgesics were prescribed. Follow up of 1 month was uneventful (Fig. 5). Follow up of 8 months has not shown any recurrence (Fig. 6). The excised tissue was sent for histopathological investigation.

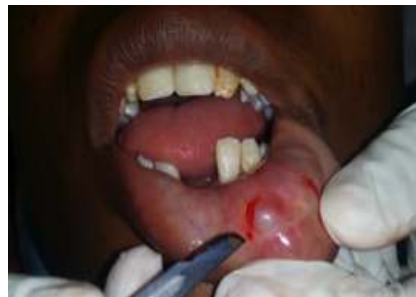

Fig. 3. Incision of mucocele

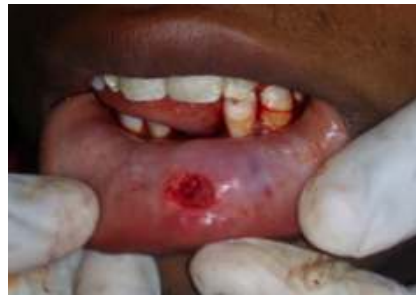

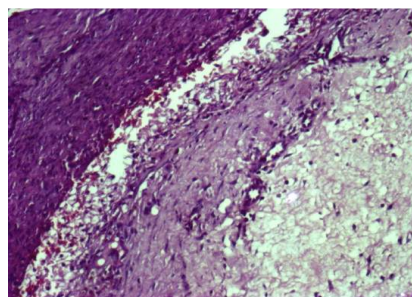
Fig. 4. Excision of mucocele

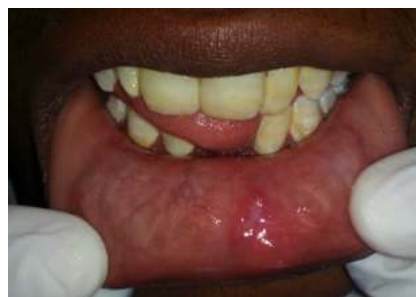
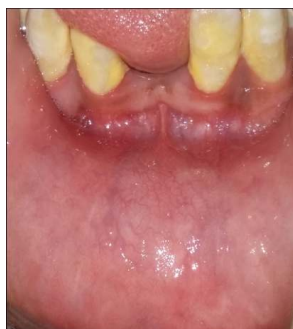
Fig. 5. Healed tissue (1 month follow up)



**Fig. 6. No recurrence (8 months follow up)**



**Fig. 7. Photomicrography (H& E 10X)**

### 2.6 Histopathological Findings

Hematoxylin and eosin section reveal stratified squamous epithelium, which was atrophic in most areas. The connective tissue showed a well-defined fibrous capsule surrounding a pale eosinophilic mucous accumulation, consisting of muciphages, few chronic inflammatory cells and blood vessels. (Fig. 7). The above findings are suggestive of extravasation mucocele.

### 3. DISCUSSION

Mucoceles of the lower lip minor salivary glands are very common. 303 cases in 15 articles is reviewed using pubmed, Google Scholar and Medline Database using "mucocele of lower lip" as the keyword (Table 1.) [6-19]. In this case the patient was a male patient with mucocele on the left lower aspect. The patient had undergone a traumatic injury is the most common reason for mucocele. The treatment of the patient was

**Table 1. The description of overall mucocele cases in lower lip region**

Author	Year	Number of cases	Age/Sex	Position/ Location on lower lip	History of trauma	Treatment
Seifert G et al. [1]	1981	273	2 <sup>nd</sup> decade of life	79% were lower lip	-	-
Nehabargava et al. [6]	2014	1	11month/ male	Left side	-	Excisional biopsy with electrocautery
Sanjeevlaller et al. [7]	2014	1	26 years /Male	Left side	Yes	Excision biopsy
Bhavna Gupta et al. [8]	2007	2	13year/ Female 2 ½ year/ Female	Left side Center of lip	Yes Yes	Excision biopsy Excision biopsy
B.N.Rangeeth et al. [9]	2010	1	9 year/ Female	Multiple lesion on left and right side	Yes	Excision biopsy
B. Senthikumar et al. [10]	2012	1	35 year/ Female	Left side	Yes	Marsupialization
S. Ashok Kumar et al. [11]	2013	1	8 months/ Male	Left side	Yes (improper feeding bottle)	Surgical excision
RajashreeGanguly et al. [12]	2015	1	34 year/ male	Left side	-	Diode laser
Nallasivam et al. [13]	2015	1	9 years/ Male	Left side	Yes	Surgical excision
Mauricio Marcushamer et al. [14]	1997	6	32-8 years/ 3 Female,3 Male	-	Yes	Cryosurgery
Kirtichawla et al. 15	2010	1	22 year/ male	-	-	Er,Cr:YSGG Laser

Author	Year	Number of cases	Age/Sex	Position/ Location on lower lip	History of trauma	Treatment
Umberto Romeo et al. [16]	2013	3	14 year/ male 13 year/ Male 12 year/ male	Left side - Right side	Yes	Er,Cr:YSGG laser 2780 nm Diode laser 808 nm KTP 532 nm
Denise Tostes Oliverira et al. [17]	1993	112	-	60% were lower lip	-	-
HamedMortazavi [18]	2014	1	26 years/ Male	Right side	Lip biting/ yes	Micromarsupialization and intralesional injection of dexamethasone phosphate
Dr. RiniGangwalBadjatia et al. [19]	2014	1	8 years/ female	Left side	Yes	Surgical excision

planned, and the convention scalpel method was considered as the treatment of choice for the patient. In the literature, age of the reported patients ranged from 8 months to 35 years, making a peak in the second decade with very little incidence amongst the males. Most of the cases were found to have left lower lip mucocele and the reason for the occurrence of mucocele on the left side is not known. The most common etiological factor for the occurrence of mucocele was found to be traumatic injuries and various treatment modalities such as excisional biopsy, laser, cryosurgery, intralesional injections, Marsupialization, Micro marsupialization. Harrison [20], in an analysis of 400 cases noticed that extravasation cysts occur more frequently in the younger patients usually during the second–third decade and mostly in the lower lip; whereas retention cysts occur most often in older patients and elsewhere than the lower lip. Actually, differentiation of ‘mucous-extravasation phenomena’ from ‘mucous-retention cysts’ is neither necessary nor important, since they are treated of choice and prognosis is the same for both type of cases [21]. The treatment of choice for mucocele is surgical excision of the lesion. Because the majority of mucocèles are small in diameter often less than 10 mm, complete excision with the associated glandular components is preferred. Recurrence of these lesions is uncommon if completely excised [22].

#### 4. CONCLUSION

Mucocele is the most common benign self-limiting condition diagnosed based on clinical and histological examination. Its recurrence rate

is rare if the involved accessory salivary glands are removed. It is commonly seen in young males. Trauma was the most common cause and majority of these lesions are seen in the lower lip. These lesions can be prevented by early interception of oral habits in children. Because of the possibility that a lesion in this location might be a tumor, a definitive diagnosis must be made after excision. As mucocele is painless, dentists are the one who notice these types of lesions and diagnose. Care must be taken to eliminate the causative agent along with the surgical excision of the lesion.

#### ETHICAL APPROVAL

The patient was informed about the procedure and consent was taken by the patient before starting the procedure.

#### COMPETING INTERESTS

Authors have declared that no competing interests exist.

#### REFERENCES

1. Oral pathology; Clinical Pathologic Correlations 5<sup>th</sup> edition, Regezi, Sciubba, Jordan.
2. Seifert G, Donath K, Von Gumberz C. Mucoceles of the minor salivary glands. Extravasation mucoceles (mucus granulomas) and retention mucoceles (mucus retention cysts). 1981;29(6):179-91.

3. Yamasoba T, Tayama N, Syoji M, Fukuta M. Clinicostatistical study of lower lip mucoceles. *Head Neck*. 1990;12:316-20.
4. Bagan Sebastian JV, Silvestre Donat FJ, Penarrocha Diago M, Milián Masanet MA. Clinico-pathological study of oral mucoceles. *Av Odontoestomatol*. 1990; 6:389-91,394-5.
5. Andiran N, Sarıkayalar F. Unal of, baydar de, ozaydin e. Mucocele of the anterior lingual salivary glands: From extravasation to an alarming mass with a benign course. *Int J Pediatr Otorhinolaryngol*. 2001; 61:143-7.
6. Neha Bhargava, Prateek Agarwal, Nitin Sharma, Mayank Agrawal, Mohsin Sidiq, Pooja Narain. An unusual presentation of oral mucocele in infant and its review. Hindawi Publishing Corporation, *Case Reports in Dentistry*; 2014.
7. Sanjeev Laller, Ravinder Singh Saini, Mamta Malik, Rahul Jain. An appraisal of oral mucous extravasation cyst case with mini review. *Journal of Advanced Medical and Dental Sciences Research*. 2014;2:2.
8. Bhavna Gupta, Rajesh Aneundi, Sudha P, Mohit Gupta. Mucocele: Two case reports. *J Oral Health Comm Dent*. 2007;1(3):56-58.
9. Rangeeth BN, Joyson Moses, Veera Kishore Kumar Reddy. A rare presentation of mucocele and irritation fibroma of the lower lip. *Contemporary Clinical Dentistry*. 2010;1:2.
10. Senthilkumar B, Nazargi Mahabob M. Mucocele: An unusual presentation of the minor salivary gland lesion. *Journal of Pharmacy and Bioallied Sciences*. 2012;4:Supplement 2 - part 1.
11. Ashok Kumar S, Mahesh Ramakrishnan. Mucocele in lower lip as a result of improper use of feeding bottle: A case report. Hindawi Publishing Corporation *Case Reports in Dentistry*; 2013.
12. Rajashree Ganguly, Mun Mukherjee, Tamal Kanti Pal. Laser excision of a mucocele: A case report. *Journal of International Dental Clinical Research Organization*. 2015;7:2.
13. Nallasivam KU, Sudha BR. Oral mucocele: Review of literature and a case report. *Journal of Pharmacy and Bioallied Sciences*. 2015;7(Supplement 2).
14. Mauricio Marcushamer, David King, Norma S. Ruano. Cryosurgery in the management of mucoceles in children. *American Academy of Pediatric Dentistry*. 29;4:3997.
15. Kirti Chawlaa, Arundeeep Kaur Lambab, Farrukh Farazc, Shruti Tandond, Shipra Arorae, Manak Guptae. Treatment of lower lip mucocele with er,cr:ysgg laser – A case report. *J Oral Laser Applications*. 2010; 10:181–185.
16. Umberto Romeo, Gaspare Palaia, Gianluca Tenore, Alessandro Del Vecchio, Samir Nammour. Excision of oral mucocele by different wavelength lasers. *Indian Journal of Dental Research*. 2013;24(2).
17. Denise Tostes Oliveira, Alberto Consolaro, Francisco Jose Guimaraes Freitas. Histopathological spectrum of 112 cases of mucocele. *Braz Dent*. 1993;4(1):29-36.
18. Hamed Mortazavi, Maryam Baharvand, Somayeh Alirezaei, Robab Noor-Mohammadi. Combination therapy in a large lower lip mucocele: A non-invasive recommended technique. 2014;5:3.
19. Rini Gangwal Badjatia, Sourabhbadjatia, Vinayakumar Kulkarni, Divya S. Sharma. Oral mucocele: A case report. *NJDSR* 2014;2:1.
20. Harrison JD. Salivary mucoceles. *Oral Surg*. 1975;39:268-278.
21. Bodner L, Tal H. Salivary gland cysts of the oral cavity: Clinical observation and surgical management. *compendium continuing educ. Dent*. 1991;12:150–154.
22. Nesibe Andiran, Fikriye sarıkayalar, Oymer Faruk Uvna, Dilek Ertoy Baydar. Eda ov zaydin mucocele of the anterior lingual salivary glands: From extravasation to an alarming mass with a benign course. *International Journal of Pediatric Otorhinolaryngology*. 2001;61:143–147.

© 2016 Dayashankar et al.; This is an Open Access article distributed under the terms of the Creative Commons Attribution License (<http://creativecommons.org/licenses/by/4.0>), which permits unrestricted use, distribution, and reproduction in any medium, provided the original work is properly cited.

*Peer-review history:*

*The peer review history for this paper can be accessed here:*  
<http://sciencedomain.org/review-history/16057>