

Cytodiagnosis of Warthin's Tumour in Submandibular Salivary Gland- A Rare Case Report

POORNIMA PANDEY¹, ARVIND BHAKTE²

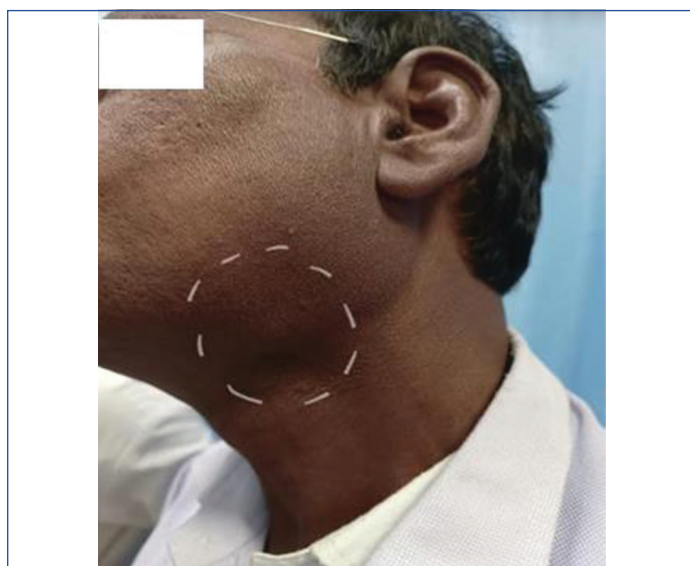ABSTRACT

The cytodiagnosis of Warthin's tumour by Fine Needle Aspiration Cytology (FNAC) in the submandibular salivary gland in literature is sparsely reported. Constituting an outnumbered portion of salivary gland neoplasms, it is a monomorphic adenoma that mainly arises in parotid gland. The occurrence of it in minor salivary gland and submandibular salivary gland is minuscule. Therefore, the confrontation of cytomorphological features of Warthin's tumour poses the problem of interpretation. In spite of the fact that, Warthin's tumour dispense as a clinically benign, slow growing and asymptomatic lesion with minimal rate of recurrence, nevertheless this entity is contemplated peculiar because of its unknown origin and cytomorphological appearance. The cytopathological smears prepared depict papillaroid sheets of oncocytoid cells which entails careful distinction for its diagnosis. The present article outlined such rare case of Warthin's tumour for its cytomorphological character and its clinical finding for its medical rarity. Here by, authors describe a case of Warthin's tumour of two years duration in a 44-year-old male patient in the right submandibular gland. The clinical examination had revealed it to be a mass of 4x4 cm lying just below the angle of mandible, with solid as well as cystic components. As a part of presurgical diagnosis the patient was referred for FNAC. The smears were prepared from both components of swelling and the peculiar case was pondered over for various concepts regarding its clinicopathological features with main emphasis on cytomorphology.

Keywords: Cytology, Fine needle aspiration cytology, Oncocytoid cells

CASE REPORT

A 44-year-old male presented to surgery outpatient department with a long standing swelling present on the right-side in the upper neck. The swelling was present for past two years and was gradually increasing in the size. The swelling was painless and was causing bulging of submandibular area on right-side. The clinical examination revealed it to be a mass of 4x4 cm lying just below angle and ramus of mandible and was in close approximation to the anterior border of sternocleidomastoid. The skin over swelling was normal. There were no scars, sinuses, fistula and discharge from the swelling. The swelling was non pulsatile. On further palpation the swelling was solid, cystic and without local rise in temperature. The swelling was not fixed to overlying or underlying structures and was unrelated to the activity of deglutition. The trans-illumination test of the swelling was partially positive [Table/Fig-1].



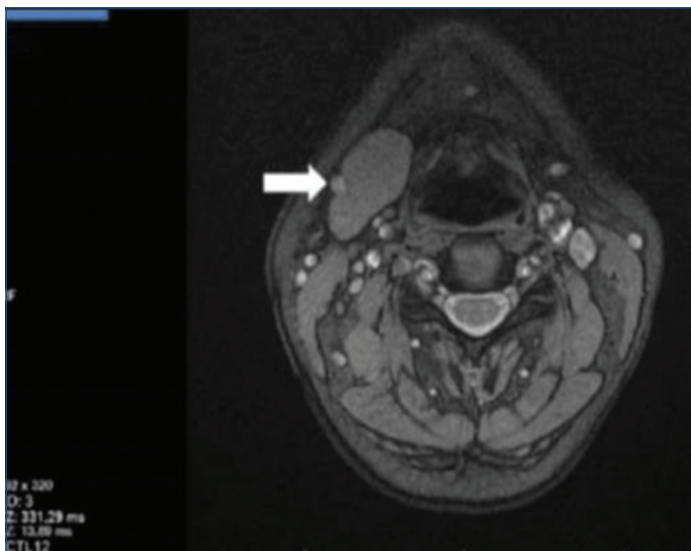
[Table/Fig-1]: Clinical photograph of submandibular swelling of the case.

The inspection of the oral cavity revealed no obvious abnormality. The swelling was palpable through the oral cavity by finger test. The swelling upon the evaluation had the differential clinical diagnosis of submandibular large lymphadenopathy, pleomorphic adenoma in submandibular salivary gland and chronic sialadenitis of submandibular salivary gland.

The patient was referred for FNAC for preoperative diagnosis. Meanwhile patient underwent haematological assessment of Complete Blood Count (CBC), Erythrocyte Sedimentation Rate (ESR) and C-Reactive Protein (CRP). These investigations revealed a normal values. The patient was also sent for the radioimaging investigations, that is Magnetic Resonance Imaging (MRI) neck. MRI was done which revealed increased capacity of the submandibular gland due to portrayed submandibular lesion showing T1 hypointensity and increased magnification compared to the proportional non affected parenchyma and T2 signals were compared to the normal gland, as shown in [Table/Fig-2]. For this peculiar entity, certain probable imaging differentials which can be scrutinised are- adenoid cystic carcinoma, mucoepidermoid carcinoma, pleomorphic adenoma and parotid nodal metastasis.

The FNAC was carried out by standard procedures using 24 SW needle under the sonography guidance. The sonography revealed 5x5 cm sized nodular swelling in the right submandibular area which was well circumscribed. The echos were solid, cystic without obvious calcification. Two areas were chosen for FNAC, the area that was solid on sonography and the cystic one. The aspiration from the cystic area was brown yellow in colour and turbid. The smears were fixed to undergo stains of haematoxylin and eosin, Papanicolaou, and May Grunwald-Giemsa by standard steps of staining procedure.

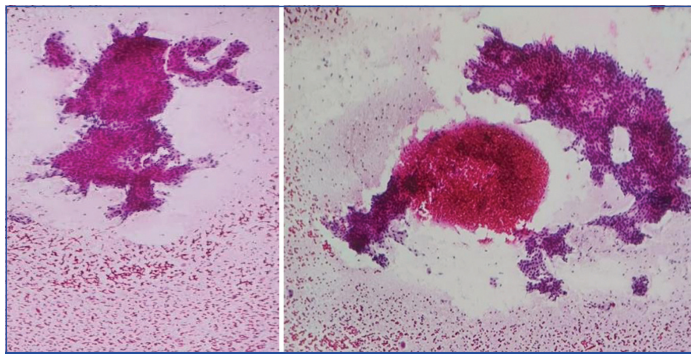
The smears were moderately cellular and showed dual population of cell types. There were oncocytoid cells placed in sheets, pseudopapillaroid groups and rarely isolated groups of three to four cells. These cells had a granular thicker cytoplasm and carried a little enlarged benign nuclei and a little increase in chromasia. These cells lacked nuclear



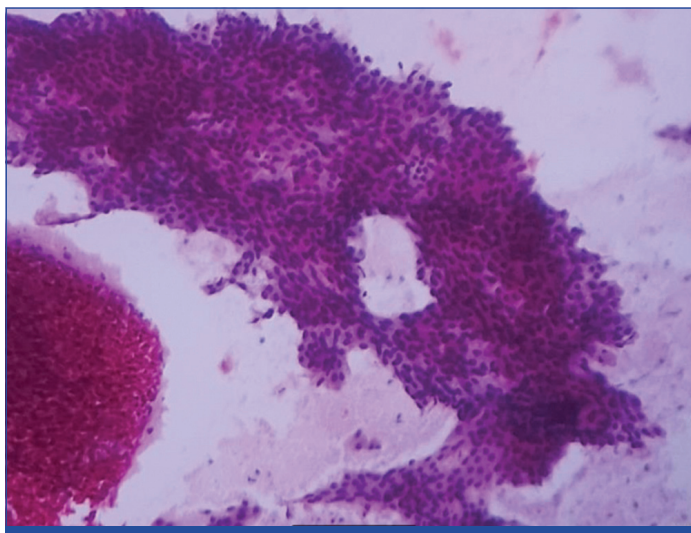
[Table/Fig-2]: MRI neck showing T1 image with hypointensity and increased volume of submandibular salivary gland.

pleomorphism. The other population of the cell that accompanied the above described cell was of lymphoid cells. The lymphoid cells were polymorphous in character and were seen diffused as well as rarely in nodules. A few places showed the lymphoid cell nodules in close proximity with oncocytoid cell population. Background showed a few cyst macrophages, scattered debris and crenated red blood cells admixed with serous material [Table/Fig-3-5].

The diagnosis of benign lymphoepithelial lesion was made which was further categorised to the lesion of Warthin's tumour based on cytomorphology. The tumour underwent the surgical excision, the

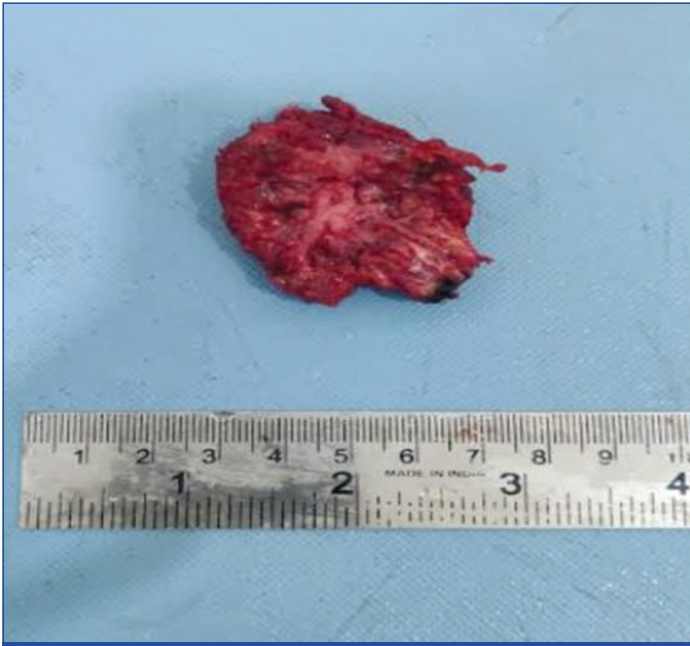


[Table/Fig-3]: Photomicrograph (Cytology) Warthin's tumour- depicts papillaroid sheets of oncocytoid cells in background of isolated lymphocytes (Papanicolaou stain- 40x). **[Table/Fig-4]:** Photomicrograph (Cytology)- Warthin's tumour- displays papillaroid structure of oncocytoid cells in proximity with lymphoid cell cluster and background lymphocyte cells (Papanicolaou stain- 10x). (Images from left to right).



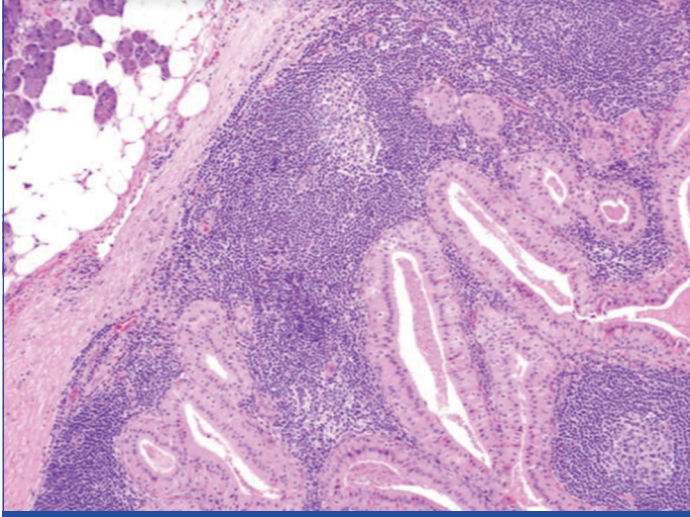
[Table/Fig-5]: Photomicrograph (Cytology)- Warthin's tumour-show the benign character of the nuclei of oncocytic cells and background macrophages and granular debris (Papanicolaou stain- 40x).

gross showed cystic as well as small part of solid areas on the cut-section is shown in [Table/Fig-6].



[Table/Fig-6]: Warthin's tumour-Gross appearance of excised tumour showing the cystic areas on cut section. The tumour appears to be well-circumscribed.

The histopathology slide picture illustrated low power view of Warthin's tumour showing papillary structures lined by two layered oncocytoid epithelium made up of tall columnar cells and a discontinuous layer of basally located cuboidal cells. The stroma depicted dense lymphocytic infiltrate with the germinal centre formation. Histomorphologically features were consistent with the diagnosis of Warthin's tumour, as can be seen in [Table/Fig-7]. As the histomorphology was classic, no further immunohistochemical assessment was performed.



[Table/Fig-7]: Photomicrograph (Histopathology)- Warthin's tumour- shows papillary structures lined by two layered oncocytoid epithelium and stroma showing lymphocytic infiltrate (H&E 10x).

The subject of the present case scenario was managed with a team of professional otolaryngologist, maxillofacial surgeon, radiologist and pathologist. As a part of optimal treatment superficial parotidectomy was performed to reduce the recurrence of the entity. After a close follow-up for about one week the patient was able to carry on his day to day life activities thus was discharged with intimidation of his visit to the healthcare centre 15 days postsurgery.

DISCUSSION

The Warthin's tumour constitute about 4-15% of all major salivary neoplasms and is the second most common benign salivary

tumour succeeding pleomorphic adenoma. Warthin's tumour typically presents in parotid gland swelling which is solid cystic in nature. Submandibular salivary gland and minor salivary gland rarely harbours Warthin's tumour [1-3]. Clinically, it presents as a painless, soft, smooth and fluctuant swelling which is unilateral frequently but can be present bilaterally. Warthin's tumour also been referred as papillary lymphomatous cystadenoma is unusual for its histology as it contains oncocyctic proliferative component as well as proliferative component of the reactive lymphoid cells [4]. The scholarly articles describe its diagnosis by FNAC especially when it is located in the parotid. However, the Warthin's tumour of submandibular salivary gland and minor salivary gland has been infrequently reported and infrequently being diagnosed on FNAC [5,6].

The literary texts describing Warthin's tumour within minor salivary gland and submandibular salivary gland mostly are in form of case reports [4-7]. But there are also a few case reports which although describes the location of Warthin's tumour in minor salivary glands and submandibular salivary gland however, their diagnosis were made on the histology of excised specimens and not on FNAC [7]. There is no consensus for histogenesis of Warthin's tumour however, the tumour has been suggested to arise in a glandular cells which latter undergoes cystic change with papillary in fronds of oncocyctic cells, surrounded by basal cells. The polymorphous lymphoid cells referred as lymphoid stroma is a result of neoplastic epithelial component of Warthin's tumour [8].

The immunostain reactions within the tissue of the Warthin's tumour revealed the predominance of the B cells specifically marked by CD-20 immunopositivity. The lymphoid cells also are known to express markers of T cells as well as natural killer cells [8,9]. As the occurrence of the Warthin's tumour in submandibular salivary gland and minor salivary gland is rare. Therefore, the diagnostic encounter of this entity on FNAC is novel and often perplexing. The cytomorphology of Warthin's tumour are described previously in a few case reports in literature [10-12]. Study of Köybaşıoğlu FF et al., analysed Warthin's tumour for the frequency of cytomorphological features in depth in the parotid gland and a case of submandibular salivary gland and concluded that 83% of the aspirates contains oncocyctic cell layer and 92% of the aspirate contain lymphoid cells [10]. The other cytomorphological features that were encountered in the smears by the authors' were of granular debris in the background, mucoid material, macrophages, neutrophils, mast cells and squamous like cells.

The case report of Radhakrishnan R et al., and Bajaj P et al., reported similar diagnostic cytomorphology for Warthin's tumour [9,13]. The cytomorphological features observed at FNAC of present case report was in agreement to the diagnostic weightage of oncocyctic cells in a pseudopapillary groups and marked population of the lymphoid cells in diagnosis of papillary cystadenoma lymphomatousum. Few of the surgeons from clinical perspective deal upon this distinctive entity using optimal treatment with preference to superficial parotidectomy to avoid the rupture of tumour capsule whereas few of them choose local resection with surrounding tissue [14]. In spite of much exploration, the origin of Warthin's tumour has not been fully established. Some of the writers emphasised that the benign neoplasm arise as a result of some tumourigenic effect on epithelial inclusions located in lymph nodes adjacent to the parotid gland. Other aetiological factors which were discussed encompassed of Epstein Barr virus infection, tobacco, autoimmune disease and chronic inflammation [15].

Warthin's tumour is rare in submandibular salivary gland as could be traced from literature search [Table/Fig-8]. The present case of Warthin's tumour in submandibular salivary gland therefore becomes a rare report which was diagnosed by FNAC and confirmed on histology on excised specimen.

S. no.	Authors	Publication	Place of study	No. of cases studied	Findings of case
1.	Bhosle S et al., [15]	2015	India	Case of 50-year-old male	Case revealed that commonly Warthin's tumour occurs in parotid gland but there can be incidences of accompanied occurrence of tuberculosis infection within a Warthin's tumour of submandibular salivary gland.
2.	Present case	2023	India	44-year-old male	Long standing swelling present on the right-side in the upper neck.

[Table/Fig-8]: Published case on Warthin's tumour.

CONCLUSION(S)

The current work presented the case of painless swelling of submandibular gland in a 44-year-old male. The swelling had slowly and asymptotically grown in two years duration and was located at an unusual site other than the characteristic area of Warthin's tumour. The final diagnosis was achieved mainly after the cytomorphological examination which depicted the oncocyctic cells in sheets with papillary configurations co-existing with polymorphous lymphoid cells in aspirates of FNAC in submandibular salivary gland swelling should arouse the suspicion of Warthin's tumour, especially in absence of normal salivary ductal and acinic cells. The antecedent diagnosis of this rare tumour in submandibular gland prior to surgery would help the surgeons in choosing the type of surgery and its limitations and the physicians to understand its pathophysiology.

REFERENCES

- [1] Pons Vicente O, AlmendrosMarqués N, BeriniAytés L, Gay Escoda C. Minor salivary gland tumours: A clinicopathological study of 18 cases. *Med Oral Patol Oral Cir Bucal*. 2008;13(9):E582-88. PMID: 18758404.
- [2] Faur A, Lazăr E, Cornianu M, Dema A, Vidita CG, Gălușcan A. Warthin tumour: A curious entity--case reports and review of literature. *Rom J Morphol Embryol*. 2009;50(2):269-73. Available at: <https://pubmed.ncbi.nlm.nih.gov/19434322/>.
- [3] Bradley PJ, McGurk M. Incidence of salivary gland neoplasms in a defined UK population. *Br J Oral Maxillofac Surg*. 2013;51(5):399. Available at: <https://doi.org/10.1016/j.bjoms.2012.10.002>.
- [4] Párraga-Linares L, Aguirre-Urizar JM, Berini-Aytés L, Gay-Escoda C. Papillary cystadenomalymphomatousum (Warthin-like) of minor salivary glands. *Med Oral Patol Oral Cirugia Bucal*. 2009;14(11):e597-600. Doi: 10.4317/medoral.14.e597.
- [5] Wang D, Li Y, He H, Liu L, Wu L, He Z. Intraoral minor salivary gland tumours in a Chinese population: A retrospective study on 737 cases. *Oral Surg Oral Med Oral Pathol Oral Radiol Endod*. 2007;104(1):94-100. Doi: 10.1016/j.tripleo.2006.07.012.
- [6] Diaz-Segarra N, Young LK, Levin K, Rafferty W, Brody J, Koshkareva Y. Warthin tumour of the oropharyngeal minor salivary gland. *SAGE Open Med Case Rep*. 2018;6(2):45-134. Doi: 10.1177/2050313X18818712.
- [7] Iwai T, Baba J, Murata S, Mitsudo K, Maegawa J, Nagahama K, et al. Warthin tumour arising from the minor salivary gland. *J Craniofac Surg*. 2012;23(5):e374-76. Doi: 10.1097/SCS.0b013e318254359f.
- [8] Kuzenko YV, Romanuk AM, Dyachenko OO, Hudymenko O. Pathogenesis of Warthin's tumours. *Interv Med Appl Sci*. 2016;8(2):41-48. Doi: 10.1556/1646.8.2016.2.2.
- [9] Radhakrishnan R, Rehani S, Bishen KA, Sagari S. Warthin's Tumour: A case report and review on pathogenesis and its histological subtypes. *J Clin Diagn Res JCDR*. 2014;8(9):ZD37-40. Doi: 10.7860/JCDR/2014/8503.4908.
- [10] Köybaşıoğlu FF, Önal B, Han Ü, Adabağ A, Şahpaz A. Cytomorphological findings in diagnosis of Warthin tumour. *Turk J Med Sci*. 2020;50(1):148-54. Doi: 10.3906/sag-1901-215.
- [11] Islam SR, Boksh Z. A rare presentation of Warthin's Tumour in the submandibular gland of a 7-year-old boy. *Ann Clin Oncol*. 2020;3(1):02-02. Doi: 10.31487/J.ACO.2020.01.04.
- [12] Shishegar M, Ashraf MJ, Azarpira N, Khademi B, Hashemi B, Ashrafi A. Salivary gland tumours in maxillofacial region: A retrospective study of 130 cases in a southern Iranian population. *Pathol Res Int*. 2011;2011(1):12-18. Doi: 10.4061/2011/934350.
- [13] Bajaj P, Garg D, Sabharwal R, Gautam S. Fine needle aspiration cytology in Warthin's tumour: A diagnostic tool. *Diagn Pathol Open*. 2015;1(1):102. Doi: 10.4172/2476-2024.1000102.

- [14] Maiorano E, Lo Muzio L, Favia G, Piattelli A. Warthin's tumour: A study of 78 cases with emphasis on bilaterality, multifocality and association with other malignancies. *Oral Oncol.* 2002;38(1):35-40.
- [15] Bhosle S, Warad B, Nair SG. Coexistence of tuberculosis with warthin tumour of submandibular salivary gland: A case report. *Int J Curr Res Rev.* 2015;7:34-37.

PARTICULARS OF CONTRIBUTORS:

1. Junior Resident, Department of Pathology, Jawaharlal Nehru Medical College, Datta Meghe Institute of Higher Education and Research, Deemed University, Sawangi (Meghe), Wardha, Maharashtra, India.
2. Director Professor, Department of Pathology, Jawaharlal Nehru Medical College, Datta Meghe Institute of Higher Education and Research, Deemed University, Sawangi (Meghe), Wardha, Maharashtra, India.

NAME, ADDRESS, E-MAIL ID OF THE CORRESPONDING AUTHOR:

Dr. Poornima Pandey,
Junior Resident, Department of Pathology, Jawaharlal Nehru Medical College,
Datta Meghe Institute of Higher Education and Research, Deemed University,
Sawangi (Meghe), Wardha-442001, Maharashtra, India.
E-mail: poornima.pan22@gmail.com

PLAGIARISM CHECKING METHODS: [\[Jain H et al.\]](#)

- Plagiarism X-checker: Feb 15, 2023
- Manual Googling: Mar 15, 2023
- iThenticate Software: Apr 01, 2023 (3%)

ETYMOLOGY: Author Origin**AUTHOR DECLARATION:**

- Financial or Other Competing Interests: None
- Was informed consent obtained from the subjects involved in the study? Yes
- For any images presented appropriate consent has been obtained from the subjects. Yes

Date of Submission: **Feb 14, 2023**Date of Peer Review: **Apr 03, 2023**Date of Acceptance: **Apr 21, 2023**Date of Publishing: **May 01, 2023**