

Bladder neck incompetence at posterior urethroplasty

Mamdouh M. Koraitim

To cite this article: Mamdouh M. Koraitim (2015) Bladder neck incompetence at posterior urethroplasty, Arab Journal of Urology, 13:1, 64-67, DOI: [10.1016/j.aju.2015.02.004](https://doi.org/10.1016/j.aju.2015.02.004)

To link to this article: <https://doi.org/10.1016/j.aju.2015.02.004>



© 2015 Arab Association of Urology



Published online: 05 Apr 2019.



Submit your article to this journal [↗](#)




Article views: 304



View related articles [↗](#)



View Crossmark data [↗](#)



PFUI-RELATED COMPLICATIONS
MINI-REVIEW

Bladder neck incompetence at posterior urethroplasty



Mamdouh M. Koraitim

Department of Urology, Faculty of Medicine, University of Alexandria, Egypt

Received 9 February 2015, Accepted 14 February 2015

Available online 7 March 2015

KEYWORDS

Bladder neck;
Incompetence;
Urethroplasty

ABBREVIATIONS

BN, bladder neck;
PFUI, pelvic fracture
urethral injury

Abstract The finding of an incompetent bladder neck (BN) at the time of posterior urethroplasty will necessarily exacerbate the already difficult situation. In such cases the aim of the treatment is not only to restore urethral continuity by end-to-end urethral anastomosis, but also to restore the function of the BN to maintain urinary continence. Fortunately, the incidence of incompetence of the BN at posterior urethroplasty is uncommon, usually $\approx 4.5\%$. It seems that pelvic fracture-related BN injuries, in contrast to urethral injuries which result from a shearing force, are due to direct injury by the sharp edge of the fractured and displaced pubic bone. The risk of injuries to the BN is greater in children, in patients with a fracture involving both superior and inferior pubic rami on the same side, and in those managed initially by primary realignment. An incompetent BN is suspected by finding an open rectangular BN on cystography, and a fixedly open BN on suprapubic cystoscopy. An incompetent BN can be treated either subsequent to or concomitant with the urethral repair, according to whether a perineal or a perineo-abdominal urethroplasty is used, respectively. Several options have been reported to treat pelvic fracture-related BN incompetence, including reconstructing the BN, forming a new sphincter by tubularisation of a rectangular flap of the anterior bladder wall, and mechanical occlusion by an artificial sphincter or collagen injection. Reconstruction of the BN by the Young-Dees-Leadbetter** procedure probably provides the most successful results. © 2015 Arab Association of Urology. Production and hosting by Elsevier B.V. This is an open access article under the CC BY-NC-ND license (<http://creativecommons.org/licenses/by-nc-nd/4.0/>).

Peer review under responsibility of Arab Association of Urology.



Production and hosting by Elsevier

Introduction

The current concept is that continence of urine in patients having a pelvic fracture urethral injury

(PFUI) repaired is maintained mainly by the bladder neck (BN), as the external sphincter is usually damaged by the initial trauma or subsequent management [1–3]. Hence, the association of an incompetent BN with a PFUI is one of the most challenging management problems in urology. In such cases the aim of treatment is not only to achieve a free urethral passage by restoring urethral continuity, but also to maintain urinary continence by restoring sphincteric function of the BN. Fortunately, this association is uncommon; it has been estimated that only $\approx 4.5\%$ of patients having a PFUI repaired have an incompetent BN [4].

Causes and risk factors

It appears that pelvic fracture-related BN incompetence, in contrast to urethral injuries which result from a shearing force, is due to direct injury by the sharp edge of the fractured and displaced pubic bone [4]. Some factors have been reported to influence the risk of BN injury at the time of pelvic trauma, and include the patient's age, pattern of pelvic fracture, and type of initial management of the urethral injury [4–6]. In a previous study, it was found that about two-thirds (67%) of patients having pelvic-fracture related BN injury were boys aged < 15 years [4]. This age-linked preponderance of BN injury is probably related to the small prostates in boys that provide less protection against injury by bone fragments than in adults.

Also, the risk of BN injury might be influenced by the pattern of pelvic fracture. Almost all patients with pelvic fracture-related BN incompetence had fractures of both the superior and inferior pubic rami on the same side [4].

Furthermore, the risk of BN injury might be influenced by the type of initial management of the urethral injury. It has been reported that patients with BN incompetence had more often initially been managed by primary realignment than had patients with an intact BN (75% vs. 33%, $P < 0.05$) [4,5].

The diagnosis of BN incompetence

The diagnosis of BN incompetence in patients undergoing repair of a PFUI is not always easy, largely because these patients are usually dependent on a suprapubic catheter and no urine can be passed or leaked via the urethra. Thus, the documentation of urinary incontinence is not possible subjectively or objectively. In fact, the diagnosis in these patients has been entirely dependent on the finding of an open BN on the resting cystogram and/or a fixedly open BN on suprapubic cystoscopy. However, this is not always true. While an open BN in these patients might be the result of an intrinsic anatomical damage leading to its dysfunction, it might also be the result of normal funnelling of the BN stimulated by a detrusor contraction. This contraction can be voluntary, as during an attempt at voiding, or an involuntary uninhibited contraction because of the

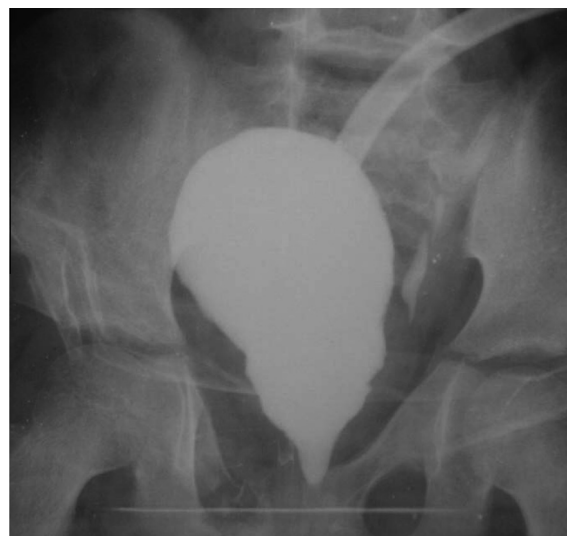

Figure 1 A preoperative cystogram at rest shows funnelling of the triangular BN. The patient was completely continent after perineal urethroplasty.

presence of a suprapubic catheter [7]. It is not always easy to differentiate between normal physiological funnelling of the BN and an open incompetent BN by cystography without a synchronous urodynamic study [8].

Nevertheless, Iselin and Webster [1] found that the BN opening as measured on the cystogram is significantly longer in dysfunctional than in functional cases, and suggested that this might help in the differentiation. Also, in a previous study we found that the average length of the BN opening was greater in dysfunctional than in functional cases (1.2 vs. 0.95 cm, respectively), but the difference was not statistically significant ($P > 0.05$) [4]. More importantly, the shape of the functional BN opening on the cystogram differs from that of dysfunctional cases.

In competent cases, there is always funnelling of the BN, which appears triangular, with the right and left borders converging distally (Fig. 1). This funnelling of the BN is probably due to contraction of the bladder musculature pulling on the urethral wall [9]. In incompetent cases, on the other hand, BN opening is rectangular in shape, with the right and left borders nearly parallel to each other (Fig. 2) [4]. It appears that this configuration is due to passive filling of the damaged BN from the bladder with contrast medium, which pushes its walls equally apart. This difference in shape of the BN opening might be used to predict the chance of urinary continence or incontinence after urethral reconstruction, and hence indicates the need or otherwise for a concomitant BN repair.

The timing of treatment

The timing of correction of BN incompetence in patients undergoing repair of a PFUI continues to be a

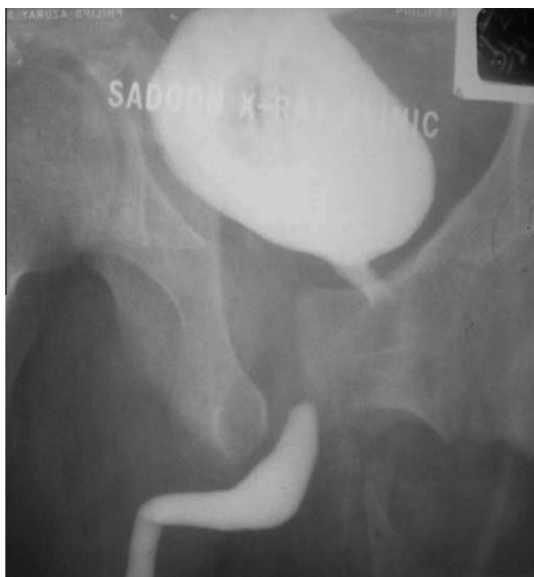

Figure 2 A preoperative combined antegrade and retrograde cysto-urethrogram shows an open rectangular BN with almost parallel right and left borders. The patient was incontinent after a successful perineal urethroplasty.

controversial subject. Several investigators hold that BN incompetence might be treated concomitantly with the urethral repair [10]. Others prefer to manage the urethral injury and BN incompetence sequentially [1].

Thus, correction of the BN can be postponed until after urethral repair when patients can void urethrally and incontinence can be confirmed subjectively and objectively. Logically, when a patient has had a successful perineal urethroplasty, BN repair can be deferred for another session, but in patients undergoing a perineo-abdominal urethroplasty the BN repair can be concomitant in the same session.

Treatment options

Several options have been described to treat pelvic fracture-related BN incompetence, including reconstructing the BN, forming a new sphincter by tubularisation of a rectangular flap of the anterior bladder wall, and mechanical occlusion by an artificial sphincter or collagen injection. However, there have been only a few reports of mechanical occlusion in these cases, and with unsatisfactory results [1,11]. In contrast, the superiority of the Young-Dees-Leadbetter operation as a method for BN reconstruction has been documented by several investigators [4,12].

This might be attributed to the inclusion of a large segment of the strong trigonal muscle in the reconstruction of the BN. It is not generally remembered that as early as 1897 the vesical trigone was known as the sphincter trigonalis, as it forms the dorsal and thicker

component of the internal sphincter [13]. Also, this was later confirmed by the three-dimensional reconstruction of the human pelvis, which showed that the trigone migrates at the BN anteriorly and proceeds downwards as the anterior fibromuscular stroma of the prostate [14]. Also, some authors reconstruct the BN by excision of the scarred segment of the BN in a wedge-like fashion and closure of the clean margins in layers, with or without an overlapping technique to reduce the lumen of the BN and augment its sphincteric function. The success rate was reported to be good in some series and less satisfactory in others [1,11,15].

The creation of a new sphincter from the anterior bladder wall was introduced by Flocks and Culp in 1953, as a procedure after radical prostatectomy [16]. However, this procedure was popularised in 1981 by Tanagho [17], who used it in 56 patients with total urinary incontinence. Notably, the anterior bladder wall proximal to the vesical orifice is characterised by a heavy condensation of circular muscle fibres [18]. A rectangular flap formed from this part and then tubularised will conceptually include these circular muscle fibres to provide an adequate sphincter function. This is the rationale of the Tanagho bladder tube. Also, a variant of the Tanagho bladder tube has been reported to provide not only a new sphincter but also extra length to achieve a tension-free urethral anastomosis [19].

Conflict of interest

None.

Source of funding

None.

References

- [1] Iselin CE, Webster GD. The significance of the open bladder neck associated with pelvic fracture urethral distraction defects. *J Urol* 1999;**162**:347–51.
- [2] Koraitim MM, Sabry A. Mechanism of continence after transpubic urethroplasty. *Urology* 1986;**27**:187–90.
- [3] Koraitim MM, Atta MA, Fattah GA, Ismail HR. Mechanism of continence after repair of post-traumatic posterior urethral strictures. *Urology* 2003;**61**:287–90.
- [4] Koraitim MM. Assessment and management of an open bladder neck at posterior urethroplasty. *Urology* 2010;**76**:476–9.
- [5] Devine CJ, Jordan GH, Devine PC. Primary realignment of the disrupted prostatomembranous urethra. *Urol Clin North Am* 1989;**16**:291–5.
- [6] Turner-Warwick R. Prevention of complications resulting from pelvic fracture urethral injuries-and from their surgical management. *Urol Clin North Am* 1989;**16**:335–58.
- [7] Turner-Warwick R. Observations on the function and dysfunction of the sphincter and detrusor mechanisms. *Urol Clin North Am* 1979;**6**:13–30.
- [8] Whiteside G, Bates P. Synchronous video pressure-flow cystourethrography. *Urolog Clin North Am* 1979;**6**:89–93.

- [9] McGuire E. Urethral sphincter mechanisms. *Urol Clin North Am* 1979;**6**:39–49.
- [10] Turner-Warwick R. Urethral stricture surgery *Current operative surgery: urology*. London: Bailliere Tindall; 1988. p. 160–218.
- [11] Mundy AR, Andrich DE. Pelvic fracture-related injuries of the bladder neck and prostate: their nature, cause and management. *BJU Int* 2010;**105**:1302–8.
- [12] Kropp KA. Bladder neck reconstruction in children. *Urol Clin North Am* 1999;**26**:661–72.
- [13] Kalischer O. *Die Urogenitalmuskulatur Des Dames Mit Besonderer Berücksichtigung Harnblasenverschlusses*. Berlin: Verlag von S. Karger; 1900.
- [14] Brooks JD, Chao W, Kerr J. Male pelvic anatomy reconstructed from the visible human data set. *J Urol* 1998;**159**:868–72.
- [15] Turner-Warwick R. The anatomical basis of functional reconstruction of the urethra. In: Droller M, editor. *Surgical anatomy*. New York: Mosby Year Book; 1991 [chapter 61].
- [16] Flocks RH, Culp DA. A modification of technique for anastomosing membranous urethra and bladder neck following total prostatectomy. *J Urol* 1953;**69**:411.
- [17] Tanagho EA. Bladder neck reconstruction for total urinary incontinence. 10 years of experience. *J Urol* 1981;**125**:321.
- [18] Tanagho EA, Smith DR, Meyers FH, Fisher R. Mechanism of urinary continence. I. Technique for surgical correction of incontinence. *J Urol* 1969;**101**:305.
- [19] Koraitim M. Anterior bladder tube. 4 forms for incontinence of different etiology. *J Urol* 1985;**134**:269–73.