



Penetrating Stab Wounds of the Spine: Two Cases and Review of the Literature

**Fondop Joseph ^a, Atemkem Tsatedem Faustin ^a,
Banga Nkono Douglas ^a, F. Dikongue Dikongue ^a,
Amougou Boris ^a, A. C. Djam ^{a*}, Dogmo Arlette ^a,
Djientcheu Vincent de Paul ^b and Fuentes Stéphane ^c**

^a Faculty of Medicine and Pharmaceutical Sciences, University of Dschang, Cameroon.

^b Yaoundé General Hospital UY1, Cameroon.

^c Chu Timone Adulte, Aix Marseille University, France.

Authors' contributions

This work was carried out in collaboration among all authors. All authors read and approved the final manuscript.

Article Information

DOI: 10.9734/IBRR/2023/v14i4315

Open Peer Review History:

This journal follows the Advanced Open Peer Review policy. Identity of the Reviewers, Editor(s) and additional Reviewers, peer review comments, different versions of the manuscript, comments of the editors, etc are available here:

<https://www.sdiarticle5.com/review-history/102192>

Case Study

Received: 03/05/2023

Accepted: 05/07/2023

Published: 15/07/2023

ABSTRACT

Penetrating wounds of the spine caused by edged weapons are on the increase due to the growing insecurity, violence, availability and accessibility of these weapons, which are generally objects of everyday use (knife, axe, machete, screwdriver, bicycle spoke, scissors, garden fork, sickle and sharpened broom handle, etc.). These objects may be the cause of penetrating wounds responsible for neurological deficits with breaches of the dura mater, or they may be without neurological deficits due to the level of the weapon in the spine. We present two clinical cases of patients with penetrating knife wounds of the spine. One at cervical level with *pneumorrhagic* emphysema, spinal cord compression and pneumoencephaly, with neurological deficit who had

*Corresponding author: E-mail: djamalain@gmail.com;

a surgical intervention followed by physiotherapy and a progressive recovery, the other with a penetrating wound at L5 crossing the blade to the vertebral body without neurological deficit in whom the knife was extracted at the emergency department without secondary deficit. Penetrating wounds of the spine are caused by stab wounds, including knives. In particular, emphysema, diffuse pneumorrhagia and pneumocephalus are extremely rare in the same patient, this being due to the knife extraction technique. These lesions, associated with neurological deficit and cerebrospinal fluid (CSF) leakage, constitute a neurosurgical emergency.

Keywords: *Rachis; stabbing weapon; neurological deficit; pneumorrhache; pneumocephaly; surgery.*

1. INTRODUCTION

Trauma is said to be penetrating when the penetrating agent penetrates the skin covering to reach the underlying anatomical structures. The severity of the injury depends on the underlying lesions and the risks of haemorrhage and septicaemia [1]. This trauma may be caused by a firearm (FA) or an arm weapon (AB); the FA/AB ratio varies greatly from one society to another, depending on the accessibility and ubiquity of weapons. It is higher in the United States, England and South Africa, where the number of gun owners is high, and lower in France and sub-Saharan Africa [1-4]. In sub-Saharan Africa and Latin America, edged weapons (machetes, knives, etc.) are easily accessible and inexpensive tools that can be used to commit acts of interpersonal violence [2,5-7]. Some studies carried out in South Africa show that edged weapons are more prevalent than firearms.

A bladed weapon is one whose blade, moved solely by the human hand, pierces or slices. It is originally made of bright, shiny metal (as opposed to bronze), hence its name. Certain objects can become bladed weapons "through use" (screwdrivers, etc.). The injuries observed are related to the size and sharpness of the penetrating agent, the energy deployed and the anatomical elements involved [1,8]. The annual incidence of traumatic injuries to the spinal cord

is 35 patients per million. This is low compared with the thorax and abdomen, due to the defensive position assumed by the victim when attacked [7]. These are generally wounds caused by surprise or during escape.

2. CASE PRESENTATION

We report here two clinical cases of vertebro-medullary wounds, including a case of lumbar wound at L5 reaching the blade and the vertebral body, without neurological deficit and another case of cervical wound with neurological deficit, pneumocephalus and pneumorrhache, cervical and dorsal, by white weapons (knife).

Case 1: Male, aged 27, in the emergency department for treatment of a stab wound to the right paramedian lumbar region, the story goes back 34 hours before his admission, when the patient received a stab wound to the right lumbar paravertebral region from his brother, an ex-convict, after a discussion in which he was accused by his tormentor of having taken his money, the sum of 1000fca (1.5 euro /1.3dollar). The patient was admitted to a primary hospital and then evacuated to our facility. He is an anxious, pain-ridden patient with a knife surrounded by coagulated blood implanted in his back (Fig. 1); he has no neurological deficits, and is on anti-tetanus painkillers, anti-anxiety painkillers and antibiotics based on amoxicillin and clavulanic acid.

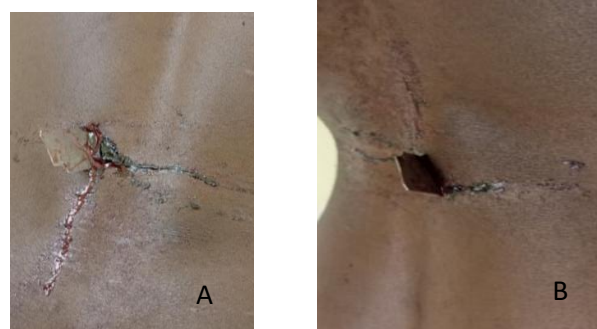


Fig. 1. Showing (A) and (B) a knife implanted in the back

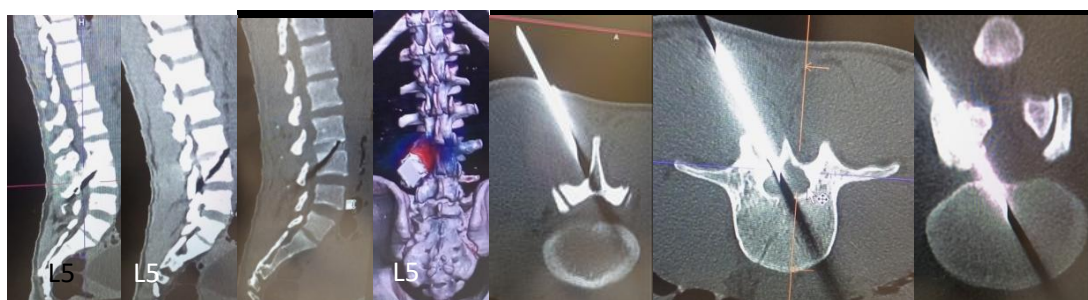


Fig. 2. CT scan showing lumbosacralization of S1 with a foreign body passing through the lamina and vertebral body of L5 following an oblique path from the skin to the vertebrae



Fig. 3. The knife blade extracted from the back with its entrance door

The lumbar CT scan showed lumbarization of S1 with a foreign body in an oblique trajectory crossing the vertebral lamina to implant itself in the body of L5 (Fig. 2).

In view of the patient's indigence, we performed asepsis and then extracted the knife, exceptionally staying in line with the axis of the knife, using local anaesthetic in the emergency department and closing the wound. No neurological or radicular deficits were observed. No leakage of CSF was noted at the 2nd dressing at D4, the patient was discharged to continue care until the removal of care at home (Fig. 3).

The patient was discharged at 3 days post-op to continue dressing at home.

Case 2: Young man, 18 years old, seen in emergency for paraparesis following a posterior cervical stab wound.

The story goes back to a day when the patient was the victim of an attack at dusk with a knife in

the posterior cervical region; he was received in a first hospital institution where the knife was before being referred to our institution.

On admission, the patient was very anxious and had a posterior cervical wound (Fig. 4), which he said was the entry point for the knife that had been extracted from his neck, leaving a clear liquid, rock water, which was very common in the CSF. He was tetra paretic with 3/5 watch strength in all 4 limbs, with sphincter hypotonia and no bladder globe [9].

A craniocervical CT scan showed subcutaneous cervical emphysema opposite the wound, intraductal pneumorrhoea and pneumocephalus (Fig. 5).

Craniocervical MRI shows cervical spinal cord compression associated with intracanal spinal peumorrhaphy and diffuse parenchymatous and ventricular malformation.

The indication for surgery was given and the patient was treated by compressive laminectomy and closure of the dural breach.

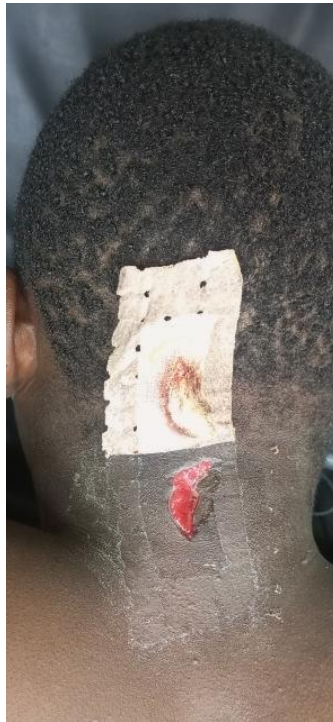

Fig. 4. Stab wound to the posterior cervical region

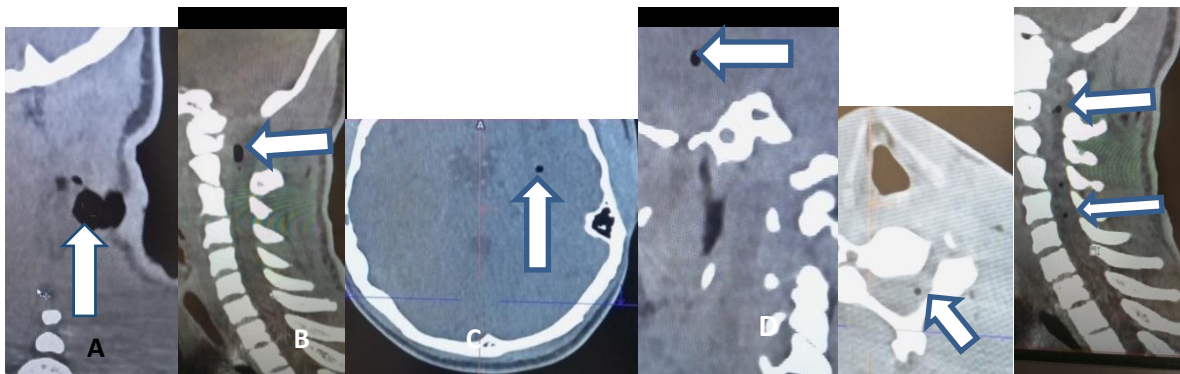


Fig. 5. CT scan showing A subcutaneous emphysema, B intracanal spinal pneumorrhaphy, C and D pneumocephalus

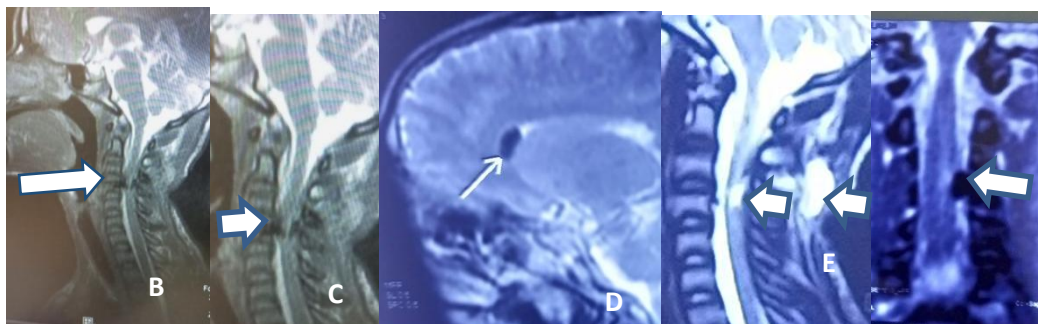


Fig. 6. MRI showing : A- B- D-E, spinal cord contusion with intracanal spinal pneumorrhaphy; c, ventricular pneumocephaly; D-E ,subcutaneous emphysema

The post-operative period was marked by good healing, with some deficit after-effects treated by supplementary physiotherapy, which enabled the patient to go from standing on a walker to walking with a cane after one month's physiotherapy.

3. DISCUSSION

Morbidity and mortality as a result of violence are on the increase worldwide. It is caused by inactions between men, which can lead to the use of bladed weapons. These weapons can cause wounds and trauma to the spine. In fact, the 1977 report by Peacock and his colleagues on 450 stab wounds to the spinal cord remains the largest of its kind to date (9,10). These injuries accounted for around 25% of all the cases of spinal cord injury they treated over a 13-year period. The authors found that knives were the most commonly used object (84.2% of cases), followed by an axe, machete, screwdriver, bicycle spoke, scissors, garden fork, sickle and sharpened broom handle; stab wounds caused by a pencil and splinter were also reported [10-12].

Our two clinical cases were wounds of the spine caused by the knife, one at cervical level, the other at lumbar level, our sample is very small to draw a comparison on the site of the lesions, having less in the series of Paecok [10] the wounds of the thoracic spine is most affected. The common point is that the wounds are located on the posterior face, in the posterior regions of the trunk, which are areas of wounding by surprise or during escape. In the patient with the cervical wound. Associated lesions include emphysema, pneumorrhachia and pneumoencephalopathy in the parenchymal and ventricular areas, lesions which are very rarely described in vertebral stab wounds [13,14]. The technique used to extract the knife by an untrained team was responsible for this dissemination of the area under the skin and in the neuraxis, and spinal cord lesions were also aggravated by this technique. The patient with the lumbar bullet wounds had no neurological deficits despite the path and depth of the bullet, which could be explained by the nerves of the ponytail which, bathed in CSF, can move and not be traumatized. In both cases, the stability of the three spinal columns did not justify per-surgical instrumentation [15,16].

The management of patients with stab wounds with emphysema, pneumorrhachia and

pneumocephalus and spinal cord compression is an emergency; it not only makes it possible to close the dural breach and the subcutaneous air entry pathway to the neuraxis, but also to perform a laminectomy to decompress the cervical cord [14]. This decompression was deficient in order to improve after the laminectomy, supplemented by physiotherapy which remains today the best treatment for neurological deficits of the spinal nerves. In non-deficient patients, the extraction of materials in the emergency department without surgical intervention and openings has been imposed in view of the patient's indigence. The risk of this extraction without surgical intervention is the possibility of creating secondary lesions. In our patient, no deficit was observed after the extraction of the knife. It should be noted that neurosurgical intervention in penetrating knife wounds without neurological deficit remains controversial in the literature [17-20]. The appearance of lesions secondary to the removal of the non-surgical knife is the main point of disapproval [21].

The limitation of this study is related to the number of cases described, given the rarity of cases described in the literature where only clinical cases are retrieved, a multicenter study would be more contribution to deepen the study of stab wounds.

4. CONCLUSION

The rise of the civilisation of violence is increasing with the use of bladed weapons, which are easily accessible at low cost, and their availability, given that they are used in everyday life for many purposes. The forms of bladed weapon are very varied (knife, axe, machete, screwdriver, bicycle spoke, scissors, garden fork, sickle and sharpened broom handle, etc.). The knife is the bladed weapon used in both our patients. These bladed weapons can cause penetrating wounds of the vertebrae and spinal cord, with nerve and infectious complications. While the existence of a meningeal breach and neurological deficit are indications for surgical intervention supplemented by complementary physiotherapy, the place of surgery in penetrating stab wounds without neurological deficit remains controversial.

ETHICAL APPROVAL

As per international standard or university standard written ethical approval has been collected and preserved by the author(s).

CONSENT

As per international standard or university standard, patient(s) written consent has been collected and preserved by the author(s).

COMPETING INTERESTS

Authors have declared that no competing interests exist.

REFERENCES

1. Daban JL, Bensalah M, Hofmann C, Goudard Y, Pons F, Debien B. Spécificités de la prise en charge des traumatismes pénétrants, session commune sfmu/sfar urgences digestives, urgence. 2012;68: 1-13.
2. Brittany Robinson, Laura N Purcell, Chifundo Kajombo, Jared Gallaher, Anthony Charles. Results of stab wounds presented at Kamuzu Central Hospital in Malawi. *Malawi Med J.* 2021;33(1):1-6. DOI:10.4314/mmj.v33i1.1,PMCID: MC8360291PMID: 3442227
3. Dijkink S, krijnen P, Hage A, Van der Wilden GM, Kasotakis G, denHartog D, et al. Differences in characteristics and outcome of patients with penetrating injuries in the USA and the Netherlands: a multi-institutional comparison. *Monde J Surg.* 2018;42(11):3608-3615. [Free PMC article] [PubMed] [Google Scholar]
4. Mnguni MN, Muckart DJ, Madiba TE. Abdominal trauma in Durban, South Africa: factors influencing outcome. *International Surgery.* 2012;97(2):161-168. [Free PMC Article] [PubMed] [Google Scholar]
5. Miller TR, Cohen MA. Costs of gunshot and stab wounds in the United States, with some Canadian comparisons. *Accident Analysis and Prevention.* 1997;29(3):329-341. [PubMed] [Google Scholar]
6. Donnally CJ, Hannay W, Rapp DA, Lekic N, Dodds SD. Archives of orthopaedic and trauma surgery. 2017;137(12):1615-1621. [PubMed] [Google Scholar]
7. Carlos Castillo Amaya, Jose Antonio Prieto Meré. Stab wound to the spine without neurological involvement: report of a rare case. *Case Reports J Surg Case Rep.* 2021;2021(5):rjab163. DOI : 10.1093/jscr/rjab163.
8. André Luiz Beer-Furlan, Wellingson Silva PaivaWagner Malagó Tavares, Almir Ferreira de Andrade, Manoel Jacobsen Teixeira. Brown-Sequard syndrome associated with an unusual spinal cord injury by a screwdriver stab wound. *Int J Clin Exp Med.* 2014;7(1):316-319.
9. Peacock WJ, Shrosbree RD, Key AG. A review of 450 stabwounds of the spinal cord. *S Afr Med J.* 1977;51:961-4.
10. Taophee Bamidele Rabi, Abayomi Adeniran Aremu, Olusegun Adetunji Amao, T Jacob Olumuyiwa Awoleke. Screwdriver: an unusual cause of cervical spinal cord injury. *Case Rep BMJ.* 2011;2011: bcr0620114309.
11. Meltzer HS, Kim PJ, Ozgur BM, et al. Vertebral body granuloma of the cervical region after pencil injury. *Neurosurgery.* 2004;54:1527-9; discussion 1529-30. [PubMed] [Google Scholar]
12. Thakur RC, Khosla VK, Kak VK. Non-missile penetrating injuries of the spine. *Acta Neurochir (Wien).* 1991;113: 144-8. [PubMed] [Google Scholar]
13. Markus F. Oertel, Marcus C. Korinth, Marcus H. T. Reinges, Timo Krings, Sandra Terbeck, Joachim M. Gillsbach Pathogenesis, diagnosis and management of pneumorrhachia. *Eur Spine J.* 2006;15(Suppl 5): 636-643.
14. Goh BK, Yeo AW. Traumatic pneumorrhoea. *J Trauma.* 2005;58:875-879.
15. Jackson Rucker chancele, Corresponding author Thomas Elliot Niemeier, William E. Neway, III, Steven Michael Theiss. Stability of the subaxial spine after penetrating trauma: do classification systems apply? *Adv Orthop.* 2018;2018:6085962. Published online 2018 Oct 9.
16. Ibrahim Alghamdi, Naif Bazaie, Naif Alqurashi, Zubair Ahmed. The impact of prehospital spinal immobilization in patients with penetrating spinal injuries: a systematic review and meta-analysis. *Rauma Care.* 2022;2(2):226-237. Available:https://doi.org/10.3390/traumacar e2020019
17. Prateek Agarwal, John F. Burke, Kalil G. Abdullah, Matthew Piazza, Brian P. Smith, Jayesh P. Thawani, Neil R. Malhotra. Case report stab wound to the intramedullary spinal cord: presurgical and surgical management options for a retained blade

- to optimize neurological preservation. SNI: Spine - A Supplement to Surgical Neurology International. 2016;7(Suppl 42):1096-1097.
18. Li X, Curry EJ, Blais M, Ma R, Sungarian AS. Intraspinal penetrating stab injury to the middle thoracic spinal cord with no neurologic deficit. Orthopedics. 2012;35:e770-3.
 19. Skadorwa T, Ciszek B. Pediatric arrowshot injury to cervical spinal cord-sagittal cord transection with no neurological deficit and good outcome: Case report and review of literature. Childs Nerv Syst. 2013;29:1933-9.
 20. Oualid Mohammed Hmamouche, Faycal Lakhdar, Mohammed Benzagmout, Khalid Chakour, Mohammed El Faiz Chaoui1. Case report stab injury to the lumbar spine without neurological involvement in a in a child. Surgical Neurology International. 2023;14(129):1-3.
 21. Andrew D. Parsons, Rose Fluss, Sean Willis, and Ralph Rahme. Through-and-through stab wound of the cervical spinal canal with retained weapon but no neurological repercussions: an exceptionally rare injury and the case for direct withdrawal. Illustrative case. J Neurosurg Case Lessons. 2022;3(14):1.

© 2023 Joseph et al.; This is an Open Access article distributed under the terms of the Creative Commons Attribution License (<http://creativecommons.org/licenses/by/4.0>), which permits unrestricted use, distribution, and reproduction in any medium, provided the original work is properly cited.

Peer-review history:

The peer review history for this paper can be accessed here:
<https://www.sdiarticle5.com/review-history/102192>