



# Huge Multicystic Splenic Lymphangioma in an Adult: A Case Report

S. N. Jatal<sup>a++\*</sup>, Sudhir Jatal<sup>b#</sup> and Sachin Ingle<sup>c†</sup>

<sup>a</sup> Jatal Hospital and Research Centre, Latur, India.

<sup>b</sup> Jatal Hospital and Research Centre, Latur, Tata Hospital, Mumbai, India.

<sup>c</sup> Department of Pathology, MIMSR Medical College, Latur, India.

## **Authors' contributions**

*This work was carried out in collaboration among all authors. All authors read and approved the final manuscript.*

## **Article Information**

### **Open Peer Review History:**

This journal follows the Advanced Open Peer Review policy. Identity of the Reviewers, Editor(s) and additional Reviewers, peer review comments, different versions of the manuscript, comments of the editors, etc are available here: <https://www.sdiarticle5.com/review-history/104813>

**Case Study**

**Received: 12/06/2023**

**Accepted: 18/08/2023**

**Published: 26/08/2023**

## **ABSTRACT**

Splenic Lymphangiomas are incredibly uncommon lesions that mostly affect children. These are divided into benign and malignant tumors, as well as real splenic cysts. A rare and slowly developing benign tumor of the spleen is called a splenic lymphangioma. So far fewer than 100 cases have been reported in the literature. The incidence of splenic lymphangioma is 80-90% in children's less than two years age and few cases are reported in adults. Splenic lymphangiomas are accounting for less than 0.007% of all splenic tumours, that appears as a single or multiple cystic lesions of the spleen.

We report an extremely rare cases of a 38 years old male, presented with left upper quadrant abdominal pain and huge palpable lump extending up to umbilicus. We performed open total splenectomy.

<sup>++</sup>M.S. F.I.C.S., FAIS, FIGES;

<sup>#</sup>Fellow in Colorectal Cancer;

<sup>†</sup>Professor;

\*Corresponding author: E-mail: [jatalhospital@gmail.com](mailto:jatalhospital@gmail.com);

**Keywords:** Splenic lymphangioma; splenectomy; splenic tumours.

## 1. INTRODUCTION

“Splenic lymphangioma is a rare and it is slow growing lesion usually seen during childhood and rarely seen after 20 years of age. In adulthood, it is usually and incidental findings. However due to increase in size of the spleen, some adult patient may present with left upper quadrant pain, abdominal distention and palpable abdominal mass. Splenic lymphangioma is proposed to be due to abnormal congenital development of lymphatic vessels or inflammation of the lymphatic system which causes obstruction and consequent Lymphangiectasia. The splenic lymphangioma are solitary, multiple nodule and diffuse lymphangiomatosis” [1,2,3].

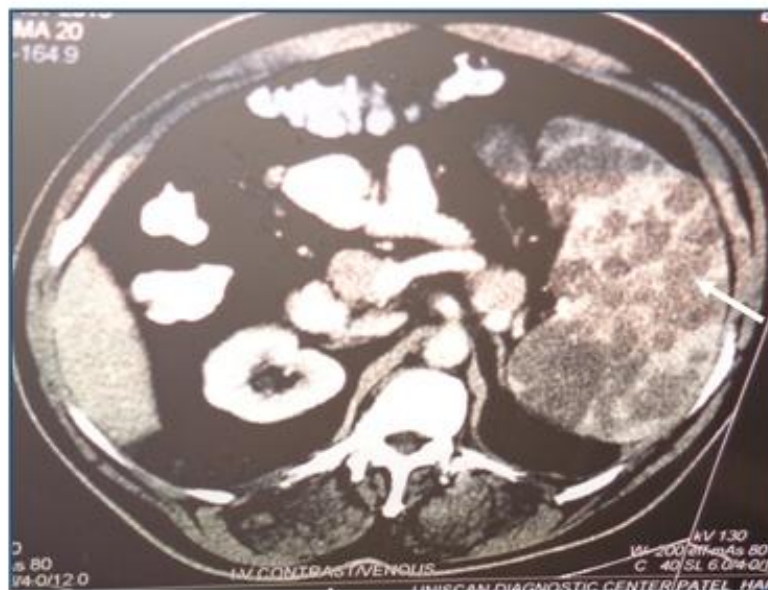## 2. CASE PRESENTATION

A 38 years old male patient was admitted to our centre on 11/11/2013 with complains of abdominal pain, abdominal distension and huge splenomegaly for one years. A physical examination revealed a significant abdominal distension, with huge splenomegaly that extend beyond the umbilical area. The spleen on palpation was firm is consistency and lobulated surface. The patient had no other organomegaly or adenopathy. All laboratory investigation including kidney function tests were normal.

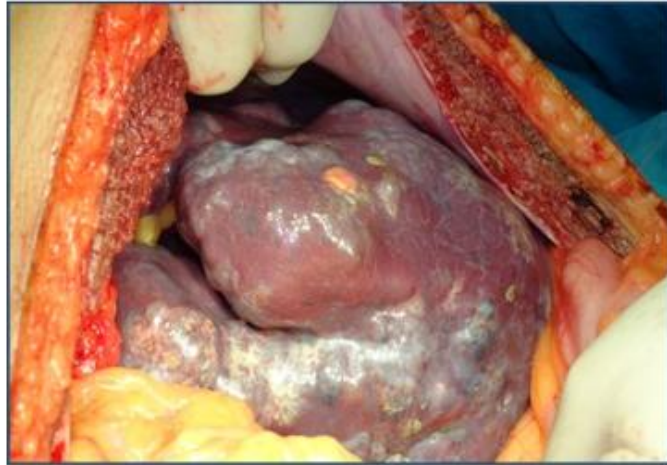Abdominal CT scan was obtained which revealed a splenic mass of 20x15x7 cm with multiple cystic hypodense nodules with variable size. The mass was limited to the spleen and pushed the stomach without invasion. The radiologist suggested the diagnosis of huge splenic lymphangioma with “honeycomb” appearance.

Patient received pneumococcal vaccination two weeks prior to surgery. Under general anaesthesia, explorative laparotomy showed a huge spleen with multinodular surface. Splenic artery and vein were identified and ligated. After words splenocolic, lenorenal and splenophrenic ligaments were dissected and proceeded with ligation of short gastric vessels and total splenectomy was done, with minimal blood loss. Post-operative recovery was uneventful and patient discharged on 8<sup>th</sup> postoperative day. The follow up after one years was normal.

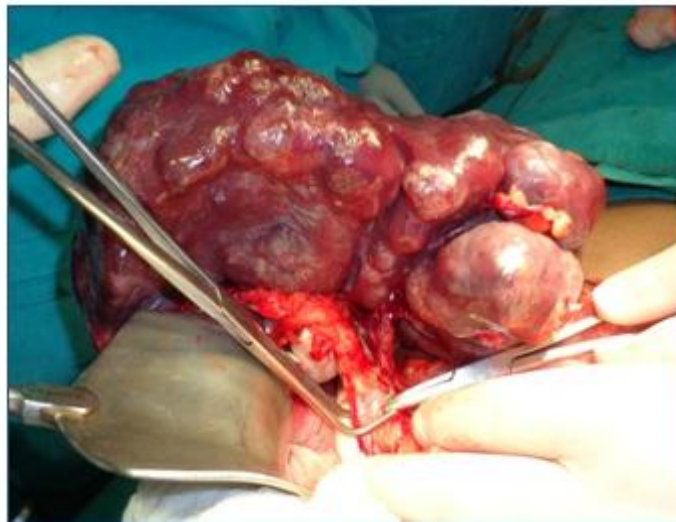On gross examination revealed the specimen, a huge multinodular spleen, weighing 3.5 kg and measured 20x15x7 cm. Microscopic examination showed numerous large vascular channels that are line by a single layer of flattened cells. Their lumens are filled by eosinophilic fluid and few red blood cells. There was no evidence of malignancy. A diagnosis of cystic lymphangioma was made (Figs. 1-6).



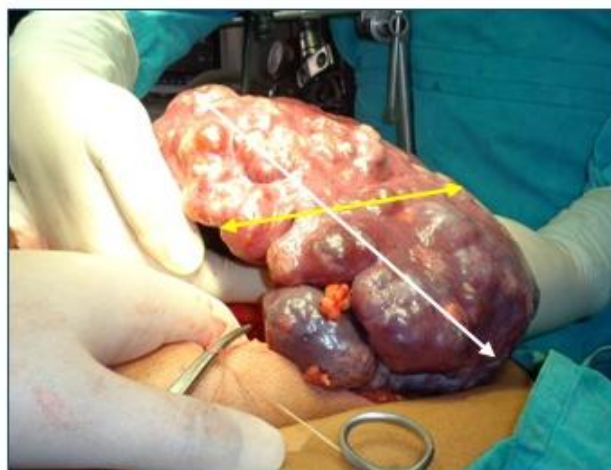
**Fig. 1. CT Abdomen showing multiple hypodense cystic lesion in spleen of size 20x15x7 cm**



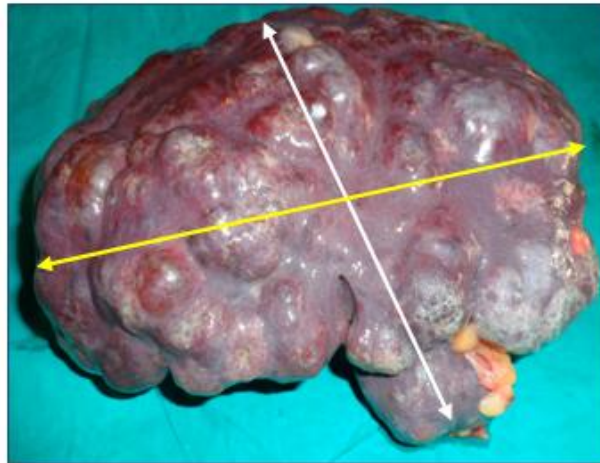
**Fig. 2. Intra operative photographs showing huge Splenic mass**



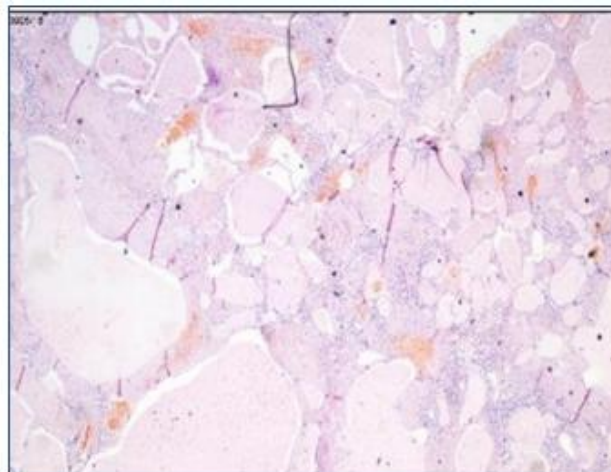
**Fig. 3. Intra operative photographs showing ligation of splenic pedicle (artery and vein)**



**Fig. 4. Intra operative photographs showing multi nodular diffuse splenic lymphangiomas**



**Fig. 5. On gross - photographs showing multi cystic nodular splenic mass of size 20x15x7 cm & weighing 3.5 kg**



**Fig. 6. Cysts lined by endothelial cells filled with proteinaceous material**

### 3. DISCUSSION

“Splenic lymphangioma is a benign cystic neoplasm that resulted from congenital malformation of the lymphatic system and accounts for less than 0.0007% of all tumours. It is a slow growing lesion usually seen during childhood and rarely seen in adulthood” [2,3].

“It is still controversial whether splenic lymphangioma is neoplasm or hamartoma. Most pathologists believe, it is a hamartoma due to anomalous congenital expansion of the lymphatic vessels, bleeding or inflammation leading to obstruction and subsequent lymphangiectasia. The clinical presentation of splenic lymphangioma is usually related to the size of the spleen but they can be asymptomatic or incidental findings during radiological

investigation if they are large, they can cause abdominal pain, abdominal distension and palpable mass on physical examination. CT scan typically show multiple sub-capsular hypoechoic lesions and occasional peripheral rim of calcification. Its diagnosis is often made through imaging such as abdominal ultrasonography, CT and MRI” [1,2,4,5].

“Macroscopically, splenic lymphangioma can come in solitary nodule, multiple nodules or as diffuse lymphangiomatosis. Lymphangiomas is usually sub-capsular because lymphatic vessels are only found in the sub-capsular region. It consistence of a single large cyst or multiple thin walled cysts filled with clear fluid” [2,3,6-10].

Microscopically, these cysts are made up of multiple vascular channels lined by single layer

of endothelial cells and contains eosinophilic amorphous proteinaceous material. Lymphangiomas are classified in to three types according to the size of the dilated lymphatic channels.

1. Capillary Lymphangioma
2. Cavernous lymphangioma
3. Cystic lymphangioma

“Multinodular cystic lymphangioma appears as a honeycomb of varying size of thin walled cysts containing lymph, other immunohistochemical technique such as CD31, CD34 and factor VIII can be utilized. The treatment of choice for splenic lymphangioma is complete surgical resection. Laparoscopic splenectomy is emerging as the procedure of choice with consideration of the size and volume of the spleen. The prognosis of total splenectomy in splenic lymphangioma is excellent” [1,2,5].

#### 4. MINI REVIEW

“The first case involving the spleen was reported in 1885 by Frink. Between 1939 and 2017, only 209 cases of splenic lymphangiomas were reported in the literature. Therefore, splenic lymphangiomas are considered uncommon benign tumours, occurring mainly in childhood, with only a few cases reported in adults. In most patients, the lymphangiomatous process involves additional sites in a diffuse or multifocal fashion such as the liver, mediastinum, and lung, the so-called lymphangiomatosis syndrome. Some cases of splenic lymphangiomas are associated with synchronous or metachronous cystic hygroma of the neck. Isolated splenic lymphangiomas constitute a much rarer form; only 15 cases between 1990 and 2017 were reported” [1,2,5].

#### 5. CONCLUSION

Splenic lymphangioma presenting in adulthood are extremely rare and once diagnosed, surgery may be the most effective modality of treatment. Laparoscopic splenectomy is emerging as the procedure of choice in normal or moderately enlarged spleen but contraindicated in patients with massive splenomegaly.

#### CONSENT

As per international standard or university standard, patient(s) written consent has been collected and preserved by the author(s).

#### ETHICAL APPROVAL

As per international standard or university standard written ethical approval has been collected and preserved by the author(s).

#### COMPETING INTERESTS

Authors have declared that no competing interests exist.

#### REFERENCES

1. Perez A, Perez MEC, Yuga AC, Viray BAG. Splenic lymphangioma in adulthood: A case report. *Int J Surg Case Rep.* 2020; 67:250-253. DOI: 10.1016/j.ijscr.2020.01.061 Epub 2020 Feb 11. PMID: 32086147; PMCID: PMC7029340.
2. Thiam Ousmane, Faye Papa Mamadou, Sarr Ibrahima Sitor, Niasse Abdou, Dieng Madien. Splenic lymphangioma, *International Journal of Surgery Case Reports.* Available: <https://doi.org/10.1016/j.ijscr.2019.07.078>
3. Efares B, Atsame-Ebang G, Zabeirou A. et al. Isolated splenic lymphangioma presenting as a huge mass causing anemia and abdominal distension in an adult patient: A case report. *J Med Case Reports.* 2018;12:97. Available: <https://doi.org/10.1186/s13256-018-1664-5>
4. Raza M, Preethi SP, Kumar HP, Ali MZ, Jasuja P. Splenic lymphangioma: a rare benign tumor in adults. *Int Surg J.* 2018;5:3403-6.
5. Pham MD, Nguyen MT, Vo MTT, Hoang VT, Pham NTT. Splenic lymphangioma in adult patient treated with laparoscopic splenectomy: A rare case report. *SAGE Open Medical Case Reports.* 2023;11. DOI: 10.1177/2050313X221147196
6. Nisha Marwah, Monika Sangwan, Megha Ralli, Renuka Verma, Swagatika Samal. Cystic Lymphangioma of Spleen: A Rare Report. *Int J Sci Stud.* 2014;2(1):40-42
7. Vezzoli M, Ottini E, Montagana M, et al. Lymphangioma of the spleen in an elderly patient. *Hematologica.* 2000;85:314-317.
8. Verghese, Basil George, Kashinath, Sanjana, Kanth R. Lymphangioma of the Spleen-A Rare Tumor Rarely seen in an Adult: A Case Report and a

- Comprehensive Literature Review. Euroasian Journal of Hepato-Gastroenterology. 2013;3:64-69. DOI: 10.5005/jp-journals-10018-1066
9. Amarjothi JMV, Bennet D, Prabakar R, Kannan D, Naganath Babu OL. Multicystic lesions of the spleen: A rare presentation of splenic lymphangioma in adult. J Case Rep Images Pathol. 2017;3:5–8.
10. Soleimani N, Pouraminaee F, Anbardar MH, Bahador A, Rahimi B, Mohammadzadeh S, et al. Splenic Lymphangioma Mimicking Lymphomatous Involvement: A Case Report with Review of the Literature. Case Rep Med. 2023 Jun 20;2023:9969213. DOI: 10.1155/2023/9969213 PMID: 37383046; PMCID: PMC10299890.

© 2023 Jatal et al.; This is an Open Access article distributed under the terms of the Creative Commons Attribution License (<http://creativecommons.org/licenses/by/4.0>), which permits unrestricted use, distribution, and reproduction in any medium, provided the original work is properly cited.

*Peer-review history:*

*The peer review history for this paper can be accessed here:*  
<https://www.sdiarticle5.com/review-history/104813>