



# Primary Hydatid Cyst of the Breast: A Mini Review

S. N. Jatal <sup>a\*</sup>, Sudhir Jatal <sup>b++</sup> and Sachin Ingle <sup>c#</sup>

<sup>a</sup> Jatal Hospital and Research Centre, Latur, India.

<sup>b</sup> Jatal Hospital and Research Centre, Latur, Tata Hospital, Mumbai, India.

<sup>c</sup> Department of Pathology, MIMSR Medical College, Latur, India.

## **Authors' contributions**

*This work was carried out in collaboration among all authors. All authors read and approved the final manuscript.*

## **Article Information**

### **Open Peer Review History:**

This journal follows the Advanced Open Peer Review policy. Identity of the Reviewers, Editor(s) and additional Reviewers, peer review comments, different versions of the manuscript, comments of the editors, etc are available here: <https://www.sdiarticle5.com/review-history/105406>

**Case Report**

**Received: 18/06/2023**

**Accepted: 23/08/2023**

**Published: 26/08/2023**

## **ABSTRACT**

Hydatid cyst of the breast is a very rare only few cases of breast hydatid cyst are published and majority of the reported cases have been diagnosed post operatively. Hydatid disease is parasitic infection caused by echinococcus granulosus. The definitive host is dog, intermediate host is sheep and human are accidental intermediate hosts. Hydatid disease is endemic in many parts of the world such as middle east Africa, South America, New-Zealand, Australia, Iran, Iraq and Turkey. In India highest prevalence is reported in Andhra Pradesh, Tamil Nadu and Jammu and Kashmir. Common location of hydatid cyst is liver (75%) and Lungs (15%) while unusual location like kidney, spleen, pancreas, heart, brain, bones, thyroid and muscles including the remaining 10% cases. Breast is very rare site for hydatid disease, accounting for 0.27% of cases.

We are reporting a rare case of hydatid cyst of the breast in a 40 years old female, patient having painless lump at left upper quadrant of the breast since one year. On ultrasonography diagnosed a benign simple cystic lump in the left breast. Intraoperative revealed the cystic lump was containing hydatid cyst with multiple daughter cysts, so we performed complete excision of the cyst with wide margin and pericystectomy was done.

<sup>++</sup> Fellow in Colorectal Cancer;

<sup>#</sup> Professor;

\*Corresponding author: E-mail: [jatalhospital@gmail.com](mailto:jatalhospital@gmail.com);

**Keywords:** Breast hydatid cyst; *Echinococcus granulosus*; hydatid cyst.

## 1. INTRODUCTION

“Hydatid cyst of the breast is very rare. Patients usually present to the hospital with a palpable and painless lump in the breast. Hydatid cyst in breast affect women between 30 and 50 years of age. Hydatid cyst may be found in any part of the body. The liver acts as the first filter and accounts for about 75% of all cases, while lung the second filter about 15%, 2.5% of the cysts are found in the kidney, 2.5% in heart, 2% in bone, 1.5% in spleen, 1% in muscle and 0.5% in the brain” [1-3].

“The breast is very rare site, as it constitutes only 0.27% of all cases. High resolution ultrasound is more specific than mammography in identifying a hydatid cyst. Cytology of aspirated fluid revealed a hydatid cyst and majority of these cases have been diagnosed post operatively. Breast lumps mimic fibroadenoma, phyllode tumours, chronic abscess or even carcinoma. Ultrasound, cytology and MRI play an important role in preoperative diagnosis” [1,3,4].

## 2. CASE PRESENTATION

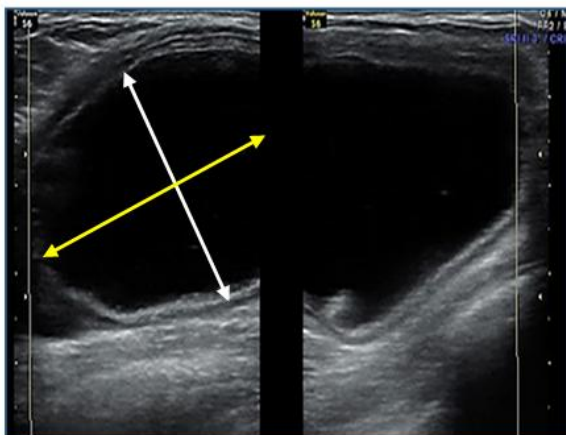
A 40 years old female was admitted to our centre on 07/10/2012 with complains of painless lump a left upper quadrant of the breast since one year. On physical examination there was a fluctuant,

non-tender, mobile lump on the upper outer quadrant of the left breast of size 5x4x3 cm. The overlying skin was normal and intact appearing. There was no axillary lymph-node enlargement. The contralateral breast was normal. Her vital signs were stable. Complete blood counts were within normal limits.

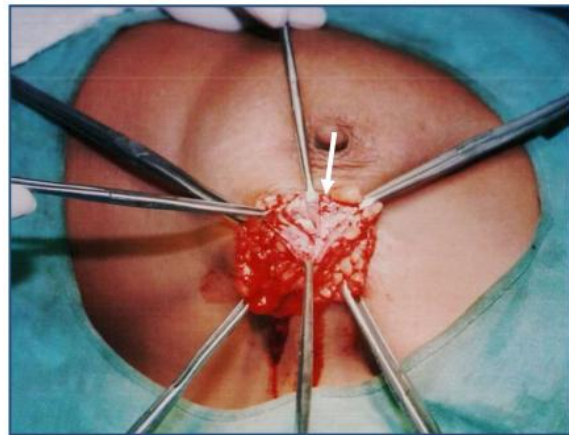
An ultrasonography was performed, which showed as well defined cystic lesion in the upper quadrant of the left breast. The lesion was cystic with thick wall and containing debris. The lesion measured 5x4x3 cm and a diagnosed a simple cyst of the breast was done.

Under general anaesthesia, the patient underwent wide excision of cystic lump. Total excision of left upper outer quadrant of breast. So total pericystectomy was done. When the cyst was opened, to our surprise, there were endocyst with multiple daughter cysts (Figs. 1-6).

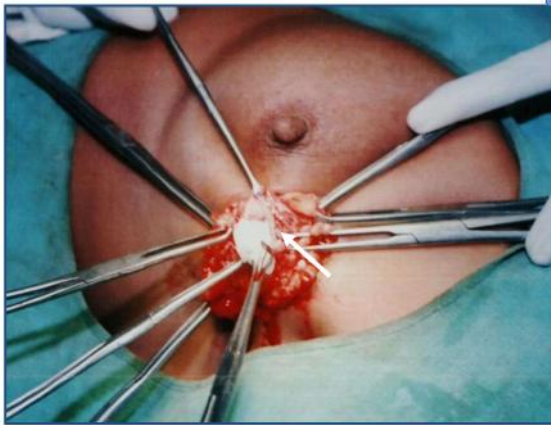
On gross examination, there was 5x4x3 cm cystic tissue with grey white outer surface. On cut section, there were multiple daughter cysts with white gelatinous germinal membrane. On microscopic examination revealed germinated and acellular laminated layers of hydatid cyst. Postoperative recovery was uneventful and patient received post-operative Albendazole treatment and recurrences was not observed in the last 12 months after the surgery.



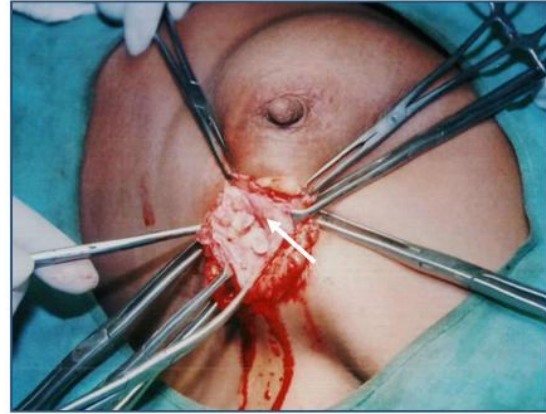
**Fig. 1. Ultrasonography of breast showing cystic lesion with thick wall of size 5x4x3 cm**



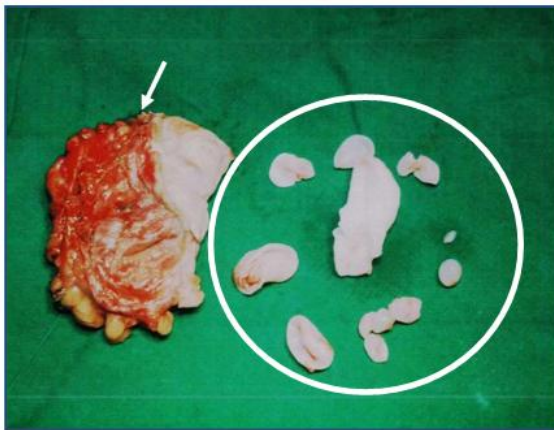
**Fig. 2. Intra-operative photograph showing breast hydatid cyst**



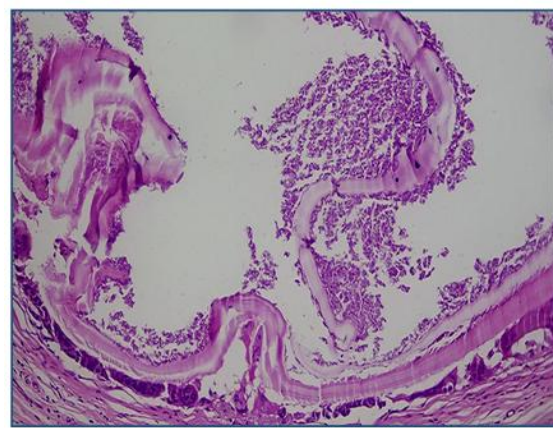
**Fig. 3. Intra-operative photograph showing breast hydatid cyst**



**Fig. 4. Intra-operative photograph showing breast hydatid cyst with multiple daughter cysts**



**Fig. 5. Photograph showing total pericystectomy done with multiple daughter hydatid cysts**



**Fig. 6. Histopathological examination showing germinating and laminated layer of hydatid cyst**

### 3. DISCUSSION

Hydatid cyst is a parasite disease caused by *Echinococcus granulosus*. The liver acts as first filter and stops about 75%, while lungs, the second filter, stop about 15% and only 10% embryos develop cyst in other organs of the body, kidney, 2.5% in heart, 2% in bone, 1.5% in spleen, 1% in muscle and 0.5% in the brain. Hydatid diseases of the breast is rare and account for only 0.27% of all cases. "Typically, the patient present with painless breast lump without regional lymph-node involvement. It generally affects women between 30 to 50 years of age. It mimic fibroadenoma, phyllode tumours chronic abscess or even carcinoma. Preoperative diagnosis can be made by fine needle aspiration cytology where scolices, hooklets or laminated membrane can be identified" [1,3].

"Mammography and ultrasound may play important role in evaluation of hydatid cyst. Mammography may reveal a ring shaped structure inside a circumscribed mass lesion" [2]. The ultrasound demonstrated with thick cystic wall and internal multi-cystic "Spoke wheel" or floating membranes "Water Lily Sign", debris of hydatid sand and peripheral calcification. CT and MRI play a significant diagnosis role in preoperative diagnosis [1,3,4].

Serological test like indirect hemagglutination immuno-electrophoresis and Elisa test are used for diagnosis. On fine needle aspiration cytology laminated membrane, scolices, hooklets. and giant cells in consistent with diagnosis of a hydatid cyst.

"A hydatid cyst is treated with total excision of cyst without any spillage and its recurrence is

very rare. Albendazole treatment reduces the incidence of recurrence. In our case after complete excision of the cyst and Albendazole was given postoperative and there was no recurrence” [2,3].

The largest reported series in literature are 20 cases breast hydatid cysts, reported by Quedraogo in a retrospective study between 1969-1982. Sagin et al found 54 breast hydatid cysts which were reported until 1994 and Arikan found 10 more reports till 2004. A total of 121 cases of breast hydatid cysts were reported in the literature up to 2018. We found 10 more cases of hydatid cysts in the breast till date on PubMed search, making a total of 132 cases. Our cases of hydatid cyst in the breast would add up to 133 recorded cases, according to the best of our knowledge [5-10].

#### 4. CONCLUSION

Breast hydatid cysts are extremely uncommon diseases. Ultrasound, cytology and MRI play an important preoperative diagnostic role. Treatment is surgical pericystectomy associated with medical treatment with Albendazole therapy.

#### CONSENT

As per international standard or university standard, patient(s) written consent has been collected and preserved by the author(s).

#### ETHICAL APPROVAL

As per international standard or university standard written ethical approval has been collected and preserved by the author(s).

#### COMPETING INTERESTS

Authors have declared that no competing interests exist.

#### REFERENCES

1. Moussaoui KE, Lakhdar A, Baidada A, Kherbach A. Hydatid cyst of the breast: case report. *Int J Surg Case Rep.* 2020; 77:325-328. DOI: 10.1016/j.ijscr.2020.10.109. Epub 2020 Oct 31. PMID: 33197778; PMCID: PMC767766

2. Kassahun Tadele A, Israel Korga T, Melis Nisiro A, Abebe Ayele S. Rare Case Report on Hydatid Cyst of Breast. *Pathology and Laboratory Medicine International.* 2022;14:33-36 Available:https://doi.org/10.2147/PLMI.S380081
3. Meshram N, Kamal F, Gadkari R. Hydatid cyst of breast: Unwelcome guest at unusual site; A case report and review of literature. *International Journal of Contemporary Medical Research* 2021; 8(1):A12-A16
4. Kumar A, Kumar A, Gaurav K, Chandra G, Tiwary AK, Bhagat S, Sarawgi M. A rare case of isolated hydatid cyst of breast. *Int J Surg Case Rep.* 2015;7C:115-8. DOI:10.1016/j.ijscr.2014.10.093. Epub 2014 Dec 11. PMID: 25582084; PMCID: PMC4336384.
5. Mahmood, Sidrah & Mahmood, Rabiaa. Pre-operative diagnosis of hydatid cyst in the breast: A case report of a rare entity and review of literature. *Journal of the Pakistan Medical Association.* 2023; 73:1530-1532. DOI:10.47391/JPMA.7085
6. Cancelo MJ, Martín M, Mendoza N. Preoperative diagnosis of a breast hydatid cyst using fine-needle aspiration cytology: A case report and review of the literature. *J Med Case Reports.* 2012;6:293. Available:https://doi.org/10.1186/1752-1947-6-293
7. Al Sharei Aiman, Abu-Jeyyab, Mohammad, Al-Khalaileh, Maysaa, Al-Awabdeh, Michleen Al-Asbahi, Hanan; Al-Dwairy, Salem, Al-Share, Mohammad. Bilateral hydatid cyst of the breast: A case report and review of the literature. *Annals of Medicine & Surgery.* 2023;85(6):2981-2984. DOI: 10.1097/MS9.0000000000000642
8. Venkatesh Vikram HC, Manasa S. A rare case of hydatid cyst in the breast in a tertiary care hospital in Bangalore, Karnataka, India. *Surgical Review: International Journal of Surgery, Trauma and Orthopedics.* 2020;6(04):282-285. Available:https://doi.org/10.17511/ijoso.2020.i04.10
9. Sutrarakar SK, Bhargava OP Singh UR, Lal S Azad KL. Primary hydatid cyst of breast: A case report. *Research J. Pharmacology and Pharmacodynamics.* 2011;3(6): 305-306.

10. Wubshet Assefa, Megbar Dessalegn, Sisay Admassu 3, Bekalu Molla, Breast hydatid cyst presented as a fluctuant painless lump mimicking galactocele: A case report, International Journal of Infectious Diseases. Available:<http://creativecommons.org/licenses/by-nc-nd/4.0/>

© 2023 Jatal et al.; This is an Open Access article distributed under the terms of the Creative Commons Attribution License (<http://creativecommons.org/licenses/by/4.0/>), which permits unrestricted use, distribution, and reproduction in any medium, provided the original work is properly cited.

*Peer-review history:*  
*The peer review history for this paper can be accessed here:*  
<https://www.sdiarticle5.com/review-history/105406>