

Continuous Spinal Anesthesia in Precarious Patients: An Experience in Lubumbashi DR Congo

Wasso Milinganyo Eddy¹, Timothée Dontaine², Sagboze Zalambo Sandra¹, Kibonge Mukakala Augustin^{3,4}, Zirhumana Namegabe Franck¹, Somwa Muhemedi Lucien⁵, Mukalay Banza Yves¹, Tshisuz Nawej Christian¹, Nguz A. Kutshid Nathan¹, Kanyanda Nafatalewa Dimitri³, Ilunga Banza Mannix³, Mulewa Umba Deogracias¹, Manika Muteya Michel¹, Mbuyi Musanzayi Sébastien³, Arung Kalau Willy³, Iteke Fefe Karl-Rivain^{1,5}

¹Department of Anesthesia and Critical Care, University Clinics of Lubumbashi, Lubumbashi, DR Congo

²Department of Surgery, Great Hospital of Charleroi, Charleroi, Belgium

³Department of Surgery, University Clinics of Lubumbashi, Lubumbashi, DR Congo

⁴Department of Surgery, Medicine School, Official University of Bukavu, Bukavu, DR Congo

⁵Department of Anesthesia and Critical Care, Diamant Medical Center, Lubumbashi, DR Congo

Email: eddymilinganyo1@gmail.com

How to cite this paper: Eddy, W.M., Dontaine, T., Sandra, S.Z., Augustin, K.M., Franck, Z.N., Lucien, S.M., Yves, M.B., Christian, T.N., Nathan, N.A.K., Dimitri, K.N., Mannix, I.B., Deogracias, M.U., Michel, M.M., Sébastien, M.M., Willy, A.K. and Karl-Rivain, I.F. (2023) Continuous Spinal Anesthesia in Precarious Patients: An Experience in Lubumbashi DR Congo. *Open Journal of Anesthesiology*, 13, 226-233. <https://doi.org/10.4236/ojanes.2023.1311021>

Received: September 3, 2023

Accepted: November 10, 2023

Published: November 13, 2023

Copyright © 2023 by author(s) and Scientific Research Publishing Inc. This work is licensed under the Creative Commons Attribution International License (CC BY 4.0).

<http://creativecommons.org/licenses/by/4.0/>



Open Access

Abstract

Background: Continuous spinal anesthesia (CSA) is an underused technique in modern anesthesia practice. Compared with other techniques of neuraxial anesthesia, CSA allows incremental dosing of an intrathecal local anesthetic for an indefinite duration, whereas traditional single-shot spinal anesthesia (SSA) usually involves larger doses, a finite, unpredictable duration, and greater potential for detrimental hemodynamic effects including hypotension, and epidural anesthesia via a catheter may produce lesser motor block and suboptimal anesthesia in sacral nerve root distributions. It is indicated in elderly patients undergoing lower limbs and sub umbilical surgery. **Aim:** This work aims to highlight the advantages of CSA on hemodynamic stability and as an alternative to heavy anesthetic procedures in already fragile patients. **Case presentation:** Our cases were two elderly patients, both of them with past stories of cardiac diseases. Both of them were undergoing amputation indicated for wet gangrene on lower limbs. They had unstable hemodynamics states due to inflammatory state. They were all rated ASA 3. CSA was performed with low doses of local anesthetics and maintenance by reinjections of mixture with the same doses. The interventions took place without major incidents and all patients survived. **Conclusion:** CSA is an underused technique in modern anesthesia. However, there is renewed interest due to the

quality of the blocs and the hemodynamics stability. We report a case series of 2 elderly patients with past stories of cardiac diseases undergoing amputation for dry gangrene that had been operated under CSA.

Keywords

Continuous Spinal Anesthesia (CSA), Precarious Patient, Dry Gangrene, Elderly Subject, DR Congo

1. Introduction

Central blocks (spinal anesthesia, continuous spinal anesthesia, epidural anesthesia, combined perispinal anesthesia) are simple, reliable and effective anesthesia, increasingly used in the last ten years [1].

Continuous spinal anesthesia (CSA), unlike single injection, allows titration of local anesthetics and, therefore, a decrease in hemodynamic repercussions [2].

CSA is an underutilized technique in modern anesthesia practice. Compared with other techniques of neuraxial anesthesia, it allows incremental dosing of an intrathecal local anesthetic for an indefinite duration, whereas traditional single-shot spinal anesthesia usually involves larger doses, a finite, unpredictable duration, and greater potential for detrimental hemodynamic effects including hypotension, and epidural anesthesia via a catheter may produce lesser motor block and suboptimal anesthesia in sacral nerve root distributions [3].

With the increased life expectancy and increased prevalence of geriatric population among societies, anesthesiologists are daily presented with the challenge of providing safe anesthesia and proper perioperative management for geriatric patients, while keeping in consideration their multiple comorbidities [4].

A study showed that CSA is a safe technique in octogenarian patients undergoing hip surgeries, with minimal effect on hemodynamics, decreased need for ephedrine and comparable rate of occurrence of side effects [5].

Concerning CSA, it's suggested that an inflammatory response is induced around the catheter site, sealing the arachnoid-dural dent and thus decreasing the cerebrospinal fluid leak [6].

We report a case series of 2 elderly patients with past stories of cardiac diseases undergoing amputation for dry gangrene that had been operated under CSA.

The patients gave their consent for the case reports to be published.

2. Presentation of the Cases

2.1. Case 1

A 68-year-old man (90 kg, 162 cm), presenting with dry gangrene, underwent amputation of the left leg under continuous spinal anesthesia. He had a history of arterial hypertension treated with captopril 25 mg per day and type 2 diabetes mellitus managed with 500 mg of metformin per day. The clinical examination

found agitation, and a respiratory rate of 24 cycles per minute. Blood pressure was normal.

The initial biological assessment included a blood count Hemoglobin = 8.3 g/dl; Hematocrit = 24.9%; platelets = 326,000/mm³, serum creatinine at 1.1 mg/dL, hemostasis assessment TP = 87.6%; TCK = 38.9; Blood group and rhesus: O positive), CRP 300 mg/L.

The electrocardiogram found left ventricular hypertrophy, incomplete right bundle branch block and apical ischemia (see **Figure 1**).

Vascular echocardiography reveals gangrene of the leg up to 5cm from the knee and mild aortic stenosis (see **Figure 2**).

Preoperatively, a dose of 5 mg amlodipine was prescribed.

In the operating room, monitoring included measurement of non-invasive blood pressure, pulsed oxygen saturation, heart rate, respiratory rate. The anesthetic technique was performed on a patient in a seated position, an intrathecal catheter was introduced at the level of the L3-L4 space (with a length of 3 cm in the subarachnoid space) allowing the injection of 6 ml of a mixture of 6 mg of

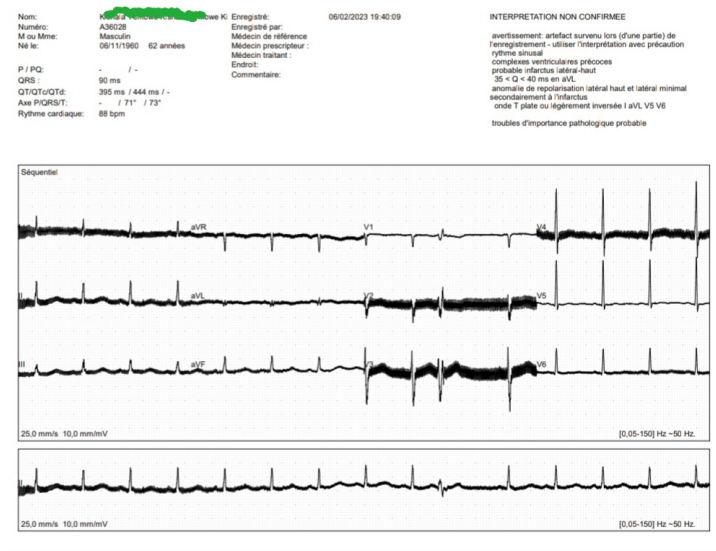


Figure 1. Standard ECG showing left ventricular hypertrophy, incomplete right bundle branch block and apical ischemia.

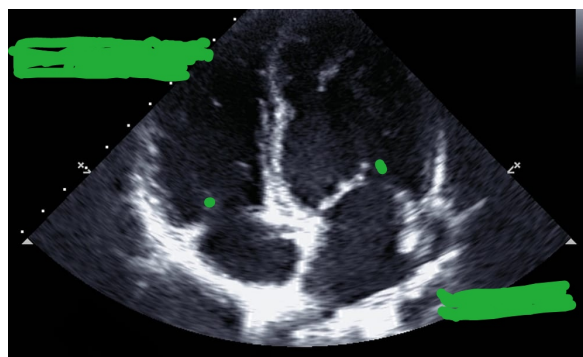

Figure 2. Cardiac ultrasound section showing aortic stenosis.

isobaric 0.2% ropivacaine and 15 mg of clonidine.

Ten minutes after continuous spinal anesthesia, the sensory block reached T8. During the operation (105 minutes), hemodynamics was stable. Two re-injections of 2 ml of mixture were necessary every 30 minutes. The intraoperative filling volume was one liter of normosaline and the blood loss was estimated at 500 ml, a transfusion of one unit of red blood cells was necessary.

At the end of the operation, postoperative analgesia was started with the intrathecal injection of 100 µg of morphine just before the catheter was removed. The postoperative course was simple. The postoperative biological assessment, identical to that performed preoperatively, remained normal. Getting up was authorized at hour 24 and leaving at day 4 postoperatively.

No complications were noted during the intervention and in immediate post operative period.

2.2. Case 2

A 63-year-old woman (70 kg, 160 cm), presenting also with dry gangrene, underwent amputation of the right leg under continuous spinal anesthesia. She had a story of a complete arrhythmia due to atrial fibrillation and monomorphic ventricular extra systoles treated with digoxin 5 mg per day and type 2 diabetes mellitus managed with 500 mg of metformin twice a day. The clinical assessment found a stable neurological, hemodynamics respiratory and renal state.

The initial biological assessment included a blood count Hemoglobin = 10.1 g/dL; Hematocrit = 30.9%; platelets = 250,000/mm³, serum creatinine at 0.86 mg/dl, hemostasis assessment TP = 86.6%; TCK = 36.8; Blood group and rhesus: O positive), CRP 148 mg/L. glycosylated hemoglobin was at 8.2%; total cholesterol of 227 mg/dL, with 161 mg/dL of LDL cholesterol.

The electrocardiogram found arrhythmia due to atrial fibrillation and monomorphic ventricular extra systoles (see **Figure 3**).

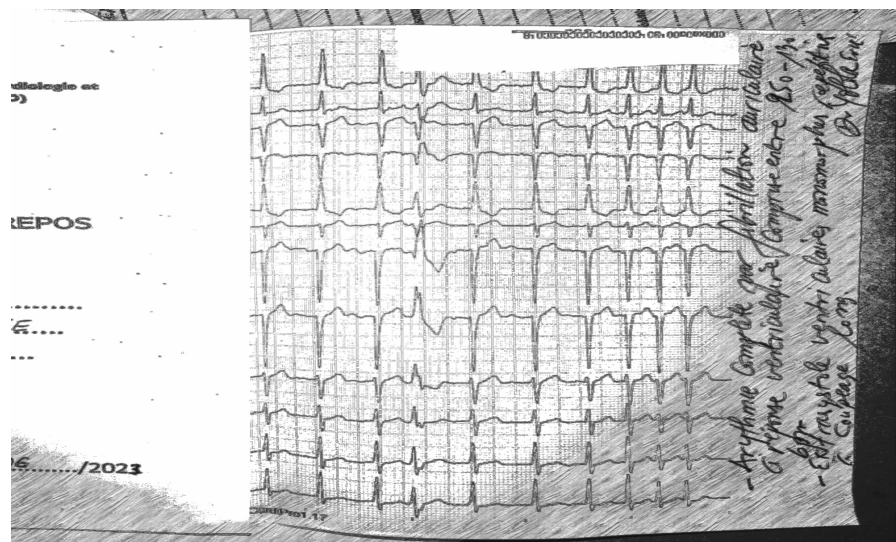


Figure 3. ECG of the patient showing complete arrhythmia due to atrial fibrillation.

Vascular echocardiography revealed an obliterating polyarteriopathy of the right lower limb of diabetic origin.

Preoperatively, the blood sugar control was insured by 10 units of rapid insulin thrice a day.

In the operating room, monitoring included measurement of non-invasive blood pressure, pulsed oxygen saturation, heart rate, respiratory rate. The anesthetic technique was performed on a patient in a seated position, an intrathecal catheter was introduced at the level of the L3 - L4 space (with a length of 3 cm in the subarachnoid space after the backflow of cerebral spinal fluid) allowing the injection of 6 ml of a mixture of 6 mg of isobaric 0.2% ropivacaine and 15 mg of clonidine.

Ten minutes after continuous spinal anesthesia, the sensory block reached T8. During the operation (90 minutes), the hemodynamic situation remained stable throughout the operation.

Two re-injections of 2 ml of mixture were necessary every 30 minutes. The intraoperative filling volume was one liter of normosaline and the blood loss was estimated at 300 ml.

At the end of the operation, postoperative analgesia started with 1 g of paracetamol IV infusion, 100 mg of tramadol and 75 mg of intramuscular diclofenac. The postoperative course was simple. The postoperative biological assessment remained as the preoperative ones. Getting up was authorized at hour 24 and leaving at day 4 postoperatively.

Brief, moderate tachycardia was the only complication and did not require additional medication.

3. Discussion

Spinal anesthesia is often preferred over general anesthesia for elderly patients with multiple comorbidities undergoing lower extremity orthopedic surgery, such as urgent repair of hip fracture [7]. Typically, these patients have an elevated risk of perioperative cardiovascular and thromboembolic complications, postoperative cognitive dysfunction, and delirium. Due to these concerns, spinal anesthesia is frequently selected over general anesthesia. Although some evidence exists that neuraxial block with either spinal or epidural anesthesia may be advantageous in patients at high risk for adverse cardiac events [8], this potential advantage is not universally accepted [9]. In a comparison of CSA with Single-shot Spinal Anesthesia and Continuous Epidural Anesthesia for lower extremity orthopedic surgery in elderly patients, mean arterial pressure did not change in the patients who had CSA, but in the CEA and SSA groups, mean arterial pressure dropped by 15% and 19%, respectively [10]. A recent study of elderly patients undergoing hip fracture repair compared CSA with low-dose bupivacaine SSA. In the SSA group, mean arterial pressure dropped by 30% in 51% of patients, while only 8% of patients with CSA exhibited such a change, despite receiving less ephedrine (11 mg with SSA versus 4.5 mg in CSA) to support

blood pressure [4].

These and other reports demonstrate greater blood pressure stability in elderly patients undergoing hip fracture repair with CSA compared with SSA [11].

Obviously, CSA is indicated and well tolerated in elderly patients with hemodynamics risks.

The preoperative clinical examination must be meticulous, in especially looking for signs of right heart failure or left. ECG and cardiac echo complete this examination.

CSA provides a number of potential advantages over other forms of anesthesia [12] [13] [14], including hemodynamic stability and extended analgesia [3] [15] [16]. In our regions of limited resources, the lack of CSA materials makes this practice rare despite its advantages on the hemodynamics stability.

In our case series no postdural puncture headache was noted. It is admitted in a review of records form 29,749 neuraxial blocks reported a significantly reduced incidence of PDPH when an intrathecal catheter was inserted after accidental dural puncture [17].

Many reports have been made recently on the practice of continuous spinal anesthesia in precarious patients with convincing results [2] [18].

4. Conclusion

For our case series we have performed CSA for two fragile patients and had few complications with quality anesthesia and immediate post-operative recovery of good quality.

Acknowledgements

The author would like to thank his colleagues and the nursing staff for their contributions.

Conflicts of Interest

The authors declare no conflicts of interest regarding the publication of this paper.

References

- [1] Adam, F. And Bonnet, F. (2004) Techniques des blocs centraux chez l'adulte. In: Dalens, B., Ed., *Traité d'anesthésie générale* (Vol. 6), Groupes de liaison SA, Paris, 1-25.
- [2] Fuzier, R., Murat, O., Gilbert, M-L., Maguès, J-P. and Fourcade, O. (2006) Rachianesthésie continue pour fracture du col fémoral chez deux patients présentant un rétrécissement aortique serré. *Annales Françaises d'Anesthésie et de Réanimation*, **25**, 528-531. <https://doi.org/10.1016/j.annfar.2006.01.007>
- [3] Moore, J.M. (2009) Continuous Spinal Anesthesia. *American Journal of Therapeutics*, **16**, 289-294. <https://doi.org/10.1097/MJT.0b013e3181729d2a>
- [4] Minville, V., Fourcade, O., Grousset, D., Chassery, C., Nguyen, L., Asehounne, K., et al. (2006) Spinal Anesthesia Using Single Injection Small-Dose Bupivacaine ver-

- Continuous Catheter Injection Techniques for Surgical Repair of Hip Fracture in Elderly Patients. *Anesthesia & Analgesia*, **102**, 1559-1563. <https://doi.org/10.1213/01.ane.0000218421.18723.cf>
- [5] Moussa, A.H., Elzahaby, H.M., Gomaa, E.Z. and Elseri, M.H. (2023) Hemodynamic Effects of Continuous versus Single Dose Spinal Anesthesia in Octogenarians Undergoing Hip Surgery: Randomized Control Trial. *BMFJ*, **40**, 245-257.
- [6] Charsley, M.M. and Abram, S.E. (2001) The Injection of Intrathecal Normal Saline Reduces the Severity of Postdural Puncture Headache. *Regional Anesthesia & Pain Medicine*, **26**, 301-305.
- [7] Beaupre, L.A., Jones, C.A., Saunders, L.D., *et al.* (2005) Best Practices for Elderly Hip Fracture Patients: A Systematic Overview of the Evidence. *Journal of General Internal Medicine*, **20**, 1019-1025. <https://doi.org/10.1111/j.1525-1497.2005.00219.x>
- [8] Rodgers, A., Walker, N., Schug, S., *et al.* (2000) Reduction of Postoperative Mortality and Morbidity with Epidural or Spinal Anaesthesia: Results from Overview of Randomised Trials. *BMJ*, **321**, 1493. <https://doi.org/10.1136/bmj.321.7275.1493>
- [9] Park, W.Y., Thompson, J.S., Lee, K.K., *et al.* (2001) Effect of Epidural Anesthesia and Analgesia on Perioperative Outcome: A Randomized, Controlled Veterans Affairs Cooperative Study. *Annals of Surgery*, **234**, 560-571. <https://doi.org/10.1097/00000658-200110000-00015>
- [10] Klimscha, W., Weinstabl, C., *et al.* (1993) Continuous Spinal Anesthesia with a Microcatheter and Low-Dose Bupivacaine Decreases the Hemodynamic Effects of Centroneuraxis Blocks in Elderly Patients. *Anesthesia & Analgesia*, **77**, 275-280. <https://doi.org/10.1213/00000539-199377020-00011>
- [11] Favarel-Garrigues, J.F., Sztark, F., Petitjean, M.E., *et al.* (1996) Hemodynamic Effects of Spinal anesthesia In the Elderly: Single Dose versus Titration through a Catheter. *Anesthesia & Analgesia*, **82**, 312-316. <https://doi.org/10.1213/00000539-199602000-00017>
- [12] Hurley, R.J. and Lambert, D.H. (1990) Continuous Spinal Anaesthesia with a Micro-Catheter Technique: Preliminary Experience. *Anesthesia & Analgesia*, **70**, 97-102. <https://doi.org/10.1213/00000539-199001000-00017>
- [13] Vijayan, R., Chan, L. and Raveenthiran, R. (1995) Continuous Spinal Anaesthesia—Early Experience in University Hospital, Kuala Lumpur. *Medical Journal of Malaysia*, **50**, 401-410.
- [14] Maurer, K., Bonvini, J.M., Ekatothramis, G., Serena, S. and Borgear, A. (2003) Continuous Spinal Anaesthesia/Analgesia vs Single-Shot Spinal Anaesthesia with Patient-Controlled Analgesia for Elective Hip Arthroplasty. *Acta Anaesthesiologica Scandinavica*, **47**, 878-883. <https://doi.org/10.1034/j.1399-6576.2003.00173.x>
- [15] Kumar, C.M., Corbett, W.A. and Wilson, R.G. (2008) Spinal Anaesthesia with a Micro-Catheter in High-Risk Patients Undergoing Colorectal Cancer and Other Major Abdominal Surgery. *Surgical Oncology*, **17**, 73-79. <https://doi.org/10.1016/j.suronc.2007.10.025>
- [16] Palmer, C.W. (2010) Continuous Spinal Anesthesia and Analgesia in Obstetrics. *Anesthesia & Analgesia*, **111**, 1476-1479. <https://doi.org/10.1213/ANE.0b013e3181f7e3f4>
- [17] Verstraete, S., Walters, M.A., Devroe, S., Roofthoof, E. and Van de Velde, M. (2014) Lower Incidence of Post-Dural Puncture Headache with Spinal Catheterization after Accidental Dural Puncture in Obstetric Patients. *Acta Anaesthesiologica Scandinavica*, **58**, 1233-1239. <https://doi.org/10.1111/aas.12394>

- [18] Lonjaret, L., Lairez, O., Fourcade, O. and Minville, V. (2012) Rachianesthésie continue et hypertension artérielle pulmonaire. *Annales Françaises d'Anesthésie et de Réanimation*, **31**, 810-812. <https://doi.org/10.1016/j.annfar.2012.07.016>