



Left Paraduodenal Hernia: Rare Cause of Acute Intestinal Obstruction

I. El Messaoudi ^{a*}, A. Laalou ^a, O. Aragon ^a,
K. Chtaibi ^a, N. Njoumi ^a and A. Ait Ali ^a

^a *Military Hospital Mohamed V Rabat, Faculty of Medicine Rabat, Mohammed V University, Rabat, Morocco.*

Authors' contributions

This work was carried out in collaboration among all authors. All authors read and approved the final manuscript.

Article Information

Open Peer Review History:

This journal follows the Advanced Open Peer Review policy. Identity of the Reviewers, Editor(s) and additional Reviewers, peer review comments, different versions of the manuscript, comments of the editors, etc are available here: <https://www.sdiarticle5.com/review-history/111072>

Case Report

Received: 05/11/2023

Accepted: 09/01/2024

Published: 17/01/2024

ABSTRACT

Internal hernias are a rare cause of intestinal obstruction, representing less than 1% of cases. Preduodenal hernias, the most common type of internal hernias, are of a congenital origin. They may be asymptomatic, cause chronic abdominal pain, or present with an acute bowel obstruction with strangulation and ischemia. We report a case of a left preduodenal hernia found in a patient with acute intestinal obstruction.

Keywords: Internal hernia; preduodenal hernia; bowel obstruction.

1. INTRODUCTION

“Internal hernias represent less than 1% of the causes of acute intestinal obstruction of mechanical origin” [1]. Para-duodenal hernias

are classically by far the most frequent since they represent 50% to 55% of all internal hernias [2]. “They are associated with a high lifetime risk of causing obstruction and in these cases the mortality rate can be as high as 20%, possibly

**Corresponding author: E-mail: imad.elazzaoui@gmail.com;*

due to delayed diagnosis” [3-6]. “Therefore, the diagnosis should be suspected in any patient presenting with acute small bowel obstruction without a history of prior abdominal surgery. The CT scan is the examination of choice for diagnosing para-duodenal hernia with small loops. The diagnosis of this congenital malformation is often made during intraoperative surgical exploration of the occluded bowel” [7]. In this case report, we present the case of a 70-year-old female admitted with acute bowel obstruction caused by a left para-duodenal hernia.

2. CASE PRESENTATION

A 70-year-old female, followed for ankylosing spondylitis (APS) with no history of previous surgical intervention, was admitted to the emergency room with an acute intestinal obstruction due to abdominal pain with cessation of matter and gas for 2 days associated with bilious vomiting. We found a diffuse tenderness without signs of peritonitis in the abdominal

examination. In digital rectal examination, we found an empty rectal ampulla.

The unprepared abdomen regains small air-fluid levels. An abdominal computed tomography (CT) scan found a feces sign at the level of an ileal loop with distension of the adjacent small bowel concluding in a mechanical small bowel occlusion (Fig. 1).

The patient was operated on urgently by midline laparotomy. Surgical exploration found distended small bowel loops with caliber disparity and area of stricture 2 meters from the angle of the jejunal denomination in an orifice of a left para-duodenal internal hernia measuring approximately 2 cm in diameter. After reduction of the intestinal loops, the orifice of the hernia is enlarged (Fig. 2).

To note, exploration does not find necrosis or peritonitis. The post-operative follow-up is simple and the patient was discharged on the 3rd day after the operation.

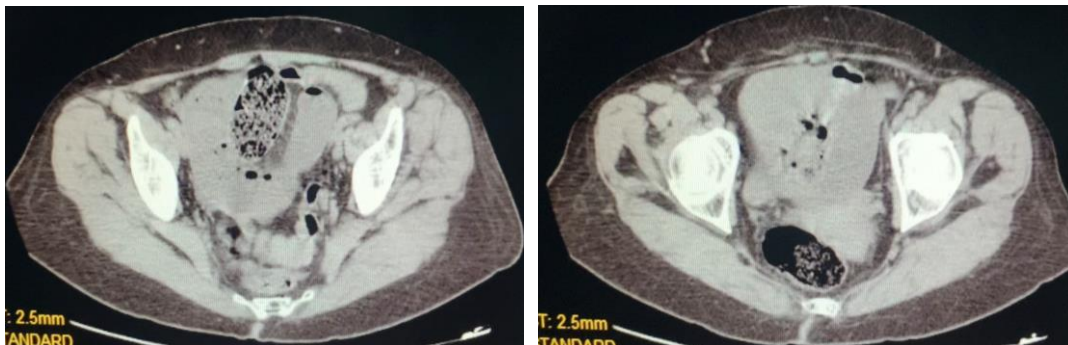

Fig. 1. CT scan showing a loop incarcerated in an internal hernia

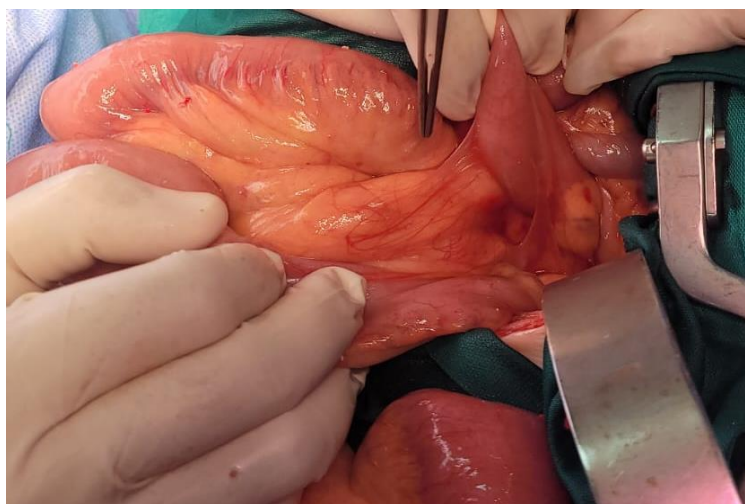


Fig. 2. Per-operative image showing the internal orifice

3. DISCUSSION

“Internal hernias are protrusions of the hollow abdominal viscera in an intraperitoneal orifice, but which remain inside the abdominal cavity (post-surgical iatrogenic forms are excluded)” [2].

Depending on the Nature of the Orifice, Several Types and Mechanisms Can be Described:

- a. Orifice para normal, creating a peritoneal dimple, due to a lack of joining of the peritoneal layers (Toldt or Treitz): retrocecal, paraduodenal; or exaggeration of a peritoneal fold: ileocaecal, retroduodenal, paravascular. Other locations have been described: paracolic, intersigmoid, supramesical or in the folds of the broad ligament.
- b. Through an abnormal pathological orifice, the mechanism of which remains controversial: small or large omentum, falciform ligament of the liver, trans mesenteric or mesocolic.
- c. Finally through a normal orifice: the omental foramen (Hiatus of Winslow) [8].

“Although PH is congenital, most cases are discovered between the 4th and 6th decades of life with an average age of about 38.5 years, they occur exceptionally in patients over 75 years old. Men are generally 3 times more affected than women” [9]. The clinical picture is not specific and the circumstances of discoveries are variable. Some internal hernias may remain asymptomatic throughout life.

“About 10% to 15% of cases are discovered preoperatively” [10]. “Often the clinical signs are dominated by periumbilical or postprandial cramps, epigastric pain, nausea, vomiting and rarely the presence of an abdominal mass on the left side” [11].

“But the most common presentation of left paraduodenal hernia is acute bowel obstruction” [12]. “At least 50% of patients with left paraduodenal internal hernias eventually develop occlusions” [13].

“Mortality is high at 20 to 50%, hence the recommendations all cases of internal hernias, including asymptomatic people, should be surgically corrected” [14].

“Computed tomography has now become the examination of choice to provide the correct

diagnosis during symptomatic periods. The preoperative diagnosis of these internal hernias could often be unknown even after a good scannographic examination, its discovery is per operative” [11].

“The treatment is surgical. The hernia must be reduced manually. If it is difficult to reduce due to its bulky size or adhesions inside the sac, an incision in the avascular part of the hernial sac on the right side of the lower mesenteric vessels. During this procedure, it is important to consider the relationship to the inferior mesenteric vessels to avoid injury to these structures” [11].

“The defect is treated in two ways, either by simple closure or by wide opening of the sac by making it continuous with the peritoneal cavity” [11].

In case of intestinal necrosis, the gesture will be associated with a resection [15].

Studies have revealed that a laparoscopic approach is possible which will be useful as a means of diagnosis if in doubt and at the same time therapeutic [16-18].

4. CONCLUSION

Any occlusive syndrome with a sudden onset with dilated small bowel loops, in a patient with no prior surgical history, even elderly, should in principle raise the possibility of a strangulated internal hernia; the frequency of “primary peritoneal bands” being at most around 10%. [2]. Careful analysis of axial slice images and multiplanar reformations should, in most cases, lead to the diagnosis.

CONSENT

As per international standards or university standards, patient(s) written consent has been collected and preserved by the author(s).

ETHICAL APPROVAL

As per international standard or university standards written ethical approval has been collected and preserved by the author(s).

COMPETING INTERESTS

Authors have declared that no competing interests exist.

REFERENCES

1. Duarte GG, Fontes B, Poggetti RS, Loreto MR, Motta P, Birolini D. Strangulated internal hernia through the lesser omentum with intestinal necrosis: A case report. Sao Paulo Med J. 2002; 120:84–6.
2. Mathias J, Phi I, Bruot O, Ganne P-A, Laurent V, Regent D. Hernies internes. EMC (Elsevier Masson SAS, Paris), Radiodiagnostic - Appareil digestif, 33-015-A-37; 2008.
3. Patil R, Smith C, Brown MD. Paraduodenal hernia presenting as unexplained recurrent abdominal pain. Am J Gastroenterol. 1999; 94:3614-5.
4. Manji R, Warnock GL. Left paraduodenal hernia: An unusual cause of small bowel obstruction. Can J Surg. 2001;44: 455-7.
5. Rollins MD, Glasgow RE. Left paraduodenal hernia. J Am Coll Surg. 2004;198:492-3.
6. Brigham RA, Fallon WF, Saunders JR, Harmon JW, D'avis JC. Paraduodenal hernia: Diagnosis and surgical management. Surgery. 1984;96:498-502.
7. Trigui A, Guirat A, Rejab H, Kardoun N, Frikha F, Amar MB, Beyrouti MI. An uncommon cause of acute bowel obstruction: The left para-duodenal hernia. Niger J Surg. 2012;18:97-9.
8. Armstrong O, Hamel A, Hamel O, Rogez JM, Robert R, Leborgne J, Tech C, Lagier S, Blin Y. Hernies internes: Anatomie chirurgicale. Laboratoire d'Anatomie, Faculté de Médecine de Nantes, France. Constant – Roumanie, 22-28 Mai 2005;195.
9. Singh RR, Warren P, Smith P, Wilson W. Image of the month. Paraduodenal Hernia. Arch Surg. 2006;141:711-2.
10. Socas Macías M, Alamo Martín JM, Suárez Grau JM, Suárez Artacho G, Tejada A, Martín Cartes J, et al. A typical left paraduodenal hernia. Rev Esp Enferm Dig. 2006;98:473-5.
11. Trigui A, Guirat A, Rejab H, Kardoun N, Frikha F, Amar MB. An uncommon cause of acute bowel obstruction: The left para. Duodenal Hernia. Nigerian Journal of Surgery. 2012;18(2):97-9.
12. Medarhri J, El Ounani M, Rachid K, Jaafar A, Iken A, Echarrab M, Balafrej S. Hernie interne para-duodénale gauche à propos d'une nouvelle observation. Médecine du Maghreb. 1997;62:20-22.
13. Cingi A, Demirkalem P, Manukyan MN, Tuney D, Yegen. Left-sided paraduodenal hernia: Report of a case. Surg Today 2006; 36:651-4.
14. Dritsas ER, Ruiz OR, Kennedy GM, Blackford J, Hasl D. Paraduodenal hernia: A report of two cases. Am Surg. 2001; 67:733-6.
15. Guinier D, Tissot O. Hernie interne transomentale étranglée. Journal de Chirurgie Viscérale. 2012;149(3):241-243.
16. Antedomenico E, Singh NN, Zogorski S. M, Dwyer K, Chung MH. Laparoscopic repair of a right paraduodenal hernia. Surg Endosc. 2004;18:165-6.
17. Uematsu T, Kitamura H, Iwase M, et al. Laparoscopic repair of a paraduodenal hernia. Surg Endosc. 1998;12:50-2.
18. Fukunaga M, Kidokoro A, et al. Laparoscopic surgery for left paraduodenal hernia. J Laparoendosc Adv Surg Techn. 2004;14:111-5.

© 2024 El Messaoudi et al.; This is an Open Access article distributed under the terms of the Creative Commons Attribution License (<http://creativecommons.org/licenses/by/4.0>), which permits unrestricted use, distribution, and reproduction in any medium, provided the original work is properly cited.

Peer-review history:

The peer review history for this paper can be accessed here:

<https://www.sdiarticle5.com/review-history/111072>