



# **Obesity and Maternal Periodontal Disease do not Cause Changes in Offspring's Adult Life - Study in Rats**

**Thayná N. Petry De Paula<sup>a</sup>, Sandra L. Balbo<sup>b</sup>, Milara B. Moi<sup>a</sup>,  
Valeria Suemi<sup>a</sup>, João P. Paiva<sup>a</sup>, Victor Miguel Goncalves Silva<sup>a</sup>,  
Jakeline L. Teleken<sup>a</sup>, Maria L. Bonfleur<sup>b</sup>, Joao P. A. Amorim<sup>c</sup>  
and Carlos A. Nassar<sup>d\*</sup>**

<sup>a</sup> *Western Paraná State University – UNIOESTE, Cascavel, Parana, Brazil.*

<sup>b</sup> *Department of Physiology, Western Paraná State University – UNIOESTE, Cascavel, Parana, Brazil.*

<sup>c</sup> *Department of Celular Biology, Western Paraná State University – UNIOESTE, Cascavel, Parana, Brazil.*

<sup>d</sup> *Department of Periodontics, Western Paraná State University – UNIOESTE, Cascavel, Parana, Brazil.*

## **Authors' contributions**

*This work was carried out in collaboration among all authors. All authors read and approved the final manuscript.*

## **Article Information**

DOI: 10.9734/JAMMR/2022/v34i431281

## **Open Peer Review History:**

This journal follows the Advanced Open Peer Review policy. Identity of the Reviewers, Editor(s) and additional Reviewers, peer review comments, different versions of the manuscript, comments of the editors, etc are available here: <https://www.sdiarticle5.com/review-history/83178>

**Original Research Article**

**Received 05 January 2022**

**Accepted 07 March 2022**

**Published 12 March 2022**

## **ABSTRACT**

**Objective:** To investigate the influence of MSG obesity and maternal periodontal disease on the mandibular bone loss of male offspring in adulthood.

**Methods:** 60 neonatal Wistar females were used and randomly separated into two groups. During the first 5 days of life, half of the female pups received subcutaneous injections in the cervical region of monosodium glutamate (MSG), and the other half-received of hyperosmotic saline solution (CTL). All animals used in the experiments received water and standard feed. At 70 days of life, animals were distributed into four experimental groups: control with no ligature (CTL NL), control with a ligature (CTL WL), MSG with no ligature (MSG NL), and MSG with a ligature (MSG

\*Corresponding author: E-mail: [canassar@yahoo.com](mailto:canassar@yahoo.com);

WL). The four groups of females reproduced with control rats (2:1). Offspring (F1) were classified into 4 groups, according to the mothers' treatment. Hemimandibles were collected for histological, morphological, and radiographic analysis and a portion of gingival tissue for analysis by enzyme-linked immunosorbent assay (ELISA) of cytokines IL-6, IL-10, IL-17, and TNF-alpha. Data were assessed using Two-way ANOVA and Tukey's test.

**Results:** There were no changes related to maternal hypothalamic obesity associated with periodontal disease in alveolar bone loss in the male offspring of F1 rats at 120 days.

**Conclusions:** Hypothalamic obesity and maternal periodontal disease did not affect the body and plasma parameters of their male offspring in the first generation, demonstrating that there was no effect of fetal programming on these parameters.

*Keywords: Obesity; periodontal disease; fetal programming; alveolar bone loss.*

## 1. INTRODUCTION

Studies have shown that parents' nutrition and lifestyle influence their children's health status in adulthood [1-2]. Over the past 30 years, the Developmental Origins of Health and Disease (DOHaD) paradigm has identified the preconception, prenatal, and neonatal periods as fundamental to shaping future susceptibility to non-communicable diseases [3-4]. The environment in which mothers experience in the preconception period and those to which their children are exposed in the womb and the first year of life tend to be essential to influence the later growth of adiposity in childhood through numerous plausible mechanisms [5-6]. It is believed that the increase in obesity rates is not only due to the excessive consumption of caloric foods and physical inactivity nowadays, but also due to the "vicious cycle" caused by obesity since children of obese people have a higher predisposition for the development of this disease [7]. The administration of monosodium glutamate (MSG) in the neonatal period causes lesions in the arcuate nucleus and median eminence of the hypothalamus, which leads to the development of hypothalamic obesity [8-10]. According to the literature, high doses of MSG administered during the neonatal period in rats also induce several abnormalities that result in extreme adiposity, accompanied by insulin resistance, glucose intolerance, dyslipidemia, and hypersecretion of insulin [11].

The increase in the prevalence of obesity is one of the leading health-related concerns worldwide since excess weight represents a significant risk factor for several comorbidities, such as cardiovascular diseases, high blood pressure, dyslipidemia, respiratory problems, apnea sleep, gastrointestinal diseases, arthritis, venous circulatory disease, strokes and periodontal disease [12]. Obesity rates in children and

adolescents worldwide increased from less than 1% (equivalent to five million girls and six million boys) in 1975 to almost 6% in girls (50 million) and almost 8% in boys (74 million) in 2016 [13]. The projection of the World Health Organization (WHO) is that, in 2025, the number of overweight and obese children may reach 75 million - including 427 thousand children with pre-diabetes, 1 million with high blood pressure, and 1.4 million with increased accumulation of fat in the liver. Besides, obesity has also been suggested as a risk factor for periodontitis [14]. Periodontal disease is an infectious and inflammatory disease that affects the supporting structures of teeth due to the interaction between periodontal pathogenic bacteria and the host's immune response [15]. The host's immune system, mainly for protection purposes, eventually destroys tooth support tissues through the synthesis and release of cytokines, pro-inflammatory mediators, and metalloproteinases [16].

Periodontal disease is known for being one of the chronic diseases that most affect the world population [17]. Periodontal medicine has investigated the relationship between periodontitis and other systemic changes, such as diabetes mellitus, rheumatoid arthritis, cardiovascular diseases, and obesity [18-19]. It is believed that the release of cytokines by adipose tissue and pro-inflammatory hormones called adipocytokines induces inflammatory processes and oxidative stress disorders, generating similar pathophysiology between the two diseases, obesity and periodontal disease [20].

Given the above, studies should be developed to help understand the bidirectional relationship between obesity and periodontal disease, as well as fetal programming, since the adverse stimuli suffered by the offspring in the intrauterine environment can influence their health status in

adulthood. Thus, this study aimed to evaluate the influence of hypothalamic obesity and maternal periodontal disease on the periodontal tissues of male offspring in adulthood.

## **2. MATERIAL AND METHODS / EXPERIMENTAL DETAILS / METHODOLOGY (ARIAL, BOLD, 11 FONT, LEFT ALIGNED, CAPS)**

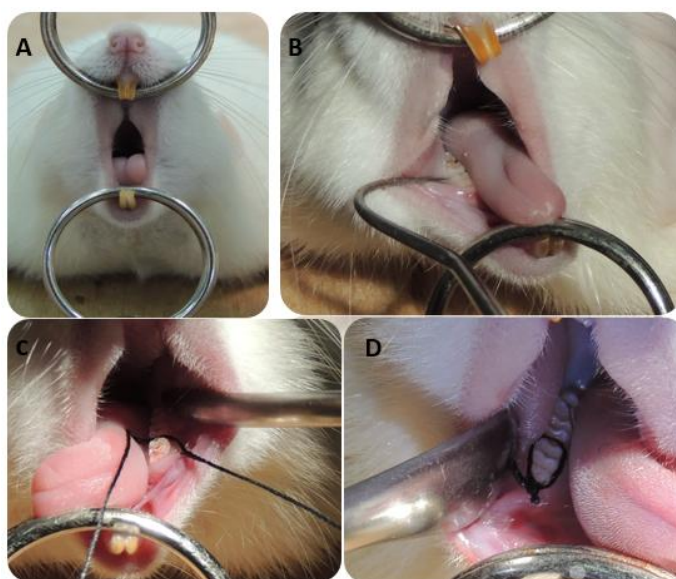
This study was submitted to the Ethics Committee on the Use o Animals (CEUA) at the Western Paraná State University. After the approval of the referred committee, female Wistar rats (N = 60) were obtained from the Central Vivarium of the Western Paraná State University and kept in the sectorial vivarium of the Laboratory of Endocrine Physiology and Metabolism under controlled temperature conditions ( $23 \pm 2^{\circ}\text{C}$ ) and light (cycle of 12 hours of light and 12 hours of darkness – 7 a.m. – 7 p.m.). Half of the female pups received during the first five days of life subcutaneous injections in the cervical region of 4g/Kg/day of monosodium glutamate (MSG) to induce hypothalamic obesity (MSG group, n = 30), and the other half received 1.25/Kg/day of hyperosmotic saline solution (CTL group, n = 30) [21].

All animals used in the experiments received water and standard feed throughout the

experimental period and were weighed once a week after weaning. The male animals used for the reproduction received water and standard feed at will and were used for reproducing with the female CTL and MSG.

### **2.1 Induction of Periodontal Disease**

At 70 days of life, half of the animals in the MSG (n = 15) and CTL (n = 15) groups underwent experimental periodontal disease. For this, they were anesthetized with intraperitoneal injection with xylazine hydrochloride 0.04 mg/kg (ANASEDAN®, Sespo Indústria e Comércio, Paulínia-SP) and ketamine hydrochloride 0.08 mg/kg (DOPALEN®, Sespo Indústria e Comércio, Paulínia-SP). Then, the animals were placed on an appropriate operating table, which allowed the mouth opening of the rats to be maintained, facilitating access to the teeth of the posterior region of the mandible. With the aid of a modified clamp and an explorer probe, a cotton thread size 40 (GLACE®) was placed around the first right and left lower molar. This ligature acted as a gingival irritant and favored the accumulation of bacterial plaque [22]. After induction of periodontal disease, the animals were divided into four experimental groups: control with no ligature n = 15 (CTL NL), control with ligature n = 15 (CTL WL), MSG with no ligature n = 15 (MSG NL), and MSG with ligature n = 15 (MSG WL).



**Image 1. Periodontal Disease Induction. A: Mouth opening. B and C: Placement of the ligature (cotton thread size 40) around the lower first molar. D: Ligature around the lower first molar. Euthanasia of the 1<sup>st</sup> group**

Seven days after periodontal disease induction, five rats from each group (CTL NL, CTL WL, MSG NL, and MSG WL) were euthanized to verify the presence and development of periodontal disease through radiographic analysis. These females were weighed, and the naso-anal length was obtained. Right after euthanasia by decapitation, the perigonadal and retroperitoneal fats were collected and weighed. The left hemimandibles were collected for further radiographic analysis.

## 2.2 Reproduction

Seven days after induction of periodontal disease, reproduction between the female rats from CTL NL, CTL WL, MSG NL, and MSG WL (n = 10) were performed with control male rats, in the ratio of one male to two females. After the pregnancy was confirmed, the male rats were euthanized, and the pregnant females separated in individual boxes. After pregnancy and lactation, about 45 days, the females were euthanized by decapitation. Only male offspring were used for this study.

## 2.3 Experiments with Mothers

Before euthanasia, mothers remain fasting for 8 hours. Tail blood was collected for fasting blood glucose using a glucose analyzer (G-Tech Free®, SD Biosensor, Korea). Quickly, body weight and nasal length were measured to calculate the Lee index  $\{[BW \text{ ratio (g) / nasal length (cm)}] \times 1000\}$ , which was used as a parameter of rodent obesity. Then, the animals were desensitized with carbon dioxide in the CO<sub>2</sub> chamber (Insight®, Ribeirão Preto, SP, Brazil) and euthanized by decapitation. Retroperitoneal and perigonadal fats were removed and weighed to assess or increase fat. They were collected as hemimandibles for radiographic evaluation in mothers.

### 2.3.1 Experiments with offspring obtained (first generation - F1) from mothers CTL and MSG, with or without experimental periodontal disease

After birth, six males remained for each litter. At 21 days of life, the offspring obtained (first generation - F1) was designated according to the mothers' treatment in: 1) CTL NL-F1 (n = 10), 2) CTL WL-F1 (n = 10), 3) MSG NL-F1 (n = 10), and 4) MSG WL-F1 (n = 10). These offspring were kept in the sectorial vivarium of the Laboratory of Endocrine Physiology and

Metabolism under controlled conditions of temperature ( $23 \pm 2^\circ\text{C}$ ) and light (cycle of 12 hours of light and 12 hours of darkness – 7 a.m. – 7 p.m.), receiving water and standard feed at will for 120 days. Fasting glucose, body weight, and naso-anal length were measured, as well as in mothers, before euthanasia.

### 2.3.2 Evaluation of mandibular alveolar bone loss by radiographic analysis

After euthanasia, the hemimandibles on the left side from both mothers and offspring were collected, fixed in 10% formaldehyde for 48 hours. Subsequently, they were washed in running water for 24 hours and kept in 70% alcohol. The hemimandibles were placed with the lingual face on the Kodak RVG 6100 digital radiographic sensor with 20 pl/mm image resolution, theoretical sensor resolution 27.03 pl/mm, optical fiber 1, 22 x 30 mm active surface dimensions, and matrix dimensions (pixels) 1200 x 1600 (1.92 million), positioned so that the buccal and lingual cusps of the first molars are in the same vertical plane. A GE-1000 X-ray apparatus, set to 15mA, 65Vp, 18 pulses, 50 cm focus/film distance with an X-ray incidence perpendicular to the pieces, was used. The digitized images were analyzed in three measurements in the Image-Pro Plus® program (Media Cybernetics, USA), and an average was made between them through a linear measurement, which covered the distance from the cemento-enamel junction to the alveolar bone crest on the side mesial aspect of the lower left first molar of the mouse, with measurements in pixels [23]. The measurements were performed by a single examiner, blind to the identities of the experimental groups.

## 2.4 Morphometric Analysis of the Mandibles

The right hemimandibles obtained from the offspring were fixed in a 10% formaldehyde solution for 48 hours. After this period, they were washed in running water for 24 hours and immersed in 70% alcohol. Subsequently, they were immersed in a 5% trichloroacetic acid solution (Pr Labor®) for descaling. The pieces were evaluated daily in order to verify the expected degree of descaling with the renewal of the TCA solution every five days. After descaling, the pieces were rewashed under running water for one hour, and histological processing was started. The fragments of the hemimandibles were dehydrated in an ascending alcoholic

series, diaphonized in xylol, and included in Paraplast. The Paraplast blocks were cut in a manual rotary microtome (Olympus 4060®) to obtain sections of 5 µm thick, which were mounted on histological slides and stained using the Hematoxylin and Eosin (H&E) technique.

For the morphometric analysis, an optical microscope (Olympus BX61®) was used. For the photomicrographs, an Olympus DP71® digital camera was used with the DP Controller® 3.2.1.276 software. These analyzes were made through measurements on the buccal and right lingual marginal gums in all offspring groups, using an image analyzer program, coupled to an optical microscope with a 10x objective. Measurements were made from pre-determined morphological points in the marginal gingiva. The results were expressed in pixels. Measurements of the total area of the epithelium and connective tissue were also performed. Two measurements were made, on different days, with the value of the area occupied by epithelium and connective tissue calculated. The results were expressed in pixels, using the Image-Pro Plus® program (Media Cybernetics, USA) [23].

The quantification of osteoblasts, osteocytes, and osteoclasts present in five consecutive fields of the vestibular alveolar bone crest starting from the highest point of the crest was performed. For observation, the 40x objective was used. Two observations were made per field, and then the values were averaged for each animal and each group.

The measurement of the alveolar bone crest (measured in pixels) was performed using the BX61® Photomicroscope coupled to a computer, which allowed capturing the images. A measurement of the shortest distance between the apex of the vestibular alveolar bone crest and the cemento-enamel junction was performed. The measurements were repeated twice a day, on three different days, and then the values were averaged.

#### **2.4.1 Analysis of cytokine expression - gingival tissue and plasma**

Blood was collected at the time of decapitation. Blood samples were centrifuged at 3000 rpm, and the plasma was separated and stored at -20°C. A portion of gingival tissue around the first left molars of all offspring groups was removed and stored in RNA/later Stabilization Solution® (ThermoFisher Scientific). Total proteins were extracted from gingival tissue samples using

detergent-based extraction buffer (T-PER®, Tissue Protein Extraction Reagent - Pierce) containing a protease inhibitor cocktail (Protein Stabilizing Cocktail® - Santa Cruz Biotechnology) according to the manufacturer's instructions.

For the quantification of cytokines in the gingival tissue, the samples were sonicated (DESRUPTOR®, Ultranique, Brazil). Subsequently, they were centrifuged for 30 minutes at 12,000 rpm at 4 ° C. The concentrated supernatant was quantified using the Bradford protein quantification system (Bio-Rad®). For the detection and quantification of the cytokines IL-6, IL-10, IL-17, and TNF-alpha in plasma and gingival tissue, 100 µL of the sample was used at a wavelength of 450 nm according to Rat Custom ProcartaPlex magnetic bead (Invitrogen, USA) with the MAGPIX® platform, according to the manufacturer's instructions.

### **2.5 Statistical Analysis**

The results were analyzed using the Graphpad Prism® 5.0 program. In all variables, normal distribution and homogeneous variance were tested. As the distribution was considered normal and the variance was homogeneous, parametric tests ANOVA - Two Way was used, followed by the Tukey multiple comparison post-test. The observed differences were considered significant when  $p < 0.05$ .

### **3. RESULTS**

When analyzing body parameters in mothers, body weight and naso-anal length were reduced in the MSG NL and MSG WL groups compared to the control groups (Table 1). However, the animals from MSG NL and MSG WL showed a higher Lee index, proving the onset of obesity due to neonatal treatment with MSG. The administration of MSG caused an increase in retroperitoneal and perigonadal fats when compared to control groups (Table 1). However, there was no statistically significant difference when the obese groups were compared (MSG NL and MSG WL). Regarding the animals' glycemic profile, there was no statistically significant variation between groups (Table 1).

The radiographically analysis of the alveolar bone in the mothers showed a more significant bone loss ( $p < 0.05$ ) in the groups with induced periodontal disease (CTL WL and MSG WL), although the bone loss was higher in the CTL WL

group than the MSG WL, suggesting a protective effect of MSG-obesity on bone resorption (Fig. 1).

Regarding the body and plasma parameters observed in the first generation, the weight and naso-anal length of the four groups of male offspring were similar, with no difference in the Lee index, as well as the percentage of

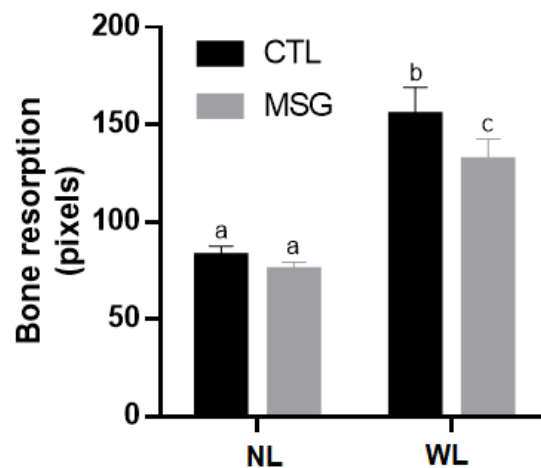
retroperitoneal and perigonadal fat on total body weight. Fasting blood glucose was statistically similar in the four groups observed (Table 2).

In the morphometrically and radiographically analysis of the alveolar bone loss, both, it was observed that obesity and maternal periodontal disease did not affect the first generation of offspring (Fig. 2).

**Table 1. Effects of hypothalamic obesity and periodontitis during pregnancy and lactation on general maternal characteristics**

	CTL NL	CTL WL	MSG NL	MSG WL
Body weight (BW) (g)	245±4.3 <sup>a</sup>	258±5.3 <sup>a</sup>	193.7±4.3 <sup>b</sup>	203.4±6.5 <sup>b</sup>
Naso-anal length (cm)	19.4±0.1 <sup>a</sup>	19±0.2 <sup>a</sup>	17.2±0.1 <sup>b</sup>	17.5±0.1 <sup>b</sup>
Lee index	320.9±3.1 <sup>a</sup>	333.9±4.1 <sup>a</sup>	359.5±6.2 <sup>b</sup>	354.7±4.9 <sup>b</sup>
Perigonadal fat pads (% BW)	0.6±0.06 <sup>a</sup>	0.6±0.07 <sup>a</sup>	1.3±0.1 <sup>b</sup>	1±0.8 <sup>b</sup>
Retroperitoneal fat pads (%BW)	1.07±0.1 <sup>a</sup>	1.07±0.8 <sup>a</sup>	2.1±0.2 <sup>b</sup>	1.7±0.1 <sup>b</sup>
Glucose (mg/Hg)	90.5±8	77.3±6.4	79±6.7	81.1±6.2

Data are means ± SEM (n=7-10).  
p=0,05 versus CTL NL.

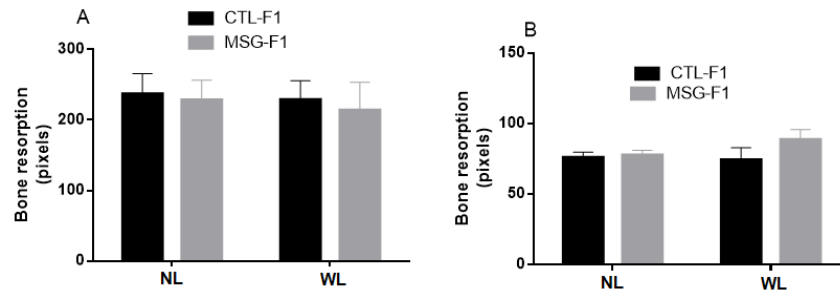


**Fig. 1. Effect of MSG treatment and experimental periodontal disease on maternal alveolar bone resorption. Data are means ± SEM The letters different over the bars represent significant differences amongst groups. p=0.05 versus CTL NL**

**Table 2. Effects of obesity and maternal periodontitis on body parameters and fasting plasma biochemical parameters in F1 offspring male at 120 days**

	CTL NL-F1	CTL WL-F1	MSG NL-F1	MSG WL-F1
BW (g)	394.4±7.3	388.1±7.9	364.9±5.5	373.2±3.5
Naso-anal length (cm)	23.6±0.2	23.6±0.1	23.3±0.2	23.1±0.2
Lee index	307.5±3.3	304.1±1.9	302.6±3	308.8±3.6
Epididymal fat pads (% BW)	1.5±0.05	1.5±0.05	1.3±0.08	1.3±0.04
Retroperitoneal fat pads (%BW)	1.4±0.05	1.5±0.05	1.3±0.08	1.3±0.04
Glucose (mg/Hg)	82.1±3.0	86.6±3.0	87.4±1.0	82.1±3.0

Data are means ± SEM (n=13-16).  
p=0,05 versus CTL NL-F1.



**Fig. 2. Effects of obesity and maternal periodontitis on offspring alveolar bone resorption. (A) Morphometrically and (B) radiographically. Data are means  $\pm$  SEM. The letters different over the bars represent significant differences amongst groups.  $p=0.05$  versus CTL NL-F1**

**Table 3. Measurements of the gingival tissues on the CTL NL-F1, CTL WL-F1, MSG NL-F1 and MSG WL-F1 groups**

	CTL NL-F1	CTL WL-F1	MSG NL-F1	MSG WL-F1
Epithelial base (pixels)	136.8 $\pm$ 6.8 <sup>a</sup>	150.2 $\pm$ 7.8 <sup>b</sup>	87.9 $\pm$ 7.5 <sup>a</sup>	91.9 $\pm$ 17.2 <sup>a,c</sup>
Height epithelial (pixels)	146.3 $\pm$ 8.8	151.1 $\pm$ 4.5	155.9 $\pm$ 12.1	152.2 $\pm$ 9.5
Epithelial area (pixels <sup>2</sup> )	67102.0 $\pm$ 2857.0	73612.0 $\pm$ 2801.0	73149.0 $\pm$ 7586.0	57757.0 $\pm$ 4582.0
Conjunctive base (pixels)	117.2 $\pm$ 4.9	127.1 $\pm$ 14.5	126.1 $\pm$ 17.5	105.4 $\pm$ 10.6
Height conjunctive (pixels)	426.7 $\pm$ 15.6	434.0 $\pm$ 21.3	423.0 $\pm$ 42.0	379.5 $\pm$ 25.4
Conjunctive area (pixels <sup>2</sup> )	36323.0 $\pm$ 2784.0	34112.0 $\pm$ 2819.0	26068.0 $\pm$ 6075.0	21406.0 $\pm$ 2963.0
Osteoblasts	14.6 $\pm$ 7.0	35.1 $\pm$ 10.0	28.2 $\pm$ 11.0	35.9 $\pm$ 15.0
Osteocytes	919.4 $\pm$ 84.0	1015.0 $\pm$ 215.0	976.3 $\pm$ 189.0	1375.0 $\pm$ 207.0
Osteoclasts	13.6 $\pm$ 7	16.3 $\pm$ 8	1.5 $\pm$ 0.9	1.0 $\pm$ 0.7

Data are means  $\pm$  SEM (n=13-16).  
 $p=0,05$  versus CTL NL-F1.

**Table 4. Inflammatory cytokine concentration in the offspring plasma and gingival tissue**

	CTL NL-F1	CTL WL-F1	MSG NL-F1	MSG WL-F1
IL-6 (ng/ml) plasma	60.456 $\pm$ 9.784	79.900 $\pm$ 3.899	82.088 $\pm$ 14.723	80.428 $\pm$ 3.950
IL-6 (ng/ml) gingival	253.690 $\pm$ 31.130	234.344 $\pm$ 33.087	330.467 $\pm$ 33.476	253.017 $\pm$ 60.680
IL-10 (ng/ml) plasma	83.360 $\pm$ 5.877	94.695 $\pm$ 2.067	90.873 $\pm$ 6.968	93.910 $\pm$ 7.506
IL-10 (ng/ml) gingival	1.458.006 $\pm$ 27.673	1.473.000 $\pm$ 17.711	1.581.000 $\pm$ 71.252	1.449.030 $\pm$ 29.756
IL-17 (ng/ml) plasma	4.241 $\pm$ 1.444	7.959 $\pm$ 967	6.758 $\pm$ 396	6.741 $\pm$ 1.726
IL-17 (ng/ml) gingival	77.567 $\pm$ 19.569	108.916 $\pm$ 13.962	97.593 $\pm$ 22.082	70.990 $\pm$ 24.985
TNF- $\alpha$ (ng/ml) plasma	11.885 $\pm$ 3850	19.746 $\pm$ 2.824	18.033 $\pm$ 1.110	22.635 $\pm$ 7.333
TNF- $\alpha$ (ng/ml) gingival	353.300 $\pm$ 72.629	184.584 $\pm$ 59.555	592.810 $\pm$ 89.293	315.890 $\pm$ 52.844

Data are means  $\pm$  SEM (n=13-16).  
 $p=0,05$  versus CTL NL-F1.

In the morphological analysis of the periodontal tissues, it was observed that the width of the base of the epithelium was similar in the offspring of mothers CTL NL and MSG NL. However, the

CTL WL-F1 group showed an increase when compared to the other groups. In the MSG WL-F1 group, there was a reduction in this value (Table 3). No statistical differences were

observed in the quantification of bone cells (osteoblasts, osteocytes, and osteoclasts) in the four evaluated offspring groups (Table 3).

No statistical differences were observed in the quantification of inflammatory cytokines (IL-6, IL-10, IL-17, and TNF-alpha) in the plasma and gingival tissue in the four evaluated offspring groups (Table 4).

#### 4. DISCUSSION

In the present study, the effect of maternal hypothalamic obesity associated with experimental periodontal disease on offspring in adult life was demonstrated for the first time, in order to observe the possible action of fetal programming. The MSG mothers group showed an increase of 93% and 81% in the weight of retroperitoneal and perigonadal fats, respectively, in addition to a significant difference in the Lee Index ( $p < 0.05$ ) when compared to the CTL group. It proves that obesity was already installed at 77 days and confirms the success of the experimental model used (Table 1). Clinical and experimental studies have already shown that maternal obesity can predispose the fetus to the development of glucose intolerance, obesity, and metabolic syndrome in adulthood since it permanently alters a variety of metabolic control processes in the fetus [3, 23].

The high prevalence of maternal obesity and, consequently, the greater predisposition to metabolic diseases in their offspring places this issue as an urgent priority for discussing the obesity epidemic. Therefore, awareness of the consequences of the obesity epidemic in pregnant women is essential, not only about the pregnancy outcome but also of the potential impact on the health of the next generation. Studies have sought to understand the effect of maternal changes, such as obesity and periodontal disease, on offspring [24-25].

In addition to maternal obesity, it is crucial to understand whether the inflammatory state caused by periodontal disease can have consequences on the offspring. The literature has already demonstrated the relationship between obesity and periodontal disease [26], but it did not relate the two variables and analyzed alveolar bone loss in the first generation. Adipose tissue releases cytokines and pro-inflammatory hormones called adipocytokines, which induce inflammatory

processes and oxidative stress disorders, generating similar pathophysiology between obesity and periodontal disease [27].

In the radiographically analysis of the maternal alveolar bone loss, it was shown that the groups in which the periodontal disease was induced by ligature showed more significant bone resorption than the NL groups, demonstrating the disease activity. However, the MSG WL group showed a slight reduction in this value compared to the CTL WL group, suggesting that hypothalamic obesity would have a protective effect on alveolar bone loss (Fig. 1). These data corroborate with studies carried out by the same group of researchers previously [8-9, 28]. Some authors suggest that obesity can lead to a positive effect on bone mass [29] but this issue remains contradictory since other research has shown that there is more significant bone resorption in obese individuals [30-31]. The protective effect of obesity on bone tissue may also be due to the higher concentration of insulin in obese individuals since osteoblasts have an insulin receptor that stimulates osteogenic differentiation and inhibits osteoclastogenesis [32]. Also, adipocytokines, such as leptin, and inflammatory cytokines, such as IL-6 and TNF-alpha, influence bone mass, directly or as a result of their effect on appetite regulation and weight, suggesting that hypothalamic obesity would have a protective effect on alveolar bone loss (Fig. 1).

In our study, hypothalamic obesity did not exacerbate periodontal disease. Nevertheless, the literature demonstrates that if the induced obesity is done through the high-calorie diet, the results demonstrate microflora and defects in periodontal tissues compatible with the periodontal disease even without the induction of periodontitis [33], suggesting that the type of Induced obesity is relevant to the exacerbation of the periodontal disease. The biological plausibility for the association between obesity and periodontal disease is explained by the increase in the levels of lipids and glucose, which may contribute to an exacerbated inflammatory response of the host, alter the function of neutrophils and also inhibit the production of growth factors by macrophages, reducing the tissue repair capacity [34].

Oral inflammation due to bacterial infections is a source of bacteria and inflammatory mediators that can spread systemically through the bloodstream and reach the placental barrier [35]. Studies investigating the action of maternal periodontal disease on parameters of the first



generation are still scarce. However, some authors have already demonstrated that the presence of the maternal periodontal disease has led to increased levels of tumor necrosis factor-alpha (TNF-alpha) cytokine in the offspring brain tissue and insulin resistance [36-37], which demonstrates the systemic influence caused by inflammation of the periodontal disease.

After injecting bacterial endotoxin (lipopolysaccharide) in pregnant rats, Nilsson et al. (2001) observed that offspring exhibited an increase in body weight, an increase in abdominal adipose tissue, and a reduction in the effect of insulin on glucose uptake, suggesting that the prenatal period is vital to determine the risk of developing insulin resistance and obesity in adult offspring. In this study, there was no statistically significant difference in the Lee index, retroperitoneal fat, perigonadal fat, and glycemia among the four groups of offspring studied (Table 2). Other studies using maternal hypothalamic obesity have shown that, after five months of life, the offspring developed obesity as well [38] however, the animals in the present study were euthanized at 120 days of age, suggesting that the changes resulting from obesity maternal are expressed later.

Epidemiological and experimental studies show that maternal obesity or consumption of a high-fat diet is associated with increased susceptibility to fatty liver and inflammation, hypertension, cardiovascular disorders [39], obesity, and insulin resistance [24, 40] in offspring at different stages of development. Few studies have previously been carried out with maternal hypothalamic obesity to assess the effect of this change on metabolic programming [39] which may suggest that it is because MSG animals show changes in reproductive function [41]

There were no differences in alveolar bone loss between the offspring, both morphologically and radiographically (Fig. 2), as well as there were no significant differences in the quantification of bone cells (Table 3). Hypothalamic obesity and maternal periodontal disease did not affect the first generation of offspring. Studies carried out to this date using obesity and maternal periodontal disease have not yet investigated whether there would be consequences of this change in the periodontal tissues of the offspring [36, 42-43]. An experimental model of induction of periodontal disease through the inoculation of periodontal pathogenic microorganisms found changes in the offspring, such as increased

inflammatory cytokines in the placenta, brain damage, premature birth, and low birth weight [44]. In the present article, no statistically significant difference was observed in the quantification of inflammatory cytokines in the plasma and gingival tissue of the offspring.

As in the experimental model of obesity, the type of induced periodontal disease used is suggested to cause changes in the offspring. One of the hypotheses that permeate metabolic programming is the Two-hit hypothesis. It suggests that the adverse stimuli that occurred during the perinatal period (first hit) would not, by themselves, be enough to change the phenotype of the individual in adulthood, but exposure to stressors in postnatal life can act as a second hit, activating or amplifying the effects of fetal programming and leading to the appearance of diseases [45]

In the morphometric analysis of the gingival tissue, there was an increase in the epithelial base in the CTL WL-F1 group compared to the CTL NL-F1 group and MSG NL-F1 (Table 3). However, in the MSG WL-F1 group, there was a reduction in this parameter when compared to the CTL WL-F1 group, suggesting that, although there is no evident alveolar bone loss in the evaluated period, there may be a higher predisposition to gingival inflammation in the offspring of obese rats with a ligature.

#### 4. CONCLUSION

Within the limits of this study, the findings of this study demonstrated that maternal hypothalamic obesity associated with periodontal disease does not affect alveolar bone loss in the male offspring of rats aged 120 days. In addition, the results suggest that obese mothers may have a protective effect on alveolar bone loss induced by experimental periodontal disease.

#### DISCLAIMER

The products used for this research are commonly and predominantly use products in our area of research and country. There is absolutely no conflict of interest between the authors and producers of the products because we do not intend to use these products as an avenue for any litigation but for the advancement of knowledge. Also, the research was not funded by the producing company rather it was funded by personal efforts of the authors.

## CONSENT

It is not applicable.

## ETHICAL APPROVAL

The Ethical Committee on the Use of Animals (CEUA) of UNIOESTE (with approval opinion of Dec 08, 2017) approved the project, which followed the Ethical Principles in Animal Experimentation adopted by the National Council for the Control of Animal Experimentation (CONCEA).

## COMPETING INTERESTS

Authors have declared that no competing interests exist.

## REFERENCES

1. Godfrey KM, Gluckman PD e Hanson MA. Developmental origins of metabolic disease: Life course and intergenerational perspectives. *Trends Endocrinol. Meta.* 2010;4:199-205.
2. Koletzko B, Symonds ME e Olsen SF. Programming research: where are we and where do we go from here? *Am. J. Clin. Nutr.* 2011;94(6):2036-2043.
3. Barker DJ. The origins of the developmental origins theory. *J. Intern. Med.* 2007;261(5):412-417.
4. Portha B, Grandjean V e Movasset, J. Mother or Father: Who Is in the Front Line? Mechanisms Underlying the Non-Genomic Transmission of Obesity/Diabetes via the Maternal or the Paternal Line. *Nutrients.* 2019;11(2):233-256.
5. Mattera MSLC, Chiba FY, Lopes FL. et al. Effect of maternal periodontitis on GLUT4 and inflammatory pathway in adult offspring. *J. Periodontol.* 2019;90(8):884-893.  
DOI: 10.1002/JPER.18-0568
6. Wilding S, Ziauddeen N, Smith D, Roderick P, Alwan NA. Maternal and early-life area-level characteristics and childhood adiposity: A systematic review. *Obes. Rev.* 2019;1093-1105.
7. Catalano PM. Obesity and pregnancy--the propagation of a vicious cycle? *J. Clin. Endocrinol. Metab.* 2003;88(8):3505-3506.
8. Brandelero SJ, Bonfleur ML, Ribeiro RA. et al. Decreased TNF-ALFA- $\alpha$  gene expression in periodontal ligature in MSG-obese rats: A possible protective effect of hypothalamic obesity against periodontal disease?. *Arch. Oral Biol.* 2012;57(3):300-306.
9. Costa KF, Bonfleur ML, Pontilho V. Evaluation of Periodontal Tissues and Abdominal Aorta of Rats with Induced Obesity by Monosodium Glutamate and Experimental Periodontitis. *BJMHR.* 2017;19(2):1-14.
10. Bahadoran Z, Mirmiran P, Ghasemi A. Monosodium Glutamate (MSG)-Induced Animal Model of Type 2 Diabetes. *Methods Mol Bio.* 2018;1916:49-65.  
DOI: 10.1007/978-1-4939-8994-2\_3
11. Balbo SL, Grassioli S, Ribeiro RA. et al. Fat storage is partially dependent on vagal activity and insulin secretion of hypothalamic obese rat. *Endocrine.* 2007;31(2):142-148.
12. Brianezzi LFF, Al-Ahij LP, Prestes LA. et al. Impact of obesity on oral health: a literature review. *RFO UPF.* 2013;18(2):211-216.
13. WHO. Obesity: Preventing and managing the global epidemic. World Health Organization. 2016; Accessed: 14 Jul 2019. Available: [http://www.who.int/nutrition/publications/obesity/WHO\\_TRS\\_894/en/](http://www.who.int/nutrition/publications/obesity/WHO_TRS_894/en/).
14. Al-Zahrani MS, Bissada NF, Borawski EA. Obesity and periodontal disease in young, middle-aged, and older adults. *J Periodontol.* 2003;74(5):610-615.  
DOI: 10.1902/jop.2003.74.5.610
15. Zambon M, Mando C, Lissoni A. et al. Inflammatory and Oxidative Responses in Pregnancies With Obesity and Periodontal Disease. *Reprod Sci.* 2018;25-(10):1474-1484.
16. Lira-Junior R e Figueredo CM. Periodontal and inflammatory bowel diseases: Is there evidence of complex pathogenic interactions? *World J. Gastroenterol.* 2016;22(35):7963-7972.
17. Frenckem JE, Praveen S, Stenhouse L. et al. Global epidemiology of dental caries and severe periodontitis – a comprehensive review. *Journal Clinical Periodontology.* 2017;44:94-105.
18. Torrungruang K, Jitpakdeebordin S, Charatkulangkun O e Gleebua, Y. *Porphyromonas gingivalis*, *Aggregatibacter actinomycetemcomitans*, and *Treponema denticola* / *Prevotella intermedia* Co-Infection Are Associated with Severe Periodontitis in a Thai Population. *Plos One.* 2015;10(8):1-13.

19. Alazawi W, Bernabe E, Tai D. et al. Periodontitis is associated with significant hepatic fibrosis in patients with non-alcoholic fatty liver disease. *PLoS One*. 2017;12:1-13.
20. Vasconcelos ACCG, Vasconcelos DFP, Silva FRP et al. Periodontitis causes abnormalities in the liver of rats. *J. Periodontol*. 2018;90(3):295-305.
21. Moura-Gréc PG, Marsicano JA, Carvalho CA e Sales-Peres SH. Obesity and periodontitis: Systematic review and meta-analysis. *Ciênc.&SaúdeColetiva*. 2014;19:1763-1772.
22. Peralta F, Pallos D, Silva CQ e Ricardo LH. Previous exposure to Cyclosporine A and periodontal breakdown in rats. *Arch. Oral Biol*. 2015;60(4):566-573.
23. Nassar PO, Nassar CA e Guimarães MR. Simvastatin therapy in cyclosporine A-induced alveolar bone loss in rats. *J. Periodontol Res*. 2009;44(4):479-88.
24. Campos KE, Sinzato YK, Pimenta WP, Rudge MV, Damasceno DC. Effect of maternal obesity on diabetes development in adult rat offspring. *Life Sciences*. 2007;81(19):1473-1478.
25. Pietrobon CB, Bertasso IM e Ribeiro RA. Maternal Roux-en-Y gastric bypass impairs insulin action and endocrine pancreatic function in male F1 offspring. *Eur J. Nutr*. 2019;1-13.
26. Manrique-Corredor EJ, Orozco-Beltran D. e Lopez-Pineda A. et al. Maternal periodontitis and preterm birth: Systematic review and meta-analysis. *Community Dent Oral Epidemiol*. 2019;47(3):243-251.
27. Martinez-Herrera M, Silvestre JR e Silvestre FJ. Association between obesity and periodontal disease. A systematic review of epidemiological studies and controlled clinical trials. *Med Oral Patol Oral Cir Bucal*. 2017;708-715.
28. Jagannathachary S e Kamaraj D. Obesity and periodontal disease. *J Indian Soc Periodontol*. 2010;14(2):96-100.
29. Mattia TM, Leite MA, Nassar PO. et al. The Influence of Obesity Induced by Monosodium Glutamate in Periodontal Tissues of Female Wistar Rats with Experimental Periodontitis. *AJCR*. 2017;7(3):28-40.
30. Evans AL, Paggiosi MA, Eastell R, Walsh JS. Bone density, microstructure and strength in obese and normal weight men and women in younger and older adulthood. *J Bone Miner Res*. 2015;30(5):920-928.
31. Nascimento CM, Cassol TS, Bonfleur ML. et al. Radiographic evaluation of the effect of obesity on alveolar bone in rats with ligature-induced periodontal disease. *Diabetes*. 2013;6:365-370.
32. Wani K, Yakout SM, Ansari MGA et al. Metabolic Syndrome in Arab Adults with Low Bone Mineral Density. *Nutrients*. 2019;11(6):1-13.
33. Zhao LJ, Jiang H, Papasian CJ. et al. Correlation of obesity and osteoporosis: effect of fat mass on the determination of osteoporosis. *JBMR*. 2008;23(1):17-29.
34. Branchereau M, Reichardt F, Loubieres P. et al. Periodontal dysbiosis linked to periodontitis is associated with cardiometabolic adaptation to high-fat diet in mice. *Am J Physiol-Gastr L*. 2016;310(11):1091-1101.
35. Machado E, Zanatta GB, Assis CA. e Zanatta FB. Obesity as a risk factor for periodontitis: is that possible? *RGO*. 2011;59(1):45-50.
36. Ren H. e Du M. Role of Maternal Periodontitis in Preterm Birth. *Front. Immunol*. 2018;8:1-10.
37. Shirakashi DJ, Leal RP, Colombo NH. et al. Maternal Periodontal Disease in Rats Decreases Insulin Sensitivity and Insulin Signaling in Adult Offspring. *J. Periodontol*. 2013;84(3):407-414.
38. Campos KE, Volpato GT, Calderon IM, Rudge MV, Damasceno DC. Effect of obesity on rat reproduction and on the development of their adult offspring. *Braz. J. Med. Biol. Res*. 2008;41(2):122-125.
39. Nilsson C, Larsson BM, Jennische E. et al. Maternal Endotoxemia Results in Obesity and Insulin Resistance in Adult Male Offspring. *Endocrinology*. 2001;142:2622-2630.
40. Taylor PD, Samuelsson AM e Poston L. Maternal obesity and the developmental programming of hypertension: a role for leptin. *Acta Physiol (Oxf)*. 2014;210(3):508-523.
41. Boyle KE, Patinkin ZW, Shapiro AL, Baker PR, Dabelea, D, Friedman JE. Mesenchymal Stem Cells From Infants Born to Obese Mothers Exhibit Greater Potential for Adipogenesis: The Healthy Start BabyBUMP Project. *Diabetes*. 2015;65(3):647-659.
42. Olney JW. Brain Lesions, Obesity, and Other Disturbances in Mice Treated with

- Monosodium Glutamate. Science. 1969;164(3880):719-721.
43. Pimentel SP, Casati MZ, Cirano FR. et al. Maternal periodontitis induces intergenerational injuries on reproductive performance of adult female rat offspring. Braz. J. Vet. Res. Anim. 2016;53(4):1-8.
44. Sousa-Soares T, Andreolla AP, Miranda CA. et al. Effect of the induction of transgenerational obesity on maternal-fetal parameters. Syst Biol Reprod Med. 2017;1-9.
45. Liang S, Ren H, Guo H. et al. Periodontal infection with Porphyromonas gingivalis induces preterm birth and lower birth weight in rats. Mol Oral Microbiol. 2018;33(4):312-321.

© 2022 Paula et al.; This is an Open Access article distributed under the terms of the Creative Commons Attribution License (<http://creativecommons.org/licenses/by/4.0>), which permits unrestricted use, distribution, and reproduction in any medium, provided the original work is properly cited.

*Peer-review history:*

*The peer review history for this paper can be accessed here:*  
<https://www.sdiarticle5.com/review-history/83178>